

Variations in the Site of Formation of Basilar Artery

Anjuman Ara Sultana¹, Shamim Ara², Mushfika Rahman³, Halima Afroz⁴, Kanij Fatema⁵, Nurun Nahar⁶, Md. Rafiqul Alam⁷

Abstract

Context: Basilar artery, supplies the anatomical structures within the posterior cranial fossa of brain. The 'Circle of Willis' is the principal arterial anastomotic trunk of brain formed by the anastomosis between the branches of internal carotid arteries and terminal branch of basilar artery. It is responsible for collateral circulation of brain, specially of old people, who have reduced blood supply to brain due to senile arteriosclerosis. Cerebrovascular diseases due to basilar artery is more common in men than women. Anatomy of basilar artery and its branches are very complex and variable. So, detailed morphological knowledge is essential for proper diagnosis and treatment of neurological disorder.

Objective: To identify variations in the site of formation of basilar artery in relation to age.

Study Design: A cross-sectional type of study.

Place & period of Study: The study was carried out in the Department of Anatomy, Dhaka Medical College, Dhaka, from January 2010 to December 2010.

Materials: 70 postmortem basilar arteries were collected from unclaimed dead bodies that were under examination in the morgue of the Department of Forensic Medicine, Dhaka Medical College Dhaka. The study was approved by the Ethical Review Committee (ERC) of Dhaka Medical College.

Methods: The samples were divided into three different age groups i.e. Group A (15-30 years) Group B (31-45 years) and Group C (46-60 years). Formalin fixed brain was washed with plain tap water to remove excess formalin and was kept on metallic tray. Site of formation of basilar artery was examined carefully by hand magnifying glass and noted.

Results: In the present study, 72.2% of basilar artery was formed at pontomedullary junction and 35.7% was formed below pontomedullary junction.

Conclusion: In the present study, the commonest site of formation of basilar artery was found at ponto medullary junction and 2nd commonest site was below pontomedullary junction but no formation above pontomedullary junction was found. Further studies to find out the cause and functional / clinical correlations of this variation are recommended.

Key Words: Basilar artery, Pontomedullary junction.

Introduction:

Basilar artery is one of the main arteries that supplies the posterior portion of brain, the area supplied by basilar artery is also called posterior

1. Lecturer, Department of Anatomy, Shaheed Suhrawardy Medical College, Dhaka
2. Professor & Head of the Department of Anatomy, Dhaka Medical College, Dhaka-1000.
3. Assistant Professor, Department of Anatomy, Dr. Sirajul Islam Medical College, Dhaka.
4. Assistant Professor, Department of Anatomy, Green Life Medical College, Dhaka-1205.
5. Assistant Professor, Department of Anatomy, Jahurul Islam Medical College.
6. Assistant Professor, Department of Anatomy, Dhaka Central International Medical College, Dhaka
7. Associate Professor (c.c.), Department of Anatomy, Dhaka Medical College, Dhaka

Correspondence: Dr. Anjuman Ara Sultana

cerebral circulation^{1,2}. Basilar artery is the most important artery in the posterior circulation³. Basilar artery is formed by the union of right and left vertebral arteries at the lower border of the pons or mid medullary level^{1,4 & 5}. Then it courses upwards along 'basilar groove' on the anterior surface of the pons, and it ends at the upper border of pons by bifurcating into two posterior cerebral arteries⁶. The posterior cerebral artery, branch of basilar artery completes an arterial polygon called the 'circle of Willis', which is the principal arterial anastomotic trunk of brain¹. Normally little blood flows around this circle, if one major vessel occluded the communicating arteries may allow critically important anastomotic flow and prevent neurological damage⁷. The most frequent

and severe atherosclerotic (degenerative proliferative) change occur in upper and lower part of basilar artery and the first part of the posterior cerebral artery. Severe narrowing of vessels sufficient to cause vascular insufficiency occurred in 2% of case at age 30-40 years and in as many as 6-8% in patient from age 60-70 years¹. Anatomical variation occasionally occurs in basilar artery and its branch. Most frequent anatomical variation of basilar artery is short segments of duplication or island formation. The superior cerebral artery may be multiple⁸. The proximal and mid basilar arteries are the most common sites of stenosis and most often cause infarction in the pons⁹. Aneurysm often develops at the site of branching of basilar artery and near the arterial circle and they can rupture or leak causing subarachnoid hemorrhage¹⁰. Cerebrovascular disease was found 22% in the year 2004¹¹ in Mymensingh Medical College Hospital. Stroke due to basilar artery comprises approximately 10% to 15% of all stroke, more common in man than woman. Structures commonly affected by basilar artery infarction are the brain stem (60%) cerebellum (50%). Basilar artery related clinical condition such as posterior circulation stroke, migraine, aneurysm, atherosclerotic changes are very common throughout the world. Knowledge of anatomy of the basilar artery and its branches in Bangladeshi people are necessary for neurosurgeons, neurologists for proper diagnoses and treatment of cerebrovascular diseases, aneurysm, tumour, epilepsy, migraine and other form of vascular anomalies.

Materials:

The present study was performed on 70 post mortem basilar arteries of different age groups collected from unclaimed dead bodies that were under examination in the morgue of the Department of Forensic Medicine, Dhaka Medical College, Dhaka from January 2010 to. December 2010. The study was approved by the Ethical Review Committee (ERC) of Dhaka Medical College. After legal formalities and requisite permission from the Department of Forensic Medicine the whole brains were collected within 24-36 hours of death. Soon after collection, each sample was gently washed with tap water on a dissection tray. Blood and blood

clots were removed. After collection of whole brain, 100ml of 40% formaldehyde solution was injected by using a 50cc syringe into the brain through the surfaces (superolateral and inferior surfaces). Then it was preserved in 40% formaldehyde solution (Origin Germany) for 15 days. After 15 days the present study was made with these fixed specimens.

Methods:

Place and duration of study: This study was carried out in the Department of Anatomy, Dhaka Medical College, Dhaka, Bangladesh, from January 2010 to December 2010. During the collection of the samples appropriate age, sex and the cause of death were noted from morgue’s record book and the samples were tagged bearing the code numbers for subsequent identifications.

Grouping of the samples: The samples were divided into three age groups according to Khalil¹². Detailed grouping and distribution of samples are shown in Table-I.

Table I

Grouping of samples of the present study (n = 70).

Group	Age limit in years	Number of samples
A	16-30	18
B	31-45	42
C	46- 60	10

Observation of site of formation of basilar artery:

Site of formation of basilar artery were examined carefully by hand magnifying glass and noted.

Results:

Results are shown in the Table –II, Figure- 1

Table – II

Site of formation of basilar artery at or below pontomedullary junction (PMJ) in different age groups

Age group	At PMJ		Below PMJ		P value
	No	%	No	%	
A (n=18)	13	(72.2)	5	(27.8)	>0.50 ^{ns}
B (n=42)	27	(64.3)	15	(35.7)	
C (n=10)	7	(70.0)	3	(30.0)	

Statistical analysis was done by Chi-square test, ns = not significant

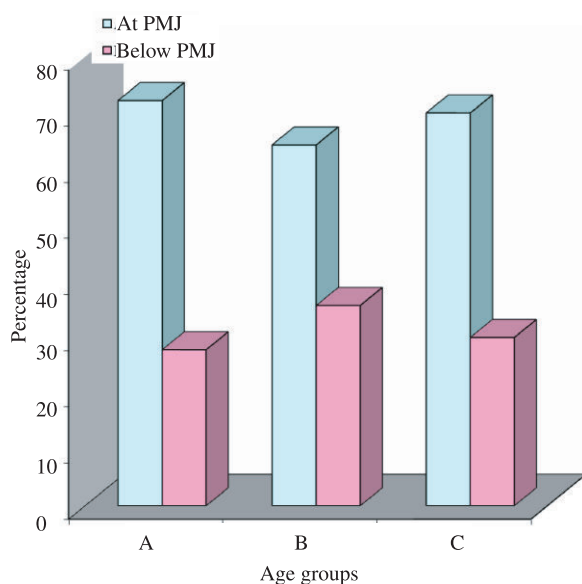


Fig.-1: Site of formation of basilar artery at or below the pontomedullary junction (PMJ) in different age groups

Group A : Age 16-30 years

Group B : Age 31-45 years

Group C : Age 46-60 years

Discussion:

In the present study site of formation of basilar artery at pontomedullary junction were 72.2% and below pontomedullary junction were 35.7%. Pai et al (2007) studied on 25 cadavaric specimens, and found the commonest site of formation of basilar artery at the pontomedullary junction, and the 2nd commonest site of formation of basilar artery below pontomedullary junction. The finding of the present study was also similar to Barcovitz and Moxham⁸, Rogers and Jacob¹³, Crossman⁴ and Snell⁵. Site of formation of basilar artery above the pontomedullary junction was not found which was similar to other studies.

Conclusion:

In the present study the commonest site of formation of basilar artery was found at ponto medullary junction and 2nd commonest site was below ponto medullary junction but above pontomedullary junction was not found. Further studies to find out the cause and functional / clinical correlations of this variation are recommended.

References:

1. Chusid JG. Disorder due to vascular disease of the central nervous system. Correlative

neuroanatomy & functional neurology. USA. Lange Medical Publications; 1985. 338-46.

2. Bartomirt and Bogguslasky. Vascular disorder of the posterior circulation-An anatomical-clinical overview. *Acenr.* 2004; 4(2): 7-9.
3. Flores SC. and Muengtaweepongsa S. Basilar artery- Thromboses. 2009; available from: <http://medicine.medscape.com/articel/1161044-overview>.
4. Crossman AR. ed. Neuroanatomy. In: Standring S, Ellis H, Heally JC, Johnson D, Williams A, Collins P, et al. eds. *Gray's Anatomy: The anatomical basis of clinical practice.* 39th ed. Edinburgh: Elsevier Churchill Livingstone; 2005. 298-301.
5. Snell RS. The blood Supply of the brain and spinal cord. in: *Clinical Neuroanatomy for medical student.* 8th ed. 2008. Philadelphia: Lippincott williams and wilkins; 469-97.
6. Pai BS, Varma RG, Kulkarni RN, Nirmala S, L. Microsurgical anatomy of posterior circulation. *Neurol India.* 2007; 55(1): 361-41.
7. Nolte J. Blood supply of the brain. In: *The human Brain.* 5th ed. St. Louis: Mosby; 2002: 119-46.
8. Berkovitz BKB, Moxham BJ. A textbook of head and neck anatomy. 1st ed. Barcelona: Wolfe Publishing Ltd; 1988: 577-80.
9. Woolfenden A, tong D, Norbash A, Ali A, et al. Basilar artery stenosis clinical and neuro-radiographic feature. *Journal of stroke and cerebrovascular Disease.* 2009; 9(2): 57-63.
10. Tulleken C A F. and Luiten L F B. The basilar artery bifurcation: Microscopical anatomy. *Acta Neurochir.* 2005; 85: 50-55.
11. Ahmed S, Hossain S, Rahman MK. Disease Pattern at Neurology Outpatient Department of Mymensingh Medical College Hospital, Mymensingh-One Year Study in the Year 2002. *Bangladesh Journal of Neuroscience.* 2006; 22(2): 89-92.
12. Khalil M. An anatomical study of the circle of Willis and other major arteries at the base of the brain in Bangladeshi people. (M.Phil. Thesis). Dhaka: IPGMR, University of Dhaka; 1992
13. Rogers AW, Jacob S. The blood supply of head and neck. A textbook of anatomy. 1st ed. Edinburgh: Churchill Livingstone; 1992. 597-99.