

Morphometric Study of Posterior Aspect of Distal End of Human Adult Dry Left Humerus

Jubaida Gulshan Ara¹, Humaira Naushaba², Khalid Mosharof Hossain Khan³, Tahmina Begum⁴, Laila Farzana Khan⁵, Abul Kalam Mohammad Kabir⁶

Abstract

Context: Humerus is the long bone of upper limb. The aim of this study is to find out valuable normative data of posterior aspect of distal end of human adult dry left humerus that can enrich the anatomists and play an important role to anthropological researchers and forensic experts. It is also important for orthopedic surgeons in surgical reconstruction of distal humeral fracture and correction of congenital and traumatic anomalies.

Materials and Methods: A cross sectional analytic type of study was conducted in the department of Anatomy of Sir Salimullah Medical College, Dhaka from July 2011 to Dec 2012.

Two hundred left sided humerus were collected from the students of Department of Anatomy of Sir Salimullah Medical College, Dhaka and Dhaka National Medical College, Dhaka.

Measurements were taken from posterior aspect of distal end of left humerus by direct physical standard osteometric method and recorded in the metric unit centimeter (cm).

Result: The result revealed that the male values were higher than female. The measurements were statistically analysed. There were significant difference ($p=0.001$) between male and female values.

Keywords: Posterior aspect of distal end of left humerus, morphometry.

Introduction:

Skeletal morphology varies among populations. Each population have specific standard of identification in skeleton. The determination of sex and estimation of stature from bones play an important role in identifying unknown bodies, parts of bodies or skeletal remains¹. Humeral length

can also be estimated from fragmented bone length². So morphometric study of posterior aspect of distal end of humeral segment is very important in anatomy, forensic science and in archeology¹.

Specifically the distal humerus is known to be dimorphic and this is said to be due to differences in the carrying angle of the articulated humerus, radius and ulna^{3,4,5}. The increased lateral deviation of the forearm relative to the axis of the upper arm distinguishes females from males. This angle is said to be about 10 to 15° in males and 20 to 25° in females⁶.

Distal humerus fractures make up 0.5 to 2% of all fractures, but up to 30% of fractures occur involving the elbow⁷. Palva-nen et al⁸ identified more than a 2-fold increase in the incidence

-
1. Associate Professor & Head, Department of Anatomy, Mugda Medical College, Dhaka.
 2. Professor and Head, Department of Anatomy Sir Salimullah Medical College, Dhaka.
 3. Assistant Professor, Sports Medicine and Arthroscopy, NITOR, Dhaka.
 4. Associate Professor, Department of Anatomy. Sir Salimullah Medical College . Dhaka.
 5. Assistant Professor. Department of Anatomy, Dhaka National Medical College . Dhaka
 6. Assistant Professor, Department of Anatomy, Shaheed Tajuddin Medical College, Gazipur.

Correspondence: Dr. Jubaida Gulshan Ara

of distal humerus fractures in older women above 60 years. The distal humerus has a unique and special anatomy in which fractures provide reconstructive problems. Olecranon fractures occur in 10% of all upper extremity lesions.⁹

This morphometric study may also be important for orthopedic and plastic surgeons for surgical treatment, reconstruction and rehabilitation process of distal humeral fracture and correction of congenital and traumatic anomalies. It is essential for the orthopedic surgeons for applying prosthesis, nailing and performing arthroscopy. Various implants according to the distal humerus are available and these plates are contoured specifically according to the anatomy of this region. The measurement of different dimensions of human dry left humerus will develop a standard base line from which we can compare different morphometric parameters with the findings of other researchers.

Materials:

A cross sectional analytical type of study was performed on two hundred (n=200) (male n= 117 and female n= 83) left sided adult dry humerus collected from the students of the Department of Anatomy, Sir Salimullah Medical College (SSMC), Dhaka and Dhaka National Medical College, Dhaka during the period of July 2011 to December 2012. The determination of sex was estimated from four features of posterior aspect of distal humerus, these are: olecranon fossa shape, angle of medial epicondyle, trochlear constriction and trochlear symmetry.

Bones were measured by direct physical standard osteometric method. All the morphological measurements were recorded in the metric unit centimeter (cm).

Ethical Clearance: Ethical clearance for the study was approved by Ethical Review Committee of Sir Salimullah Medical College, Dhaka.

Methods

Procedure for measurement of different variables in posterior aspect of the distal end of humerus.¹⁰

1. The distance between the most proximal and distal point along the edge of olecranon fossa (Fig: 1)

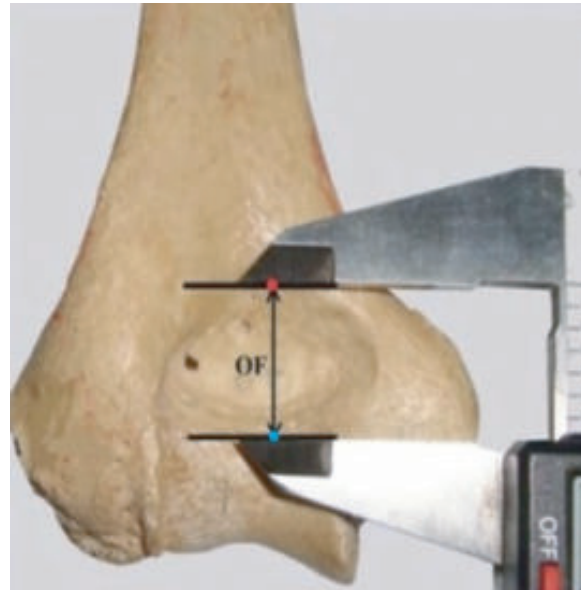


Fig: 1 The distance between the most proximal and distal point along the edge of the olecranon fossa was measured by digital slide calipers, OF-olecranon fossa.

A dot was given on the most proximal point and another dot was given on the most distal point along the edge of the olecranon fossa. The distance between two dots was measured and recorded by digital slide caliper.

2. The distance between a. the most proximal point of olecranon fossa and most distal point of trochlea
b. the most distal point of olecranon fossa and most distal point of trochlea (Fig.-2)

a. A dot was given on the most proximal point along the edge of olecranon fossa and a dot was given on the most distal point of trochlea. The distance between two dots was measured and recorded by digital slide caliper.

b. A dot was given on the most distal point of olecranon fossa and another dot was given on the most distal point of trochlea. The distance between two dots was measured and recorded by digital slide caliper.

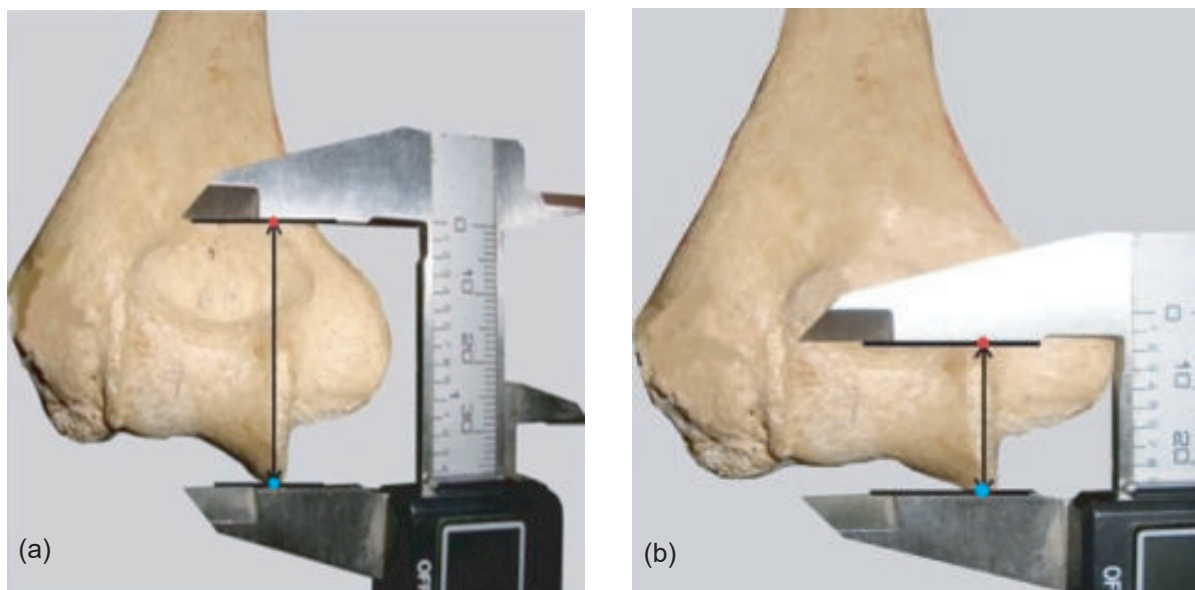


Fig.-2: Photograph showing the distance between a. the most proximal point of olecranon fossa and the most distal point of trochlea and b. most distal point of olecranon fossa and most distal point of trochlea of humerus was measured by digital slide caliper.

Results:

1. Distance between the most proximal and distal point along the edge of olecranon fossa:

The mean (\pm SD) distance between the most proximal and distal point along the edge of olecranon fossa of humerus was 2.08 ± 0.27 cm and 1.74 ± 0.21 cm in male and female respectively shown in Fig 3.

2. Distance between a.the most proximal point of olecranon fossa and the most distal point of trochlea b. most distal point of olecranon fossa and the most distal point of trochlea.

a. The mean (\pm SD) distance between the most proximal point of olecranon fossa and the most distal point of trochlea was $4.04 \pm .20$ cm and $3.51 \pm .25$ cm in male and female respectively as shown in Fig 4a.

b. The mean (\pm SD) distance between the most distal point of olecranon fossa and the most distal point of trochlea was 2.09 ± 0.17 cm and 1.68 ± 0.17 cm in male and female respectively as shown in Fig 4b.

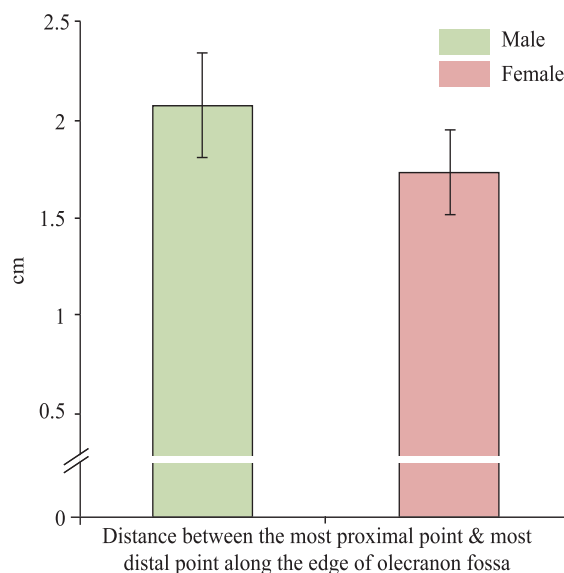


Fig. 3 Bar diagram showing distance between the most proximal and distal point along the edge of olecranon fossa of left humerus in male and female.

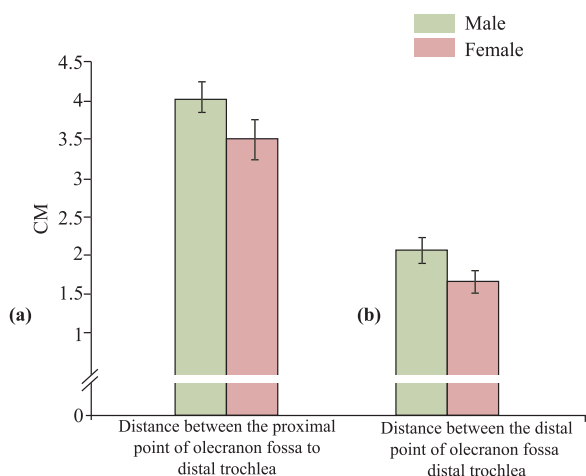


Fig.-4: Bar diagram showing the distance between a. the most proximal point of olecranon fossa and most distal point of trochlea and b. distance between the most distal point of olecranon fossa and distal point of trochlea of left humerus in male and female

Discussion:

The morphometric analyses suggest that there are some differences between the segments of humerus within different population groups. These discrepancies are due to various factors like ethnicity, race, culture, sex, age etc. along with the environmental influence affecting bone growth such as nutrition, physical development and genetic factors⁷.

Bangladeshi are mixed race of Austrics, Indo Aryan, Mongolians and Dravidians group¹¹. Indian population is also a racial admixture of the Caucasoids, Negroids, Mongoloids and Australoids.¹¹ Turkish people display a great variety of ethnic types. They possess physical features from the Caucasoids to Northern Mongoloids¹¹.

In the present study the mean (\pm SD) distance between proximal and distal point along the edge of olecranon fossa was found $2.08 \pm .27$ cm and $1.74 \pm .21$ cm in male and female respectively. Deniz Akman¹⁰ conducted a study on Turkish population who were Caucasoid by race in which this distance was $2.39 \pm .26$ cm on left side in male. Somesh, M S¹² worked on Indian population and found this distance was 1.90 ± 0.29 cm on left side in male.

The mean (\pm SD) distance between proximal point to olecranon fossa and distal trochlea was $4.04 \pm .20$ cm and 3.51 ± 0.25 cm in male and female respectively, Deniz Akman¹⁰ found this distance $3.97 \pm .34$ cm and Somesh M S¹² found this distance $3.57 \pm .43$ cm in male .

The mean (\pm SD) distance between distal point to olecranon fossa and distal trochlea was $2.09 \pm .17$ cm and $1.68 \pm .17$ cm in male and female respectively. Deniz Akman¹⁰ found this similar distance $1.97 \pm .25$ cm , Somesh MS.¹² found this distance 1.68 ± 0.22 cm in male.

In the present study the values were greater in male than female which was statistically significant ($p < 0.001$). Female study were not available in other countries. The present study was found dissimilar with the studies reported by other countries.

These dissimilarities might be due to ethnic and racial variation.

Conclusion:

The knowledge of the morphometric values of humerus segments is important in forensic, anatomic and archeological cases. It is also helpful for the clinicians in the treatment of distal end of humeral fracture and during placing implants for reconstruction of humerus.

References:

1. Mall GM, Hubig A, Buttner J, Kuznik R, Penning M, Gwaw, et al. A sex determination and estimation of stature from the long bones of the arm. *Forensic Sci Int* 2001; 117: 23-304.
2. Ceri G, Falys Falys CG, Schutkowski H, Weston DA. The distal humerus: a blind test of Rogers' sexing technique using a documented skeletal collection. *J. Forensic Sci* 2005; 50: 1289-93.
3. Grabiner. Grabiner MD. The elbow and radioulnar joints. Lea and Febiger, London. 1989
4. Fuss, Fuss FK. The ulnar collateral ligament of the human elbow joint. *J. Anat* 1991; 175: 203-12.

5. Kingston, Kingston B, Understanding Joints: A Practical Guide to Their Structure and Function. United Kingdom: Stanley Thornes Ltd. 2000.
6. Roger. Sex determination of adolescent skeletons using the distal humerus. *J Am Phys Anthropol* 1999;140:143-48.
7. WEBB LX. Fractures of the distal humerus. In: Bucholz, R. W., Heckwan, J. D., eds.: Rockwood and Green's Fractures in Adults. Philadelphia, Lippincott Williams & Williams 2001, 953–72.
8. Palvanen M, KannusP, Niemi S, Parkkari J. Secular trends in the *osteoporotic* fractures of the distal humerus of elderly women. *Europ J Epidemiol*,1998; 14: 159–64.
9. Rommens PM. Olecranon fractures in adults: factors influencing outcome. *Injury J. care injured* 2004; 34: 1157-94.
10. Deniz Akman, The morphometric measurement of humerus, *Turkey Journal Medical Science*. 2006; 36(2): 81-89.
11. Wikipedia. Wikipedia. Race and ethnicity of Bangladeshi. Available. <http://en.wikipedia.org/wiki/Bengal>. 2013.
12. Shomesh MS. Morphologic study of the humerus segments in Indian population. *International Journal. Morphol* 2011; 29(4): 1174-80.