

Variations in the Superior Articular Facets of the Atlas Vertebra

Sadia Rahman¹, Shamim Ara², Farhana Hossain³, Sharmin Rahman⁴, Afroz Ahmed⁵

Abstract:

Context: Variations in the shape of the superior articular facets of the atlas vertebra between male and female is an interesting aspect of physical anthropometry. So that a standard data can be established for future studies in anatomy that can help forensic experts, spine surgeons, orthopedic surgeons and radiologists to adopt appropriate plans for diagnosis & treatment.

Materials and methods: The study material consists of 152 (one hundred and fifty two) human dry ossified atlas vertebrae of unknown sex. The study samples were divided into male and female groups using the "discriminant function analysis technique" and the shapes of superior articular facets of atlas vertebrae were identified by simple observation method.

Results: In the male atlases, 45.7% kidney-shaped, 30.9% oval-shaped, 9.9% dumb-bell shaped and 13.6% figure of 8-shaped superior articular facets were found on right side and 40.7% oval-shaped, 35.8% kidney-shaped, 16.0% dumb-bell-shaped, 7.4% figure of 8-shaped superior articular facets were found on left side. In the female atlases 62% oval-shaped, 33.8% kidney-shaped, 2.8% dumb-bell-shaped and 1.4% figure of 8-shaped superior articular facets were found on right side and 63.4% oval, 31% kidney shaped, 4.2% dumb-bell shaped, 1.4% figure of 8-shaped superior articular facets were found on left side.

Key words: Atlas, superior articular facet.

Introduction:

The adult vertebral column consists of 33 vertebrae. There are seven cervical vertebrae, among them atlas is the first¹. It is ring shaped and does not have a body and spinous process like other cervical vertebrae². The atlas vertebra has undergone many structural modifications⁸. The vertebral arch has become modified to form a thick lateral mass on each side joined at the front by a short anterior arch and a longer posterior arch at the back³. The lateral masses are ovoid and each

bears a superior articular facet and faces superomedially. The condyles of the occipital bone forms an atlanto occipital joint with superior articular facets of atlas vertebra.

Superior articular facet of the atlas with a different shape is an indication of the further restriction of movement at atlanto-occipital joint. Abnormal hypertrophy of these facets is a recognized cause for narrowing of vertebral canal and consequent neurological features⁴. Assessment of morphological variation of superior articular facets are done before performing any clinical procedure in its proximity such as atlanto occipital transarticular approach which is useful for surgery of anterior extradural lesions of the cranio vertebral junction⁹. On the other hand atlas vertebra is the target of several fixation procedures including Cervical 1, Cervical 2 transarticular screw fixation⁶.

Materials and methods:

A total 152 fully ossified and dried human atlas vertebrae of unknown sex were collected from

1. Assistant Professor, Department of Anatomy, Ibrahim Medical College, Dhaka.

2. Professor & Head, Department of Anatomy, Dhaka Medical College, Dhaka.

3. Assistant Professor, Department of Anatomy, Bangladesh Medical College, Dhaka.

4. Assistant Professor, Department of Anatomy, Ad Din Woman's Medical College, Dhaka.

5. Assistant Professor, Department of Anatomy, Anwar Khan Modern Medical College, Dhaka.

Correspondence: Dr. Sadia Rahman





Department of Anatomy of Dhaka Medical College and other government and non-government medical colleges in Dhaka city. Then the sex of collected bones was determined by a multivariate linear discriminant function analysis technique¹⁰. By discriminant analysis technique and also with the help of various metric methods used by different authors, the sex was determined and the grouping was done (Table-I).

Table-I
Grouping of the sample:

Sex	Number of atlas vertebrae
Male	81
Female	71

Then different shapes of superior articular facets were observed and recorded by morphological examination.

Table-II
Different shapes of superior articular facet

Oval shaped	Kidney shaped	Dum bell shaped	Figure of 8 shaped
			

Ethical Clearance: This study was approved by the Ethical Review Committee of Dhaka Medical College, Dhaka

Results: Results are shown in figure -1&2.

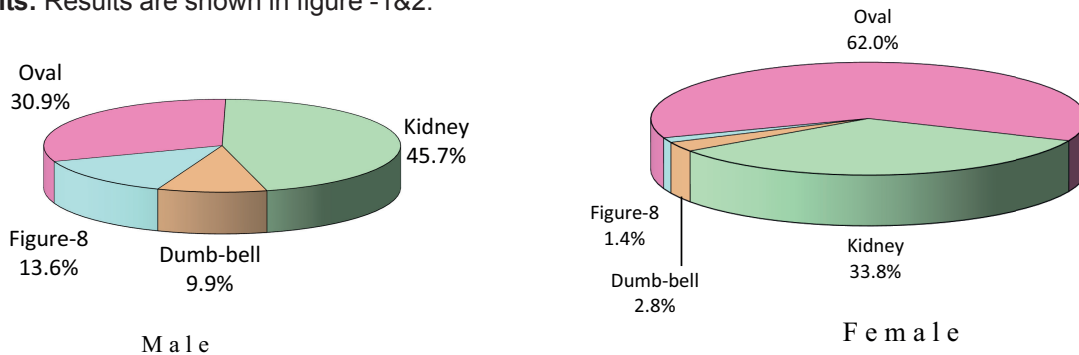


Fig.1: *Different shapes of right superior articular facets of atlas vertebrae of male and female*

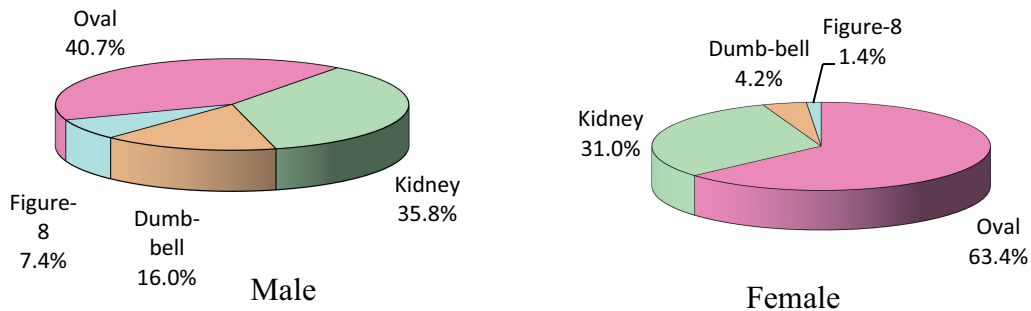
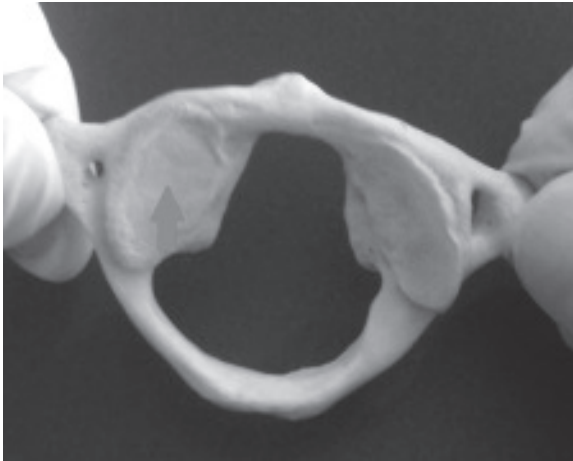
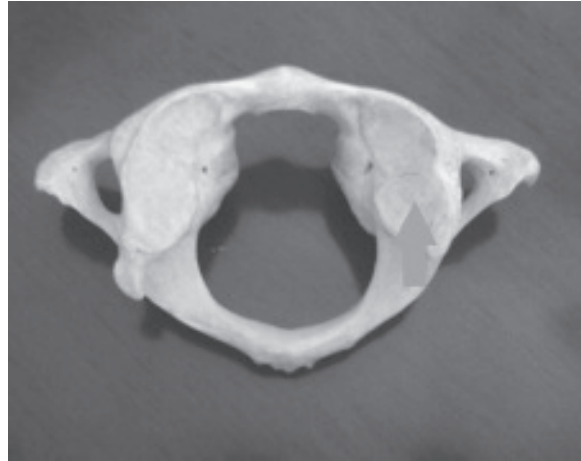


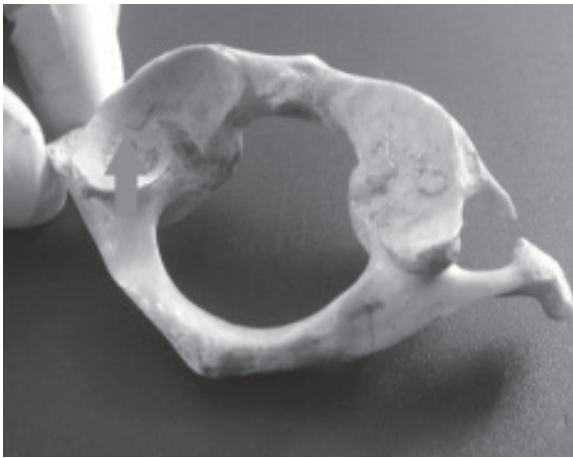
Fig. 2: *Different shapes of left superior articular facets of atlas vertebrae of male and female*



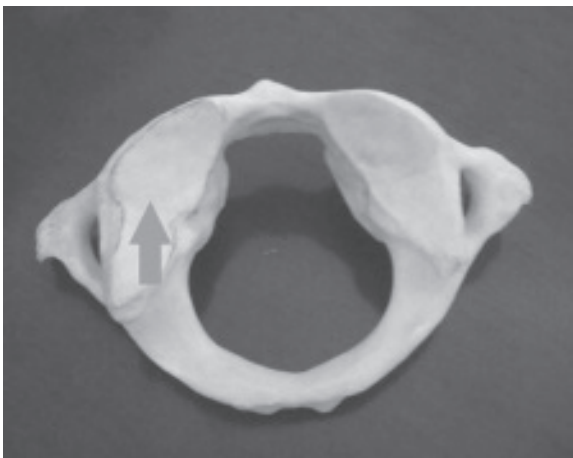
Photograph showing oval shaped (arrow marked) superior articular facet.



Photograph showing figure of 8 shaped (arrow marked) superior articular facet.



Photograph showing kidney shaped (arrow marked) superior articular facet.



Photograph showing dumb-bell shaped (arrow marked) superior articular facets.

Discussion:

In the present study 9.9% and 16% dumb-bell shaped superior articular facets were found in right and left side respectively in male and that of female were 1.4% and 4.2%. But Lalit, et al⁴ reported 70% and 66% dumb-bell shaped superior articular facets in right and left side respectively (irrespective of sex). Sing⁷ also reported 67% and 69% dumb-bell shaped superior articular facets in right and left side respectively. In the present study 30.9% and 40.7% oval shaped superior articular facets were found in right and left side respectively in male and that of female were 62% and 63.4%. In the present study 45.7% and 35.8% kidney shaped superior articular facets in right and left side respectively in male were found and that of female were 33.8% and 31%. Sengul and Kadioglu⁵ reported 72% oval and 28% kidney shaped superior articular facets in atlas vertebrae (irrespective of sex). In the present study 13.8% figure of 8 shaped superior articular facets were found in right and left side respectively in male and that of female it were 1.4% both in right and left side. Lalit, et al⁴ reported 33.3% and 28% figure of 8 shaped superior articular facets in right and left side respectively (irrespective of sex).

Conclusion:

The present study exhibited that most of the

superior articular facets of male were kidney shaped and female were oval shaped. Radiographic and computed tomographic study and measurement of living atlas vertebrae and comparison between the radiographic findings with the morphometric study of human dry ossified atlas vertebrae are recommended.

References:

1. Newell RLM. Functional Anatomy of Musculo Skeletal System. In: Strandring S. Gray's Anatomy: The anatomical basis of clinical practice. 40th ed. London: Churchill Living Stone; 2008. 705-74.
2. Snell R.S. The back. In: Clinical Anatomy by Region. 8th ed. Philadelphia: Lippincott Williams and Wilkins; 2008. 923-70.
3. Sinnatamby CS. Head and Neck and Spine. In: Last's Anatomy Regional and Applied. 11th ed. London. Churchill Living Stone; 2006. p. 321-447.
4. Lalit, M. et al. The Morphological analysis of the Superior Articular Facet of the adult human Atlas vertebra. Journal of clinical and diagnostic research.2011; 5(2): 274-77.
5. Sengul,G. and Kadioglu,H.H. Morphometric anatomy of the Atlas and Axis vertebrae. Turkish Neurosurgery. 2006; 16(2): 69-76.
6. Naderi S, Chakmac H, Acar F, Arman C, Mertol T, Arda MN. Anatomical and computed tomographic analysis of C₁ vertebra. Clinical neurology and Neurosurgery. 2003; 105(1): 245-48.
7. Singh,S. Variations of the superior articular facets of atlas vertebrae. Journal of Anatomy. 1965; 99(3): 565-71.
8. Gosavi SN, Vatsalaswamy P. Morphometric study of atlas vertebra using manual method. Malaysian Orthopaedic Journal.2012; 6(3): 18-20.
9. Kawashima M, Tanriover N, Rhoton AL. Extreme lateral variants of the atlanto occipital transarticular approach to anterior extradural lesions of the cranio verebral junction. Anatomic Reports Of Neurosurgery. 2003; 53(3): p. , E.A. A pilot study using the first cervical vertebra as an indicator of race. Journal of Forensic Science.1997; 42(6): 1114-18.