

Femoral Neck Shaft Angle of Adult Bangladeshi Male

Shakera Akter¹, Shamim Ara², ABMG Kibria³, Farzana Begum⁴, Auni Kamal⁵

Abstract

Background: Femoral neck shaft angles (FNSAs) are an important measure for the assessment of hip and planning of operations in the upper part of femur. From a bio-mechanical standpoint bone geometry is related to the body weight. Geometric parameters like the diameter of the femoral head and neck, the length of neck and the femoral neck shaft angle are determinant factors of osteoporotic patients.

Objective: The study was carried out to measure the right and left femoral neck shaft angles from radiographs and to provide a base line data of femoral neck shaft angle of Bangladeshi adult male so that adequate planning and preoperative selection of orthopaedic implant for surgeries involving femoral neck can be taken.

Materials and method: The study was a cross-sectional analytical type which involved measuring femoral neck shaft angles (FNSAs) of anterior posterior views of 25 male pelvis, showing the hip joint and proximal part of femur of both sides. Radiographs of adult male pelvis commented normal by the radiologist were taken as study materials. Femoral neck shaft angles (FNSAs) were measured by goniometer.

Results: Male neck shaft angle of the femur (FNSAs) revealed that there were no significant difference in FNSAs between right and left side.

Keywords: Femur, neck-shaft-angle (FNSA).

Introduction:

The femur is the largest and the strongest bone in the body. The hip joint is formed by the head of the femur and acetabulum. The angle is known by many names including neck shaft angle (NSA), collodiaphyseal angle (CDA), diaphysio-femoral angle, angle of inclination or Mikuliczangle and caputcollum - diaphyseal angle¹. This angle is necessary to enable the femoral shaft to swing clear of the pelvis during mobility². The neck shaft

angle varies with age, stature and width of the pelvis. When this angle is $>135^\circ$ the condition is known as coxavalga. When the angle is $<120^\circ$ it is known as coxavara. The angle of femoral neck reduces with aging. In early infancy the neck shaft angle is about 150° , in childhood 140° , in adult it is about 125° and in elderly about 120° ³.

Anatomical study of femur serves helpful data to understand different aspects of clinical disease condition, including fixation of femoral neck fracture, changes in osteoporosis, associated congenital anomaly as well as medicolegal cases⁴. It is also helpful in designing and bioengineering construction of orthopaedic implants and hip prosthesis.

Material and Methods:

A cross-sectional analytical study was carried out for measuring the neck shaft angles from radiograph of adult male pelvis. The radiographs were collected from different medical college

1. Associate Professor (C.C), Department of Anatomy, International Medical College, Gushulia, Tongi, Gazipur
2. Professor & Head, Department of Anatomy, Dhaka Medical college, Dhaka
3. Assistant Professor, Department of Orthopedics, Shaheed Monsur Ali Medical College and Hospital, Uttara
4. Professor (C.C) & Head, Department of Anatomy, Army Medical College, Bogra Cantonment.
5. Assistant Professor, Department of Anatomy, International Medical College, Gushulia, Tongi, Gazipur

Correspondence: Dr. Shakera Akter

hospital of Dhaka city. X-ray anterior-posterior (AP) view of the pelvis showing both hip joints and upper femora were selected. The radiographs selected were those with no visible pathology and were commented as normal by the radiologist. The measurement were carried out with the aid of viewing box and single handheld 360° goniometer. The measurement were done by two researchers and the average value was recorded as the final value.

To measure the femoral neck shaft angle, longitudinal axis of neck and longitudinal axis of shaft were determined.

A. Longitudinal axis of neck: To find out the longitudinal axis of neck lowest limit of head circumference was determined then midpoint of intertrochanteric line was determined. Line joining the two points is neck axis. Then neck axis was extended to cut shaft axis. (Fig 1).

B. Longitudinal axis of shaft: Is the line joining the midpoint of the shaft below the lesser trochanter up to the greater trochanter. (Fig 1).

C. Femoral neck shaft angle (FNSA): Intersection between the longitudinal axis of neck and the longitudinal axis of shaft (Fig.-1).

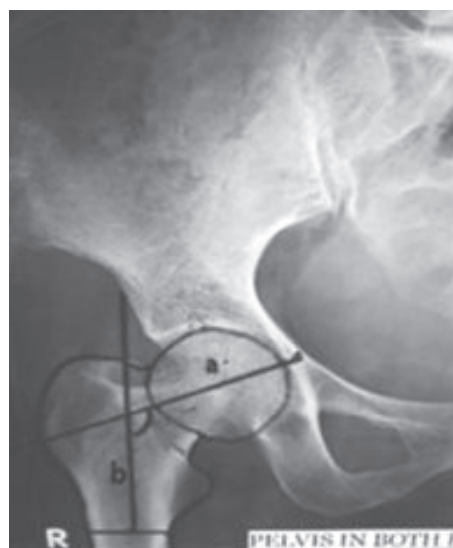


Fig.-1: Arrow showing femoral neck shaft angle (FNSA). Line a: longitudinal axis of neck, Line b: longitudinal axis of shaft

Ethical Clearance:

This study was approved by the Ethical Review Committee of Dhaka Medical College, Dhaka

Results:

A total 40 NSAs were analyzed from 25 adult male patients. The value of NSA of male ranges from 115° to 145° with a mean of 131.99°±5.02° the mean value for the right and left side for adult male were 132.05°±6.62° and 131.94°±6.43° respectively (Table-I).

Table I
Adult male neck shaft angle of right and left femur

Parameter	Lowest value (°)	Highest value (°)	Modal NSA (°)	Mean±SD value (°)	P value
Right NSA	125	136	130	132.05±6.62	0.0001
Left NSA	124	136	130	131.94±6.43	

Table II
Comparison of NSA of present study with other studies

Sl.no	Authors	Year	Sample size	Population	Method	FNSAMean ±SD	P value
1	M lequesne	2004	112	French	X- ray	132.8°±4.4	0.0001
2	PF Umebese	2005	110	Nigerian	X- ray	132.8°±4.4	
3	M Inam	2011	70	Pakistan	X- ray	134°±5.6°	
4	Present study	2017	25	Bangladeshi	X- ray	132.05°±4.4°	

Discussion:

The studies on neck shaft angles have been done by different authors in different parts of the world. Variations in neck shaft angle has been found and this can be attributed to varying level of activity, genetics, race, diet and lifestyle.^{5,6}In the present study the mean value NSAs were $132.05 \pm 6.62^\circ$ and $131.94^\circ \pm 6.43^\circ$ on the right and left side respectively. There were no significant differences on the right and left NSA in the present study which was similar to the findings of most of the other author (table-II).

The importance of NSAs lies in diagnosis, treatment of various orthopaedics condition like developmental dysplasia , osteoarthritis of hip, slipped capital femoral epiphysis and various valgus or varusosteomies^{7,8}. It is hoped that these morphometric finding on NSA could be of some use possibly in designing prosthesis for Bangladeshi population.

References:

1. Wright D, Whyne C, Hardisty M, Kreder HJ, Lubovsky O. Functional and anatomic orientation of the femoral head. Clin Orthop Relat Res. 2011; 469(9):2583–09.
2. Sugano N, Noble PC, Kamaric E, Salama JK, Ochi T, Tullos HS. The morphology of the femur in Konig G. Radiography of the proximal end of femur for measurements of angles (author’s translation). Z OrthopGrenzgeb. 1977; 115(3):310–20.
3. Konig G. Radiography of the proximal end of femur for measurements of angles (author’s translation). Z OrthopGrenzgeb. 1977; 115(3): 310–20.
4. Ravichandran D, Muthukumaravel N, Jaikumar R, Das H, Rajendran M. Proximal femoral geometry in Indians and its clinical applications. J AnatSoc India. 2011; 60:6-12.
5. Togwood PA, Skalak A, Cooperman DR. Proximal Femoral Anatomy in the normal human population. ClinOrthopaedRel Res. 2008; 467:876-85.
6. Saika KC, Bhuyan SK, Rongphar R. Arthropometric study of the hip joint in northeastern region population with computed tomography. Indian J Orthop. 2008; 42:260-6.
7. Serafimov L. Biomechanical influence of the innominate osteotomy on the growth of the upper part of the femur. Clinical Orthopaedics& Related Research. 1974; 98:39-40.
8. Lechler P, Frink M, Gulati A, Murray D, Renkawitz T, Bucking B, et al. The influence of hip rotation on femoral offset in plain radiographs ActaOrthop. 2014; 85(4):389–95.