

Observational Study of Diaphyseal Nutrient Foramina in Fully Ossified Dry Human Left Tibia

Mahbuba Akter¹, Humaira Naushaba², Laila Farzana Khan³, Fahmida Zaman⁴, Israt Jahan Tania⁵

Abstract:

Context: Nutrient foramen is an opening through which the nutrient artery enters and supplies the shaft of the long bones. An understanding of the number and location of diaphyseal nutrient foramina on tibia is very important clinically, especially for orthopedic and vascular surgeons as well as to radiologists for planning of treatment.

Materials and methods: This is an observational descriptive type of study which was carried out in the department of Anatomy of Sir Salimullah Medical College (SSMC), Dhaka from July 2014 to June 2015 performed on two hundred (n=200; male=102 & female=98) fully ossified dry human left tibia. This study was carried out on the samples by direct observational method.

Results: The nutrient foramen was single in number in 99% samples, double in number in 1% samples. The location of nutrient foramen was observed on the posterior surface in 97.5% cases and on the antero-lateral surface in 2.5% cases. No nutrient foramen was observed on the antero-medial surface.

Conclusion: The anatomical knowledge gained from this study and the obtained recorded data can be useful in certain surgical procedures as well as bone transplant, reconstruction surgery, tumor resection and microvascular surgery.

Keywords: Human tibia, nutrient foramen

Introduction

A nutrient foramen or vascular channel are small tunnels in the cortex of long bones that contain nutrient arteries and peripheral nerves¹. The main blood supply to long bones is from diaphyseal nutrient arteries, especially during active growing period in the embryo and fetus, and during the early phases of ossification². The long bone is supplied by nutrient artery which enters the bone obliquely through nutrient foramen which is directed away from the growing end. The nutrient artery supplies the bone marrow and the inner two third of the

compact part of the shaft. During childhood, long bones receive about 80% of the interosseous blood supply from nutrient arteries and in case of their absence, the vascularization occurs through periosteal vessels³. The location of nutrient foramen does not have a significant relationship with bone length and number of ossification centers^{4,5}. Location and number of nutrient foramina in long bone is important in orthopedic surgical procedure as well as in medicolegal cases. In free vascular bone grafting, the nutrient arterial supply is extremely important and is preserved to promote fracture repair, a good blood supply being necessary for osteoblast and osteocyte cell survival, as well as facilitating graft healing in the recipient⁶. An accurate knowledge of the location of the nutrient foramina in long bones help in preventing intraoperative injuries in orthopedic as well as in plastic and reconstructive surgery⁷. The areas or regions with a good blood supply heal more rapidly than those with a poor blood supply. The tibia is a good example of such process.

1. Assistant Professor, Department of Anatomy, ZH Sikder Women's Medical College, Dhaka.
2. Professor and Head, Department of Anatomy, Sir Salimullah Medical College, Dhaka.
3. Associate Professor, Department of Anatomy, Dhaka National Medical College, Dhaka.
4. Assistant Professor, Department of Anatomy, MH Samorita Medical College, Dhaka.
5. Assistant Professor, Department of Anatomy, City Dental College, Dhaka.

Correspondence: Dr. Mahbuba Akter

Location is most frequently on the 1st part which is of much clinical significance because this explains why the lower end of tibia is less vascular and therefore non-unions delayed union or malunion are common on the lower part of shaft of tibia⁸.

In transplant techniques, the statistical data about nutrient foramen and nutrient artery in long bone is required. The preserved nutrient blood flow is essential for the survival of the osteocytes⁹. Preoperative planning of the procedures is vital for all such surgical interventions, together with an appropriate understanding of the extraosseous vascular supply for a successful outcome¹⁰.

So the knowledge of nutrient foramina is essential in bone transplant, reconstruction surgery, tumor resection and during placing internal fixation device^{11,12}. The findings will enlighten the clinicians and anatomists.

Materials and methods

This is an observational descriptive type of study which was carried out in the department of Anatomy, Sir Salimullah Medical College (SSMC), Dhaka, from July, 2014 to June, 2015. The study was performed on two hundred (n=200; male=102 & female=98) fully ossified dry human left tibia and was carried out by direct observational method.

The following variables were observed -

- i. number of nutrient foramen
- ii. location of nutrient foramen

Procedure for determination of number and location of nutrient foramen

The nutrient foramen was identified by the presence of a well-marked groove, often slightly raised edge at the commencement of the canal (Fig 1). Only diaphyseal nutrient foramen of tibia was observed. A fine metallic wire was passed through each foramen to confirm their patency. The presence or absence, number and location of nutrient foramen in relation to specific border or surface of the shaft were observed, counted and recorded.

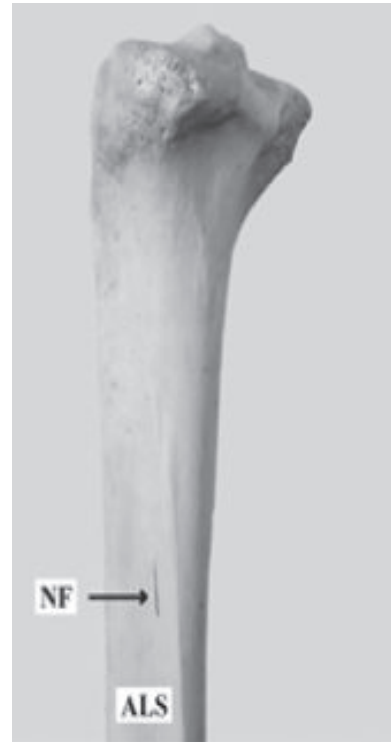


Fig.-1: Nutrient foramen on anterolateral surface.

Ethical Clearance:

The study was approved by the Ethical Review Committee of Sir Salimullah Medical College, Dhaka.

Results

Nutrient foramen was singular in number in 99% samples and double in number in 98.04% tibia (Table I) samples. Single nutrient foramen were more in female (100%) than in male (1%). Double nutrient foramina was absent in female. Distribution of location of nutrient foramen between male and female is shown in Table II. It was found that 97.5% tibia had nutrient foramen on the posterior surface and 2.5% tibia had on the antero-lateral surface. On the posterior surface nutrient foramina were more in female (99%) than in male (96.1%) and on the antero-lateral surface nutrient foramina were more in male (3.9%) than in female (1%). Nutrient foramina was absent on the anteromedial surface of tibia.

Table-I
Number of nutrient foramen on the shaft of left tibia

Number of nutrient foramen	Both sexes(n=200)		Male(n=102)		Female(n=98)	
	Frequency	Percentage (%)	Frequency	Percentage (%)	Frequency	Percentage (%)
Single	198	99.0	100	98.04%	98	100%
Double	2	1.0	2	1.96%	0	0%
Total (n)	200	100.00	102	100.00	98	100.00

Table-II
Location of nutrient foramen on the shaft of left tibia

Location of nutrient foramen	Both sexes		Male		Female	
	Frequency	Percentage (%)	Frequency	Percentage (%)	Frequency	Percentage (%)
Posterior surface	195	97.5	98	96.1	97	99.0
Antero-lateral surface	5	2.5	4	3.9	1	1.0
Total (n)	200	100.00	102	100.00	98	100.00

Discussion

The diaphysis of the long bones are irrigated by one or more nutrient arteries that pierce through compact bone and divide the medullary cavity into ascending and descending branches¹³. It is generally agreed that the vessels that occupy the nutrient foramen are derived from those that took part in the initial invasion of the ossifying cartilage. So the nutrient foramen was at the site of original centre of ossification. There is variations in number and location of nutrient foramen. In tibia, the nutrient artery usually arises directly from the popliteal or from the posterior tibial arteries. The arrangement of the diaphyseal nutrient foramina in the long bones usually follows a definite pattern. In the present study majority of bones had a single nutrient foramen. The findings of the present study were similar to the study reported by Kalpana T et al¹⁴ and Gupta. R.K and Kumari G. A¹⁵. They studied on Indian population. Most of the nutrient foramen were located on the posterior surface of fully ossified dry human left tibia.

Conclusion

The findings of the present study might be a help to the anatomist for constructing baseline data, to orthopedic surgeon and vascular surgeon for planning of treatment.

References:

1. Kate BR. Nutrient foramina in human long bones, J Anat Soc Ind 1971; 20(3): 139-45.
2. Lewis OJ. The blood supply of developing long bones with special reference to the metaphyses, J Bone Joint Surg 1956; 38B: 928-33.
3. Trueta J. Blood Supply And The Rate of Healing of Tibial Fractures. Clin. Orthop. Rel. Res., [online] 1974; 105: 11–26.
4. Patake, V.R. Diaphysal nutrient foramina in human long bones. J. Anat. [online] 1977; 101:813-22.
5. Shulmann, S.S. Observations of the nutrient foramina of the human radius and ulna. Anat. Rec., [online] 1959; 134: 685-9.
6. Kothapalli J, VRS. The diaphyseal nutrient foramina architecture - a study on the human upper and lower limb long bones. IOSR Journal of Pharmacy and Biological Sciences, [online] 9, 36-41.
7. Kizilkanat., et al. Location, number and clinical significance of nutrient foramina in human

- long bones, national journal of medical research, 2007; 189(1): 87-95.
8. Mysorekar, VR. Diaphysial Nutrient Foramina In Human Long Bones, national journal of medical research, [online], 1967. 813-22.
 9. Nagel A. The clinical significance of the nutrient artery, Orthop Rev 1993; 22: 557-61.
 10. Schiesel A, The nutrient artery canal of the femur a radiological study in patients with primary hip replacement. Skeletal Radial., [online] 2004;33(2): 142-9.
 11. Sendemir & Cimen. Diaphysial nutrient foramina in human long bones. J Anat, [online] 1993; 101(4): 813-22.
 12. Sol MD. Diaphyseal nutrient foramina in the femur, tibia and fibula bones, Int J Morphol,[online] 2007; 25(2): 305-8.
 13. Trueta J, Blood Supply and The Rate of Healing of Tibial Fractures. Clin. Orthop. Rel. Res., [online] 1974; 105: 11–26.
 14. Kalpana T. A study of the nutrient foramina in dry human tibia bones of telangana region, International Journal of Anatomy and Research, [online] 2017; 5(3.1): 4152-57.
 15. Gupta RK, Kumari GA. A study of diaphyseal nutrient foramina in human tibia, National journal of medical research, [online] 4, 310.