

Case Reports

Hereditary Spastic Paraplegia-Report of 2 Cases in a Family

KANIJ FATEMA¹, MIZANUR RAHMAN², SHAHEEN AKHTER³, TAHMINA KARIM⁴

Introduction:

Hereditary spastic paraplegia (HSP) also called Familial spastic Paraplegia or Strumpell- Lorrain disease is a heterogeneous group of inherited disorders¹ in which the main feature is progressive spasticity in the lower limbs due to pyramidal tract dysfunction². The prevalence range from 3 to 10 cases per 100,000 populations in Europe.³

HSP was first described in 1883 by Adolph Strumpell, a German neurologist, and was later described more extensively in 1888 by Maurice Lorrain, a French physician.⁴ It is diagnosed using the criteria proposed by Fink JK et al (1996) as 1) all alternative disorders have been excluded 2) the family history supports an inherited disorder 3) subject reports a progressive disturbance and 4) neurological examination shows a frank corticospinal tract deficit in the lower limbs, including grade 4 hyperreflexia and extensor planter responses.⁵

Conventionally HSP are divided into two clinical groups, uncomplicated HSP (Pure spastic paraplegia) or complicated HSP depending on the presence of other neurological features in addition to spastic paraparesis. The age of onset can be from infancy to the eighth decade with a marked interfamilial variation due to genetic heterogeneity in this condition.⁶

Inheritance may be autosomal dominant, autosomal recessive or rarely X linked, but autosomal dominant inheritance is most commonly associated with pure forms of the disease, whereas autosomal recessive HSP shows greater phenotypic variability, including several well defined syndromes.⁷ To our knowledge no HSP case has been reported in Bangladesh in biomedical journals. So, we are reporting the cases.

Case Report:

Two brothers presented with similar type of disease process. The elder brother, a 6 year old male child presented in paediatric neurology outdoor,

Bangabandhu Sheikh Mujib Medical University with progressive spastic paraplegia for evaluation. On enquiry he started to sit on 6 months of age and learned to walk at 18 months of age. While started walking the parents noticed frequent fall during walking. Then gradually he developed gait difficulty and spasticity of both lower limbs. He was born of consanguineous marriage and the delivery was full term and vaginal without any neonatal hypoxia or jaundice. There were no unusual problems in his perinatal period and he experienced no serious illnesses or injuries in his childhood. On query, the patient's brother is also affected with same kind of illness.

On examination, speech was normal but he lacked spontaneity. His height and weight was within normal limit. Examination of the lower extremity showed a bilateral equinovarus deformity, paraparesis, spasticity, hyperreflexia (4+ DTR) of both ankles,



Fig.-1: Two brothers with HSP

1. Assistant Professor, Pediatric Neurology, BSMMU.
2. Professor and Head, Pediatric Neurology, BSMMU.
3. Professor, Pediatric Neurology, BSMMU.
4. Pediatrician, BSMMU

Correspondence: Dr Kanij Fatema

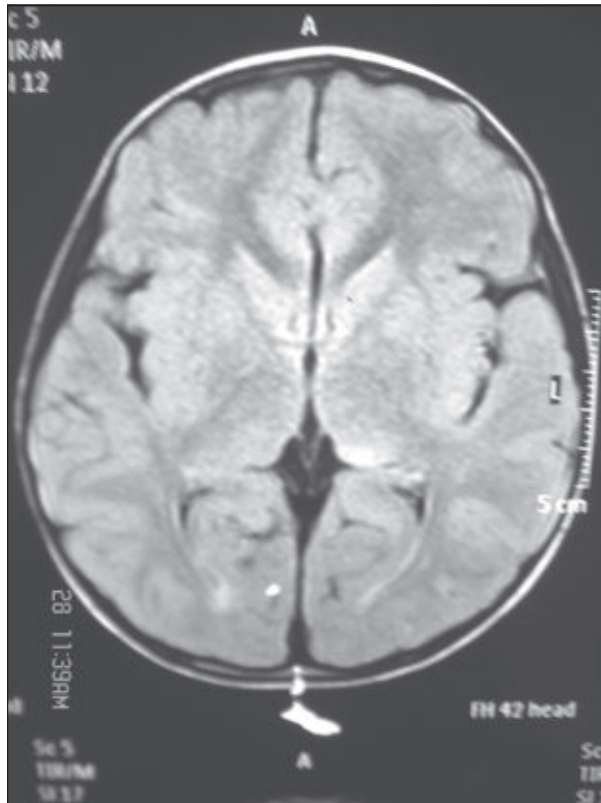


Fig.-2: Normal MRI of brain of the first case

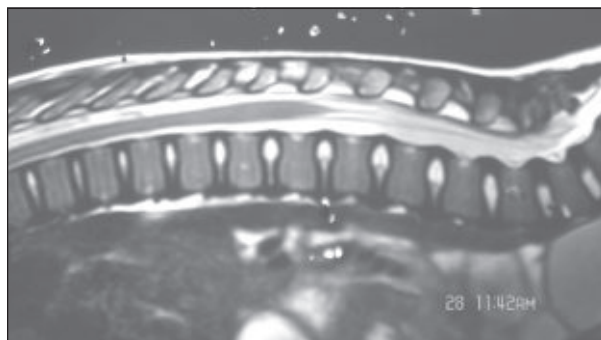


Fig.-3: Normal MRI of spine of the first case

extensor planter responses and positive Babinski, vibration and joint position sensation was normal. There was no fasciculation or involvement of upper extremities and bulbar muscles. His cognition was normal. Hypertonic urinary disturbance with inability to completely empty the bladder was noted. He was unable to walk without support from a care given. Laboratory investigations revealed normal complete blood count, X- ray spine, X-ray chest, X-ray pelvis. Magnetic Resonance Imaging (MRI) brain and spine was normal except there was maxillary sinusitis.

Our second case, a 5 year old male child who is the brother of the first case was referred with the same

problems of his brother. He was delivered by normal vaginal delivery at home with no antenatal and postnatal insult. His development was normal up to 18 months when he started to walk. Then he started to fall frequently while walking and gradually developed spasticity and balance difficulty by the age of two year.

Physical examination revealed bilateral equinovarus deformity and pes cavus. On neurological evaluation, he had spasticity and hyperreflexia of the lower limbs with extensor planter responses and no sensory deficits. On psychological evaluation no cognitive decline was revealed. He also complained of inability to completely evacuate bladder. All his investigations came normal except maxillary sinusitis in the CT scan of Brain.

Both brothers had been clinically diagnosed as having Hereditary Spastic Paraplegia with normal birth history, similar developmental history, clinical manifestation and investigation findings. As there is consanguinity of the parents is present most likely it is the autosomal recessive form of the disease. Due to unavailability of the genetic study and cost perspective, genetic study could not be performed in this case.

Discussion:

HSP describes a heterogeneous group of genetic neurodegenerative disorder in which the most severely affected neurons are those of spinal cord. The key diagnostic clinical findings are of lower limb spasticity and pyramidal weakness with heperreflexia and extensor planter responses.⁸ The genetics of HSP are complex and all modes of inheritance that is Autosomal dominant, Autosomal recessive and X linked recessive have been described.¹

In pure HSP the patients present lower limb spaticity, particularly in the hamstrings and quadriceps , muscle weakness in iliopsoas and tibialis anterior, walking difficulty or gait disturbances, stiffness of legs, mild sensory abnormality in the lower limbs, pes cavus and urinary sphincter disturbances.⁹

Here we are describing these reports, the two boys presented with similar clinical features and developmental features. Both of them presented with progressive gait disorder, spasticity of lower limbs, equinovarus deformity, hyperreflexia and extensor planter responses. They also have hypertonic urinary disturbances with inability to evacuate urinary bladder which suggest spinal cord involvement which is a feature of HSP. Cognition is normal which suggests

pure form of HSP. As particular of these cases, both the brothers had maxillary sinusitis which may be co-morbid condition. As there is consanguinity of parents it is most likely of autosomal recessive condition but due to unavailability of genetic finding this can not be confirmed. Almost all the investigation came normal which excludes other differential diagnosis such as amyotrophic lateral sclerosis (ALS), multiple sclerosis, Friedreich ataxia etc.

Complicated HSP comprises a large number of condition in which spastic paraplegia is accompanied by other features such as ataxia, severe amyotrophy, optic atrophy, pigmentary retinopathy, mental retardation, extrapyramidal signs, dementia, deafness, peripheral neuropathy, epilepsy etc.^{10,11}

There is no specific treatment to prevent, slow or reverse HSP. Treatment of HSP mainly consists of symptomatic medical management to promote physical and emotional well being. Some of the treatment options include: Beclofen to reduce tone, Tizanidine to treat nocturnal or intermittent spasm, Diazepam and Clonazepam to decrease intensity of spasm, Botulinum toxin to reduce muscle overactivity. Physical therapy is required to restore and maintain the ability to move; to reduce muscle tone and to maintain or improve range of motion and mobility.¹²

Although HSP is a progressive condition and usually starts in the legs and spreads to other muscles ultimately leading to confinement to bed, the prognosis for individuals with HSP varies greatly.¹³ Some cases are seriously disabling while others are less disabling and are compatible with productive and full life. The majority of individuals with HSP have a normal life expectancy.²

Conclusion:

In conclusion it can be stated that HSP must be considered as a differential diagnosis with a patient with lower limb spasticity, positive family history and progressive gait disturbances. Fairly good number of HSP has been reported by authors from different parts of the world. So the clinicians' awareness of this rare disorder may prevent misdiagnosis, unnecessary evaluation and inappropriate treatment.

References:

1. Fink JK. The Hereditary Spastic Paraplegia: nine genes and counting. *Arch Neurol* 2003; 60: 1045-9.
2. Depienne C, Stevanin G, Brice A, Durr A. The Hereditary Spastic Paraplegia: an update. *Current opinion in Neurology* 2007; 20:674-80.
3. Selinas S, Crosby AH, Proukakis C. Hereditary Spastic Paraplegia: Clinical feature and Pathogenic mechanism. *The Lancet Neurology* 2008; 12:1127-38.
4. Peter F. Hereditary Spastic Paraplegia. *J Neurol Neurosurg Psychiatr* 1963; 26: 516-9.
5. Behan W, Maia M. Strumpells Familial Spastic Paraplegia: genetics and neuropathology. *J Neurol Neurosurg Psychiatry* 1974; 37:8-20.
6. Harding AE. Classification of hereditary ataxias and paraplegias. *Lancet* 1983; 8334: 1151-5.
7. Crosby AH, Proukakis C. Is the transportation highway the right road for the hereditary spastic paraplegia? *Am J Hum Genet* 2002; 71:1009-16.
8. Soderblom C, Blackstone C. Traffic accidents; molecular genetic insights into the pathogenesis of hereditary spastic paraplegia. *Pharmacol Ther* 2006; 10(9): 42-56.
9. Mcdermott C, White K, Bushby K, Shaw P. Hereditary Spastic Paraperesis: a review of new developments. *J Neurol Neurosurg Psychiatr* 2000; 69:150-60.
10. Harding AE. Hereditary Spastic Paraplegias. *Semin Neurol* 1993; 13:333-6.
11. Schwarz GA, Liu CN. Hereditary Spastic Paraplegia- Further clinical and pathological observation. *AMA Arch Neurol Psychiatry* 1956; 75:144-62.
12. Durr A, Brice A, Serdaru M. The phenotype of pure autosomal dominant spastic paraplegia. *Neurology* 1994; 44: 1274-7.
13. Eugenia R, Cosmina S, Elena B. Hereditary Spastic Paraplegia. *Romanian Journal of Morphology and Embryology* 2009; 50: 299-303.