

## Case Reports

### Xeroderma Pigmentosum – A Social Stigma Report in Two Siblings and Literature Review

TUSHAR JAGZAPE<sup>1</sup>, ARUNITA BAGGA<sup>2</sup>, AMOL GUPTA<sup>3</sup>, DAMODHAR BALPANDE<sup>4</sup>

#### Introduction :

Xeroderma pigmentosum is an autosomal recessive, rare pigmentary atrophic disease of childhood that progresses to early development of senile changes in sun-exposed skin.<sup>1</sup>

Xeroderma pigmentosum (XP) was first described in 1874 by Hebra and Kaposi.<sup>2</sup> In 1882, Kaposi coined the term xeroderma pigmentosum for the condition, referring to its characteristic dry, pigmented skin. Xeroderma pigmentosum is also known as DeSanctis-Cacchione syndrome.

#### Case report:

X, 4 and ½ year male child born of a consanguineous marriage at term with weight of 2.5 kg was brought with chief complaint of erythematous macular rash all over the body beginning from 2 months of life, global developmental delay and rapidly progressive, painless swelling with foul smelling discharge over right cheek just below the right eye since last 2 months. Initially the rash was on exposed part of the body but since last 6 months it was present all over. No history of trauma or similar swelling elsewhere or of convulsions. History of photophobia and similar complaints in younger sibling 2 ½ year of age since 4 months of life. Two elder female siblings were normal.

On examination the child was malnourished with weight for age 40% of the expected. Vitals were stable. There were macular corneal opacities and conjunctival nevi in both eyes. The child was hypotonic with diminished reflexes and bilateral sensory neural hearing loss. Other systemic examination was normal.

There was hyperpigmentation all over the body mostly over exposed areas. Fungating mass of around 8cm diameter present over the right cheek, just below the eye, free from the underlying bone. The clinical

impression was XP with ? squamous cell carcinoma. ?? Multiple lentiginos syndrome with soft tissue tumor.

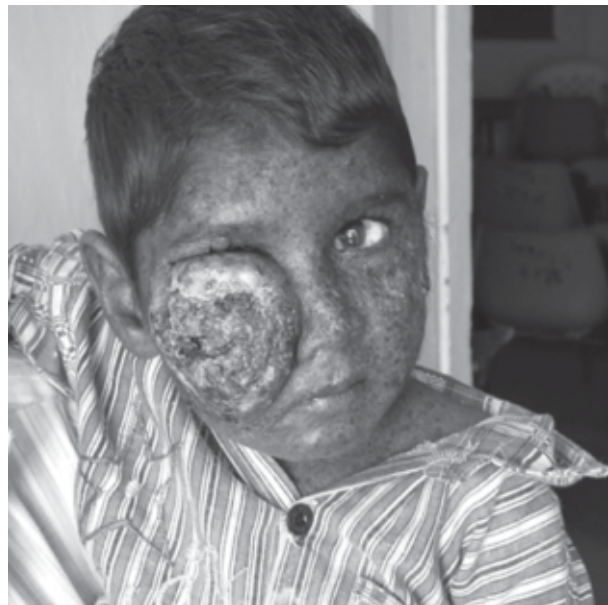

Fig.-1: showing the fungating mass below the right eye.

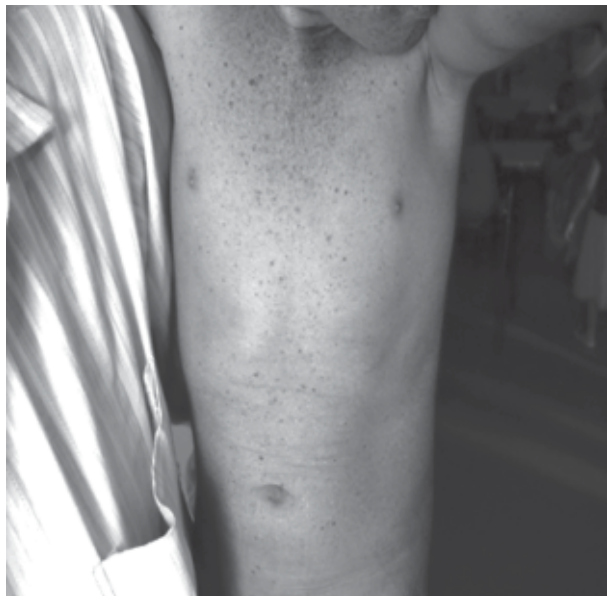
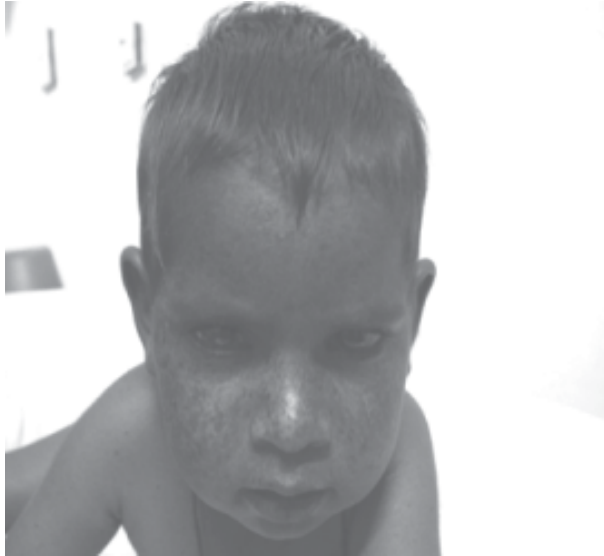
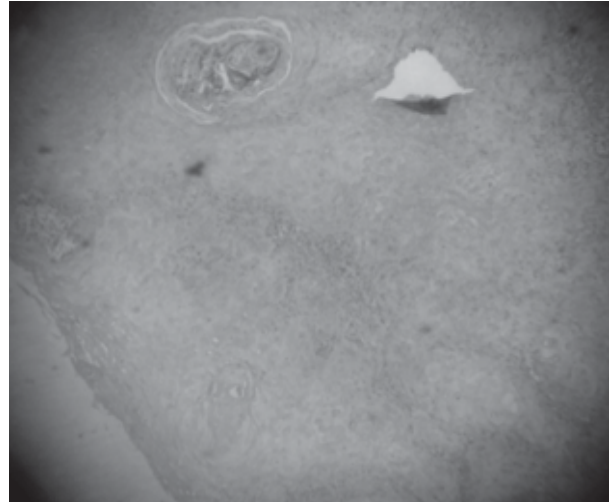
Fig.-2: Multiple hyperpigmented lesions all over the body, more on the exposed parts.

1. Associate Professor, Department of Pediatrics, J.N.Medical College, Sawangi(M), Wardha
2. Assistant professor (Physiology)
3. Resident
4. Professor and unit incharge

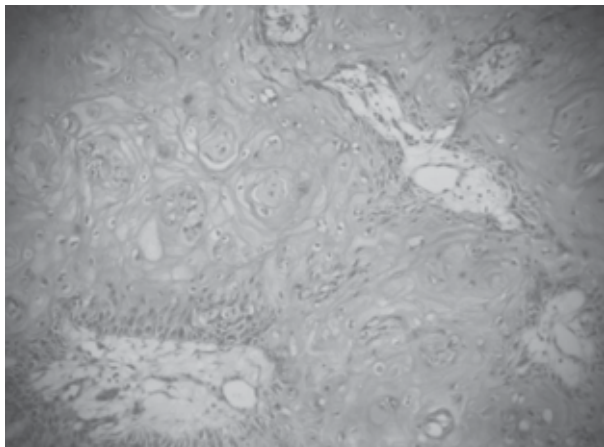
**Correspondence:** Dr. Tushar Jagzape, c/o H.O.D. Department of Pediatrics, J.N.Medical College, Sawangi(M) Wardha, Cell no – 09421783796, Email – tusharjagzape@yahoo.com



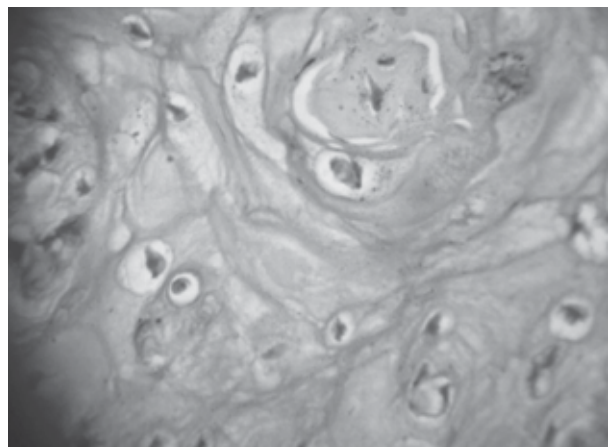
**Fig.-3:** Younger sibling of the patient with typical facial lentigos and ocular changes



**Fig.-4:** 4x scanner view, showing squamous cell carcinoma with multiple squamous epithelial pearls within the dermis (H&E stain)



**Fig.-5:** Multiple malignant epithelial pearls (hollow arrow) with malignant cells and mitotic figures (black arrow) (10x H&E stain)



**Fig.-6:** Same as in figure 5 (40x H& E stain)

**Discussion:**

The basic defect underlying the clinical manifestations is a nucleotide excision repair (NER) defect leading to the defective repair of DNA damaged by ultraviolet (UV) radiation.<sup>2</sup> NER involves removal and the replacement of damaged DNA with new DNA. Two types of NER exist: global genome NER (GG-NER) and transcription-coupled NER (TC-NER). In addition the immunosuppressive effects of UV-B radiation may also be involved in the pathogenesis of XP. These patients exhibit enhanced sensitivity to ionizing radiation.<sup>1</sup>

The estimated frequency in United States is 1:25000 and somewhat more in Japan. Its incidence in the

Indian context is not significant.<sup>3</sup> Both sexes are equally affected. Consanguinity between parents of affected children has been found in 30% of cases<sup>4</sup> In our case it was a consanguineous marriage and only males were affected. The females were normal. Ahmed H et al has reported a case of XP in three consecutive siblings of a Nigerian family where both male and female were affected.<sup>5</sup>

Bradford et al has reported that the diagnosis can be made in the first year of life. In their study, 60 % of affected children demonstrated acute sun sensitivity and the remaining affected children did not burn easily but developed marked freckle like pigmentation. These unusual freckles, when present on the face before

age two years, are typical of XP and rarely seen in children with normal DNA repair mechanisms.<sup>6</sup> Our patients started developing skin rash before 6 months of age.

Both of our patients had photophobia, macular corneal opacities and conjunctival naevus. Dollfus et al has described that the ophthalmologic abnormalities are usually limited to the anterior, UV- exposed portion of the eyes: conjunctiva, cornea and lids.<sup>7</sup> Gupta et al in their series of 7 patients with XP found dry eye in 100 % and conjunctival melanosis in 50% cases.<sup>8</sup>

Our patients had global developmental delay. Gross motor age was around 12 months and social was around 6-7 months. They had microcephaly, diminished reflexes and hypotonia, sensorineural hearing loss. Albert Neisser first described neurologic abnormalities associated with XP in 1883. De Sanctis and Cacchione described 3 brothers with XP who had mental retardation , dwarfism, and gonadal hypoplasia.<sup>9</sup> Subsequently, some authors referred to XP associated with CNS abnormalities as De Sanctis-Cacchione syndrome. Kraemer et al in his review of 830 patients observed neurologic abnormalities in 18 % patient which were mental retardation (80%), spasticity or ataxia(30%) and microcephaly (24%) in decreasing order of frequency.<sup>10</sup>

Patients with XP have 1000 times more risk of developing skin cancer than that of the general population. Basal cell cancer (BCC) and squamous cell carcinoma(SCC) are the most common, with most tumours found on the face, head or neck. Alymlahi et al has reported a case of bilateral SCC in a 18 month old girl with XP.<sup>4</sup> Mohanty et al and Grampurohit et al both have reported two cases with multiple cutaneous malignancies in 18 year old male patient.<sup>1,3</sup> The median age of onset of non-melanoma skin cancers reported in patients with XP is 8 years, compared to 60 years in the healthy population.<sup>1</sup> Our patient had SCC of the right cheek. Metastatic SCC is one of the important cause of mortality in these patients. Most patients do not live beyond the third decade because of the development of tumors.<sup>4</sup> Its difficult to prevent these malignancies but the patient should adopt to a life style to minimize UV exposure by wearing protective clothing, UV absorbing glasses and long hair styles, in order to reduce their incidence.<sup>3</sup> Early diagnosis and treatment of SCC is important for better outcome. Surgical excision is the treatment of choice. Schaffer JV et al have reported use of radiation therapy for high risk SCC in patient with XP.<sup>11</sup>

Premalignant skin lesions may be treated with cryosurgery or topical antimitotic agents. Early removal of neoplasms should be accomplished with excision, chemosurgery or intralesional IFN- $\alpha$ . In selected patients, oral isotretinoin has been shown to significantly reduce the incidence of skin cancers.<sup>12</sup>

The bacterial DNA repair enzyme T4 endonuclease V in a topical liposome-containing preparation has been reported to reduce the frequency of new actinic keratoses and BCC in individuals with XP in one research study by Yarosh et al.<sup>13</sup>

More important is the Psychological and social support to the patient and family. Because of the awful appearance people are scared of these patients. In our case when this patient was admitted in the ward all other patients wanted to be shifted away. People should be made aware that this is not a infectious or contagious disease and genetic counseling should be provide to avoid consanguineous marriages.

#### References :

1. Grampurohit VU, Dinesh US, Rao R. Multiple cutaneous malignancies in a patient of xeroderma pigmentosum. J Can Res Ther 2011;7:205-7
2. Cleaver JE. Defective repair replication of DNA in xeroderma pigmentosum. Nature 1968;218:652-6.
3. Mohanty P, Mohanty L, Devi BP. Multiple cutaneous malignancies in xeroderma pigmentosum. Indian J Dermatol Venereol Leprol 2001;67:96-7.
4. Alymlahi E, Dafiri R. Bilateral facial squamous cell carcinoma in an 18-month-old girl with xeroderma pigmentosum. J Postgrad Med 2005;51:128-30.
5. Ahmed H, Hassan RY, Pindiga U. Xeroderma pigmentosum in three consecutive siblings of a Nigerian family: observations on oculocutaneous manifestations in black African children. Br J Ophthalmol 2001;85: 110.
6. Bradford PT, Goldstein AM, Tamura D, Khan SG, Ueda T, Boyle J, Oh KS, Imoto K, Inui H, Moriwaki S, Emmert S, Pike KM, Raziuddin A, Plona TM, DiGiovanna JJ, Tucker MA, Kraemer KH. Cancer and neurologic degeneration in xeroderma pigmentosum: long term follow-up characterises the role of DNA repair. J Med Genet. 2011;48:168-76.

7. Dollfus H, Porto F, Caussade P, Speeg-Schatz C, Sahel J, Grosshans E, Flament J, Sarasin A. Ocular manifestations in the inherited DNA repair disorders. *Surv Ophthalmol.* 2003;48:107-22.
8. Gupta N, Sachdev R, Tandon R. Ocular surface squamous neoplasia in xeroderma pigmentosum: clinical spectrum and outcome. *Graefes Arch Clin Exp Ophthalmol.* 2011; 249(8): 1217-21.
9. De Sanctinis C, Cacchione A. L'idiozia xerodermica. *Riv Sepr Freniatr.* 1932;56:269-92
10. Kraemer KH, Lee MM, Scotto J. Xeroderma pigmentosum. Cutaneous, ocular, and neurologic abnormalities in 830 published cases. *Arch Dermatol.* Feb 1987;123:241-50.
11. Schaffer JV, Orlov SJ. Radiation Therapy for High-Risk Squamous Cell Carcinomas in Patients with Xeroderma Pigmentosum: Report of Two Cases and Review of the Literature. *Dermatology.* 2011.
12. DiGiavanna JJ. Retinoid chemoprevention in patients at high risk for skin cancer. *Med Pediatr Oncol* 2001;36:564-7.
13. Yarosh D, Klein J, O'Connor A, Hawk J, Rafal E, Wolf P. Effect of topically applied T4 endonuclease V in liposomes on skin cancer in xeroderma pigmentosum: a randomised study. *Xeroderma Pigmentosum Study Group. Lancet.* 2001;357:926-9.