

Spectrum of Hepatic Presentation of Wilson's Disease in Children Attending A Tertiary Care Centre of Dhaka City

FARHANA BAYES¹, ASM BAZLUL KARIM², LAILA HELALY³, FAHMIDA BAYES⁴, MD.
RUKUNUZZAMAN⁵, SANJIDA AHMED⁶, SYEDATABASSUM ALAM⁷

Abstract

Background: The incidence of Wilson's disease (WD) is increasing day by day in every ethnic group worldwide. WD has been found as a common cause of chronic liver disease in children. This study was undertaken to find out the occurrence and different types of hepatic presentation of Wilson's disease in children admitted with liver diseases at a tertiary care centre of Bangladesh.

Methodology: This cross sectional descriptive study was carried out at the department of Paediatric Gastroenterology and Nutrition, BSMMU during the period from March 2008 through April 2010. A total number of 71 children of both sexes aged 3-15 years, who had the features of liver disease (jaundice with or without hepatomegaly/splenomegaly and/or raised serum ALT), were enrolled in this study. For the purpose of the study, the diagnosis of WD was made by the presence of any 2 of the 3 features: presence of K-F ring by slit lamp examination, low serum ceruloplasmin level (<20 mg/dL) and urinary copper excretion of >1600 µgm /24 hours after penicillamine challenge.

Results: Wilson's disease was found in 31 (43.7%) of 71 children. Among them chronic liver diseases were 18 (58%), acute hepatitis 6 (19.4%), acute liver failure 6 (19.4%) and asymptomatic WD case was 1 (3.2%). The mean age \pm SD of WD cases at presentation was 9.87 ± 2.6 years and 22 (70%) cases were male. Maximum numbers of WD cases were found in children below 10 year of age. The two common presenting features of WD cases were jaundice 28 (90.3%) and ascitis (58.1%). Other features were K-F ring, 25 (80.6%) and hepatomegaly, 24 (77.4%). Biochemical findings showed low serum ceruloplasmin level (done in 20 patients) in 20 cases and 24 hours urinary copper excretion of >1600 mg/day in 23 cases. About one third of children presented with liver diseases were diagnosed as Wilson's disease and about 50% of WD cases presented with chronic liver diseases.

Conclusion: Wilson's disease is a common cause of chronic liver disease. Penicillamine challenge is a reliable diagnostic test for Wilson's disease.

Keywords: Children, Hepatic presentation, Wilson's disease

1. Medical Officer, Department of Paediatric Gastroenterology and Nutrition, Bangabandhu Sheikh Mujib Medical University (BSMMU)
2. Professor, Department of Paediatric Gastroenterology and Nutrition, BSMMU
3. Consultant, Bangladesh Thalassaemia Hospital
4. OSD, DG Health Mohakhali, Dhaka
5. Associate Professor, Department of Paediatric Gastroenterology and Nutrition, BSMMU
6. Medical Officer, Paediatric Neurology Unit, Department of Paediatrics, BSMMU
7. Associate Professor, Paediatric Neurology Unit, Department of Paediatrics, BSMMU

Correspondence: Dr. Farhana Bayes, Department of Paediatric Gastroenterology and Nutrition, Bangabandhu Sheikh Mujib Medical University, Dhaka, Email: farhanabayes_74@yahoo.com

Introduction

Wilson's disease (WD) in early childhood commonly presents with liver diseases¹. It includes different forms of parenchymal liver disease, ranging from mild acute hepatitis to fulminant hepatic failure or cirrhosis. Some authors found WD as a common cause of chronic liver disease in children². It is also reported that in India WD has become an important cause of liver disease in different age groups³. In developed countries non viral causes are frequently overlooked in children attending hospitals with various forms of liver diseases⁴. After several studies, researchers have recommended that WD should be considered as one

of the differential diagnosis in these cases as the incidence is increasing day by day⁵. WD is observed in every ethnic group worldwide with a frequency of 1 in 30,000 people and a carrier rate of 1 in 90^{6,7}.

Wilson's disease is a relatively rare inherited disorder of copper metabolism where there is a defect in an enzyme in the pathway of biliary excretion of copper, resulting in copper accumulation in the liver and toxicity^{8, 9}. The common presentations of WD are hepatic, neuropsychiatry or both. The hepatic presentations of WD appear early in life compared to the neurological presentations¹⁰. As the capacity of the liver to store excess copper delays the appearance of symptoms before the age of 3 years¹¹.

Diagnosis of hepatic presentation of WD is based on clinical suspicion and few supporting investigations like serum ceruloplasmin level (<20 mg/dl), hepatic copper (>250mg/g dry weight) estimation, presence of KF ring and high urinary copper (>1600 mgm/day) excretion after penicillamine challenge¹².

In Bangladesh, to the best of knowledge, study on WD in large scale had not been done so far. Data on clinical, biochemical, hematological and serological profile of WD in Bangladeshi children is not optimum. Therefore this study was undertaken to find out the various hepatic presentations of WD in Bangladeshi children suffering from liver diseases and to observe the diagnostic value of different biochemical, haematological and serological tests that are currently available.

Methodology

It was a cross sectional descriptive study. A total of 71 consecutive patients of 3-15 years of age with liver diseases who got admitted at Dept of Paediatric Gastroenterology and Nutrition, Bangabandhu Sheikh Mujib Medical University, Dhaka between March 2008 through April 2010 were taken for the purpose of the study. Very sick children were excluded from the study.

Clinically a child presented with jaundice with or without hepatomegaly/ splenomegaly along with biochemical evidence of liver disease (increased serum ALT) at inpatient department of paediatric Gastroenterology and Nutrition, was selected for the study. After taking written consent from the parents, a preset data sheet was filled up by the researcher herself. A detailed history of the duration of jaundice, ascites, generalized weakness, right upper quadrant pain, h/o taking any offending drugs, family history of

consanguinity, family history of jaundice, history of death of any family member from liver diseases, family history of Wilson's disease, history of immunization against HBV were taken by the investigator. Physical examinations were done to find out the stigmata of the chronic liver disease (spider angioma, palmer erythema, wasting of thenar and hypothenar muscles), features of acute liver injury (tender hepatomegaly with impaired liver function test) and other signs were looked for systematically. The eye was examined by slit lamp for K-F ring by a single ophthalmologist at BSMMU. Then blood was collected by the researcher and necessary investigations such as liver function tests (serum ALT, serum bilirubin, prothrombin time and serum albumin), complete blood count with peripheral blood film (PBF) etc were done. For the diagnosis of WD serum ceruloplasmin and 24 hours urinary copper estimation after penicillamine challenge were done. Asymptomatic Wilson's disease was diagnosed by investigations but clinically asymptomatic.

Serum bilirubin was measured by colorimetric method. Serum ALT was measured by auto analyzer (Back man coulter auto analyzer, USA, model-5x). Serum albumin was measured by Bromocresol green, Colorimetric method using auto analyzer. In the hematology department of BSMMU estimation of CBC with PBF and the prothrombin time (PT) were done. Prothrombin time >3 sec of control was considered prolong. For 24 hours urinary copper estimation after penicillamine challenge, orally Penicillamine 500 mg (2 tablets of 250 mg) was given twice. First at the beginning of urine collection and second dose 12 hrs after the first dose. Then urine was collected for 24 hrs and sample was sent to Atomic Energy Commission for the test. It was done by "Atomic absorption spectrophotometer" (normal range: <60 µgm / day).

As serum ceruloplasmin and 24 hours urinary copper estimation are not available at BSMMU, these two tests were done from outside laboratory (Lab aid diagnostic centre and Atomic energy centre).

Results

In this cross sectional descriptive study, a total of 71 patients of liver diseases were enrolled. Out of seventy one patients 31 (43.7 %) had WD and 40 (56.3 %) were other than WD. This study showed that most (54.8%) of the patients with different hepatic presentation WD were found in the age range of seven

to ten years. The next common age group was eleven to fourteen years and total 9 (29%) patients were in this age group (Table-I). In this study most of the patients 23 (74.1%) did not give any history of consanguinity of marriage. Out of thirty one WD cases, majority were male 22 (71%). The male and female ratio was 2.4: 1 (Figure 1). The commonest presentation were chronic liver disease, (58%) and acute hepatitis, 6 (19.4%). One patient was diagnosed as asymptomatic WD during family screening (Table 2). Common presenting symptoms were jaundice (90.3%), ascitis (58.1%), right upper quadrant pain (29 %), muscle weakness (22.6%), weight loss (19.4%) (Table 3), etc. It was observed that jaundice (90.3%) was the commonest presenting sign. Others were K-F ring (80.6%), hepatomegaly (77.4%), ascites (58.1%) etc. Spleen was found palpable in 12 (38.7%) cases (Table IV). Twelve (38.7%) patients with WD had history of any kind of liver diseases among family members. There were 11 (35.5%) cases that had history of death of a family member from liver disease. The mean \pm SD value of 24 hrs urinary copper excretion (after penicillamine challenge) was 2018.62 ± 886.28 mg/day. This test was done in all WD cases. In WD the mean \pm SD value of serum ALT was 101.52 ± 65.61 U/L. The mean \pm SD value of serum ceruloplasmin was 13.09 ± 4.87 mg/dL. The mean \pm SD value of serum bilirubin was 3.25 ± 1.57 mg/dL and the mean \pm SD value of serum albumin was 26.13 ± 10.50 g/L (Table V). The mean \pm SD value of hemoglobin (Hb) was 9.5 ± 1.16 gm/dL. The mean \pm SD value of prothrombin time (Sec) of studied patients was 17.96 ± 5.12 sec. Sensitivity and specificity of urinary copper excretion of $> 1600 \mu\text{gm} / 24$ hours after penicillamine challenge is 100%. The positive predictive value is 100. In case of detection of disease negative cases this test result is also 100% reliable (Table-VI).

Receiver-operating characteristic (ROC) curve for the analysis of prothombin time is 100%. Receiver-operating characteristic (ROC) curve for the analysis of serum ALT shows sensitivity and specificity of 100%.

Table I
Age distribution of the patients (n=31)

Age in years	No. of patients	Percent
3 - 6	2	6.4
7 - 10	17	54.8
11 - 14	9	29.0
> 14	3	9.6

Spectrum of Hepatic Presentation of Wilson's Disease

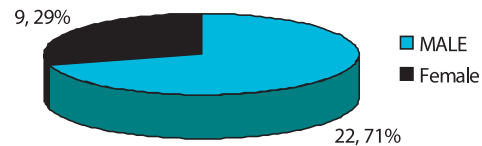


Fig.-1: Sex distribution of the studied patients (n=31)

Table II
Different hepatic presentations of WD (n=31)

Hepatic presentations of WD	No	Percent
Chronic liver disease (CLD)	18	58.0
Acute hepatitis	6	19.4
Acute liver failure	6	19.4
Asymptomatic WD	1	3.2

Table III
Presenting symptoms of the studied cases (n=31)

Symptoms	No. of patients	Percent
Yellow coloration of sclera	28	90.3
Yellow coloration of skin	19	61.3
Yellow coloration of urine	19	61.3
Gradual distention of abdomen	18	58.1
Right upper quadrant pain	9	29.0
Muscle weakness	7	22.6
Fatigue	7	22.6
Weight loss	6	19.4
Malaise	3	9.7

Table IV
Presenting signs of the studied cases (n=31)

Signs	No. of patients	Percent
Jaundice	28	90.3
K-F ring	25	80.6
Enlarged liver	24	77.4
Ascites	18	58.1
Oedema	11	35.5
Splenomegaly	12	38.7
Wasting of thenar and hypothenar muscle	9	29
Palmar erythema	7	22.6
Clubbing	6	19.4
Esophageal varices	5	16.1
Muscle wasting	5	16.1
Sunflower cataract	4	12.9
Leuconychia	2	6.5
Gynaecomasia	1	3.2

Table V
Biochemical and serological parameters of the studied patients (n=31)

Biochemical parameters	Mean ± SD	Range
24 hrs urinary copper (penicillamine challenge test) estimation (µg/day)	2018.62 ± 886.28	300-3500
Serum ALT (U/L)	101.52 ± 65.61	20-239
• Serum albumin (g/L)	26.13 ± 10.50	6-45
• Serum ceruloplasmin (mg/dl)	13.09 ± 4.87 *	4.8-25
• Serum bilirubin (mg/dl)	3.25 ± 1.57	0.16-6

* Done in 20 cases

Table VI
Receiver-operating characteristic (ROC) curve for the analysis of 24 hrs urinary copper estimation (penicillamine challenge test)

Criterion	Sensitivity	95% CI	S specificity	95% CI	Positive Predictive value	95% CI	Negative Predictive value	95% CI
>1557	100	85.2-100	100	73.5-100	100	85.2-100	100	73.5-100

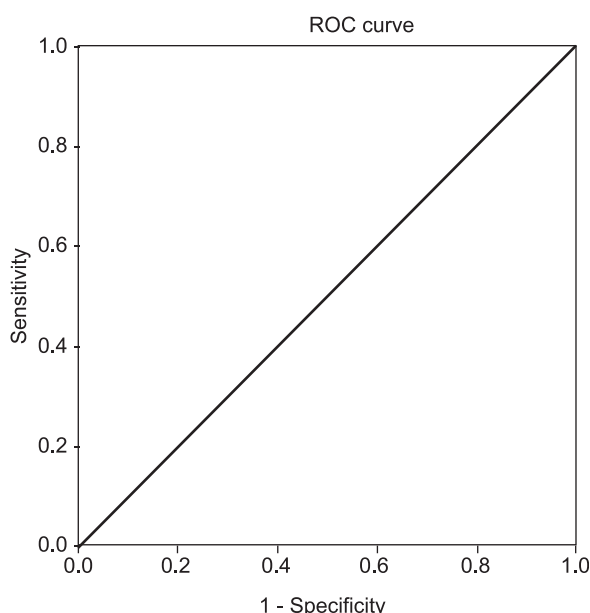


Fig.-2 : Receiver-operating characteristic (ROC) curve for the analysis of 24 hrs urinary copper estimation (penicillamine challenge test)

Discussion

Liver disease is a common medical problem in Bangladesh. Wilson’s disease with hepatic presentation is found more frequently in children than in older patients¹³. Wilson’s disease is an autosomal recessive disorder of copper metabolism with a

prevalence of 1 in 30,000 in the general population¹⁴. With the availability of diagnostic facilities more and more cases of WD are diagnosed now a days. The incidence and prevalence of WD is also increasing day by day⁵. The clinical manifestations are secondary to accumulation of copper in various organs, the most common presentations being hepatic or neuropsychiatry. In children, the disease usually presents after 3 years of aged¹⁵. Renal disturbances are extremely rare in patients with Wilson’s disease¹⁶.

In this study 71 children aged between 3-15 years with liver diseases were investigated to see the occurrence of WD among them. It has been found that a combination of a different clinical and biochemical tests are required for the right diagnosis of Wilson’s disease in patient with liver disease. In hepatic cases, diagnosis of WD is more difficult. Single commonly used parameter is not sufficient to detect WD. K-F ring may be absent in 50% of patients of Wilsonian liver disease. Serum ceruloplasmin may be low in 45% of patients with hepatic disease⁴. A low serum ceruloplasmin level is not diagnostic for WD in absence of K-F ring. Urine copper excretion is markedly increased in patients with WD. But its usefulness in clinical practice is limited. Liver biopsy findings are generally nonspecific and not directly helpful to make the diagnosis of WD. Hepatic copper content is increased in 82% of patients with WD,

although liver copper content is a useful parameter, it neither proves nor excludes WD. Usually a combination of various biochemical parameters are needed to establish the diagnosis of WD¹⁷.

WD was diagnosed by clinical suspicion along with the presence of any two of the criteria like K-F ring (by slit lamp examination), low serum ceruloplasmin (<20 mg/dl) level and high urinary copper excretion of >1600 µgm / 24 hours after penicillamine challenge.

In this study out of seventy one children with liver disease, 31 patients (43.7 %) had WD and 40 (56.3 %) were other than WD. Out of 31 studied patients, K-F ring and low serum ceruloplasmin were found in 14 patients, K-F ring and urinary copper excretion of >1600 µgm/24 hours after penicillamine challenge were found in 17 patients, low serum ceruloplasmin and urinary copper excretion of > 1600 µgm/24 hours after penicillamine challenge were found in 10 patients. Serum ceruloplasmin, urinary copper excretion of >1600 µgm/24 hours after penicillamine challenge and K-F ring were found in 7 patients.

Most of the WD cases (54.8%) were found below ten years of age. The youngest patient presented with WD was a five year old girl. Similar result was also observed in a study done in Bangladesh¹⁸. In that study 32 patients with WD were studied and the mean±SD value of age was found to be 9±2.97 years and the youngest age at presentation was a boy of 3.5 year who was an asymptomatic case of WD and diagnosed during family screening. Hepatic presentations of WD in younger age group were also found in other study¹⁹. The youngest case of WD, so far diagnosed, was a boy of 3 year⁶.

In this study 71% WD cases were male. Male predominance in WD was also found in another study⁵. Eleven out of 16 patients were found to be male in that study. These male predominance may be due to the fact that male child are getting more attention than female child in the society.

In the present study eight (25.8%) patients had history of consanguinity of marriage. In another study it has been found consanguinity in 12.5% of studied population¹⁸.

Chronic liver disease, 18 (58%) was the commonest presentation of WD in the studied population. Other presentations were acute hepatitis, 6 (19.4%) and acute liver failure, 6 (19.4%). One patient with asymptomatic WD was diagnosed during family

screening. In a study of 55 cases of WD, seventeen patients of them were presented with various form of chronic liver diseases and five with fulminant hepatitis⁴. In another study of 6071 patients with liver diseases, sixteen were diagnosed as WD⁵. Clinical, biochemical, radiological and histopathological parameters of total 175 patients were evaluated for the etiology of chronic liver disease and WD was found as the etiological factor in 5 (2.8%) patients²⁰. A study was conducted at a tertiary care hospital in Bangladesh where clinical and common laboratory parameters were recorded from 32 Wilson's disease children with hepatic presentation. Out of 32 children studied, 21 (65.6%) presented with the features of chronic liver disease (CLD), 6 (18.8%) with fulminant hepatic failure (FHF), one with acute hepatitis and 4 (12.5%) with asymptomatic elevation of liver enzymes along with enlargement of liver and/or spleen¹⁸.

Yellow discoloration of sclera (90.3%) and gradual distention of abdomen (57.1%) were the two common presenting symptoms of the WD cases in this study. Other presenting symptoms were right upper quadrant pain (29%), muscle weakness (22.6%) and weight loss (19.4%). In this study jaundice (90.3%) and K-F ring (80.6%) were found to be the two common presenting signs. Other presenting signs of the WD cases found in the present study were hepatomegaly (77.4%), ascites (58.1%), sunflower cataract (12.9%) etc. Spleen was found palpable in 12 (38.7%) cases. K-F ring was also found to be a common presentation (40.90 %) in a study⁴. Another study found KF ring in 21 (65.6%) children and sunflower cataract in 4 children¹⁸.

It was observed that history of death of a family member from liver disease was present in 11 (35.5%) cases and history of liver diseases among family members was present in 12 (38.7%) cases. In one study it has been found family history of liver disease in 2 (6.25%) and history of sibling death from liver diseases in 5 (15.62%) cases¹⁸.

This study shows the importance of 24 hours urinary copper excretion after penicillamine challenge test. Twenty four hours urinary copper excretion after penicillamine challenge was found >1600 mg in 17 patients in this study. In this study sensitivity and specificity of urinary copper excretion of > 1600 µgm / 24 hours after penicillamine challenge is 100%. The positive predictive value is 100, which means it can detect true disease positive cases in 100%. In case

of detection of disease negative cases this test result is also 100% reliable. Urinary copper excretion of >100mg/day may be seen in patients receiving copper chelation therapy, in contamination of collection by exogenous copper, in chronic active hepatitis, in cholestatic cirrhosis, or in nephritic syndrome cases¹⁶.

But copper excretion after penicillamine administration of more than 1600mg/24 hours was regarded as diagnostic for Wilson's disease in paediatric group²¹.

In the studied WD patients the mean \pm SD of serum ALT was 101.52 \pm 65.61 U/L. The mean \pm SD serum albumin was 26.13 \pm 10.5 g/L. Hanif M et al. (2004) found forty nine patients with hypoalbuminemia (<2.5gm %) and 45 patients with raised ALT (>80 IU/L). In this study the mean \pm SD of serum ceruloplasmin was 13.09 \pm 4.87 mg/dl. In a patient with liver dysfunction, the finding of a plasma or serum ceruloplasmin level of less than 20 mg/ dl suggests the diagnosis of Wilson's disease; however, confirmatory studies are necessary because a number of diseases for example massive protein losing conditions like kwashiorkor, severe copper deficiency and severe hepatic insufficiency may also cause low ceruloplasmin level¹⁶. Other clinical conditions like hereditary hypoceruloplasminemia²², aceruloplasminemia²³, fulminant hepatitis, normal neonate; Menkes' syndrome; and in 20% cases of heterozygote for Wilson's disease^{4, 24, 22}, show low ceruloplasmin level. In this study the mean \pm SD of Hb was found to be 9.5 \pm 1.16 gm/dl. The mean \pm SD of prothrombin time of patients (Sec) was 17.96 \pm 5.12 sec. It was found that the mean Hb was low and prothombin time was prolonged in the studied cases. Another study found anaemia in 52 (94.54%) patients and prolonged PT (>4 sec of control) in 49 (89.09%) cases²⁵.

Conclusion:

It has been concluded from this study that features of chronic liver disease were the commonest manifestation of wilson disease in children. Urinary copper excretion, pnothrombin time & ALT could be the important laboratory tools for diagnosis of wilson disease and also to assess the severity.

References

1. Mowat AP. Wilson's disease. In: Liver disorder in childhood, 2nd edition. London: Butterworth company; 1987: 244- 55.
2. Brewer GJ. Yuzbasiyan-Gurkan.Wilson's disease: an update, with emphasis on new approaches to treatment. Dig. Dis1998; 7: 178-93.

3. Bhave SA, Bavdekar AR, Pandit AN. Changing patterns of chronic liver disease in India. Ind J Padiatr 1994; 61: 675 - 82.
4. Steindl P, Ferenci P, Dienes H P, Grimm G, Paringer I, Madl C et al . Wilson's disease in patients presenting with liver disease: A Diagnostic challenge. Gastroenterology 1997; 113: 212-218.
5. Kumagi T, Horiike N, Michitaka K, Hasebe A,Kawai K, Tokumoto Y et al. Recent clinical feature of Wilson's disease with hepatic presentation. J Gastroenterol 2004; 39: 1165-69.
6. Curthbert JA. Wilson's disease: a new gene and an animal model for an old disease. J Invest Med 1995; 43: 323-26.
7. Schilsky M L. Wilson disease: genetic basis of copper toxicity and natural history. Semi L Dis 1996; 16: 83 -95.
8. Ala A, Walker A P, Ashkan K, Dooley J S, Schilsky M L. Wilson's disease. Lancet 2007; 369: 397-408.
9. Brewer G J. Recognition, Diagnosis, and Management of Wilson's Disease. Ex Bio Med 2000; 223: 39-46.
10. Merle U, M Schaefer, P Ferenci, W Stremmel. Clinical Presentation, diagnosis and long-term outcome of Wilson's disease: a cohort study. Liver 2006; 43: 76 -89
11. Walshe J M. Wilson's disease presenting with features of hepatic dysfunction: a clinical analysis of eighty-seven patients. Q J Med 1989; 70: 53 -263.
12. Pandit A N, Bavdekar A, Bhave S. Wilson's Disease. Ind J Pedi 2002; 69: 785-791.
13. Roberts E A, Schilsky M L. A practice guideline on Wilson disease. Hepatology 2003; 37: 1475 - 89.
14. Sternlieb I. Perspectives on Wilson's disease. Hepatology 1990; 12 :1234- 39.
15. Dhawan A ,Taylor R M , Cheeseman P, Silva P De, Katsiyiannakis L, Vergani G M. Liver Transpl 2005;11: 441- 48.
16. Scheinberg IH & Sternlieb I. (editors). Wilson's disease, published by WB Saunders, Philadelphia; 1984.

17. Ferenci P. Pathophysiology and clinical features of Wilson's disease. *Metab Brain Dis* 2004; 19: 229 - 39.
18. Karim MB, Rahman MM, Islam MS. Wilson's Disease with Hepatic Presentation in Childhood. *Mymensing Med J* 2007; 16: 29-32.
19. Durand F, Bernuaum J, Giostra E, Mentha G, Shouval D, Degott C, Benhamou J P, Valla D. Wilson's disease with severe hepatic insufficiency: beneficial effects of early administration of D-penicillamine. *Gut*. 2001; 48: 849 - 52.
20. Ray G, Ghoshal U C, Banerjee P K, Pal B B, Dhar K, Pal A K, Biswas P K. A etiological spectrum of chronic liver disease in eastern India. *Trop Gastroenterol*. 2000; 21(2):60-2.
21. Costa M D, Baldwin D, Portmann B, Lolin Y, Mowet A P, Mieli-Vergani G. Value of urinary copper excretion after penicillamine challenge in the diagnosis of Wilson's disease. *HEPATOLOGY* 1992; 15: 609 - 15.
22. Edwards CQ, Williams DM, Cartwright GE. Hereditary hypoceruloplasminemia. *Clin Genet* 1979; 15: 311 -16.
23. Gitlin J D. Aceruloplasminemia. *Pediatric Research*1998; 44:271-276.
24. Menkes J H. Menkes disease and Wilson's disease: two sides of the same copper ion. Part I: Menkes disease. *Eur J Paediatr Neurol* 1999; 3: 147 - 58.
25. Hanif M, Raza J, Qureshi H, Issani Z. Etiology of chronic liver disease in children. *J Pak Med Assoc*, Received September 6, 2008, from [http://www.ncbi.nlm.nih.gov/pubmed/15129869?ordinalpos=81 &itool=EntrezSystem2.Pent](http://www.ncbi.nlm.nih.gov/pubmed/15129869?ordinalpos=81&itool=EntrezSystem2.Pent).