

# Subcutaneous Fat Necrosis of Newborn (SCFN) Associated with Head Cooling in an Asphyxiated Newborn-A case report

AFMM RAHMAN<sup>1</sup>, AA AMERI<sup>2</sup>, HSA SHEHRI<sup>3</sup>, MAA MRIDHA<sup>4</sup>

## Introduction

Subcutaneous fat necrosis of newborn (SCFN) affects usually full term and post term neonates within the first few weeks of life. It is characterized by areas of firm, mobile, circumscribed nodules and plaques over the trunk, buttocks, extremities and cheek. The overlying skin may be flesh colored, red or violaceous<sup>1</sup>. It consists of mostly lobular panniculitis, with a dense inflammatory infiltrate, crystals of triglycerides in adipocytes and multinucleated giant cells<sup>2</sup>. SCFN may be related with some of the risk factors like traumatic delivery, perinatal asphyxia, hypothermia, maternal diabetes mellitus and preeclampsia of the mother<sup>3,4</sup>. Maternal hypercoagulable state such as protein C deficiency and antiphospholipid syndrome are also risk factors for SCFN<sup>5</sup>. Prostaglandin E administration and cold application for supraventricular tachycardia may rarely be the risk factors for SCFN. But perinatal asphyxia and hypothermia are the most commonly associated risk factors for the development of SCFN<sup>2,6</sup>.

Therapeutic hypothermia is a new method for treating HIE and is used to treat full-term newborns with moderate or severe degree of HIE. Therapeutic hypothermia has neuroprotective benefits and reduces the risk of death or severe functional impairment in newborn with HIE<sup>7,8</sup>. SCFN is a self limited inflammation of the subcutaneous adipose tissue but some complications, such as hypercalcaemia and thrombocytopenia, may arise which need attention<sup>9</sup>. Reported case of asphyxiated full term baby who developed SCFN after head cooling therapy in the NICU of Abha General Hospital, Kingdom of Saudi Arabia.

## Case Report

A female baby delivered by emergency LUCS from a 35-year Saudi woman with Diabetes Mellitus due to

fetal distress and failure to progress in labor. Before LUCS, ventous extraction of fetus was tried which ended up with shoulder dystocia. There was no history of PROM but liquor was meconium stained. There was family history of type-1 Diabetes Mellitus in two siblings of the baby. At birth the baby was found cyanosed, floppy with no respiratory effort and no heart beat and she was covered with meconium. Birth weight of the baby was 4.63 kg, head circumference was 34.5 cm, length was 53 cm. APGAR score was 0/1, 2/5 and 3/10. Head and face of the baby was severely edematous. Immediate resuscitation was done at delivery room and then shifted to NICU for admission with problem of severe perinatal asphyxia, meconium aspiration syndrome, infant of diabetic mother and birth injury.

In NICU the baby was connected to SIMV-PC mode mechanical ventilator due to severe respiratory and metabolic acidosis. Parenteral nutrition, ancillary support and empirical antibiotics were started through umbilical venous catheter. Selective head cooling was started about 2 hours after delivery. Target rectal temperature was kept between 33.5°C – 34.5°C. During the period of head cooling her heart rate was found between 90 -110, BP was maintained within normal limits, Prothrombin time (PT) and activated Partial Thromboplastin Time (aPTT) was found within acceptable range. Head cooling was continued for 72 hours then gradually rewarmed.

At 4 hour of age the baby developed generalized tonic clonic convulsion which was controlled by IV Phenobarbitone. Baby was extubated to N-SIMV mode and then to Nasal prongs O<sub>2</sub> on 5<sup>th</sup> day of life. On 9<sup>th</sup> day of life, an erythematous indurated well demarcated tender lesion was observed below the right axilla and on the lateral aspect of right arm upto elbow joint. CT scan of brain was done on this day, which showed subdural hemorrhage, no evidence of ischemia or focal lesion and normal ventricular system. On the same day, the baby's condition deteriorated and required ventilation again. So she was put on N-CPAP, septic work up was done, antibacterial and antifungal drugs were started and continued for 8 days. After 4 days

1. Specialist Pediatrics and Neonatology, NICU, Abha General Hospital, Abha, KSA

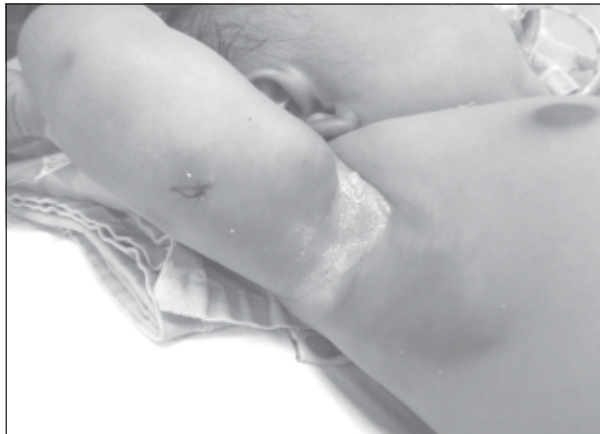2. Head of NICU, Abha General Hospital, Abha, K S A

3. Consultant Dermatology, Abha General Hospital, Abha, K S A

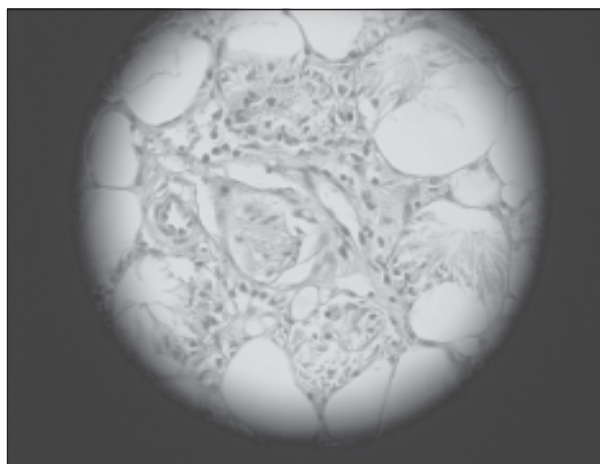
4. Associate Professor, Pediatrics, Shaheed Suhrawardy Medical College, Dhaka, Bangladesh.

**Correspondence:** Dr AFM Mizanur Rahman MD, Specialist, Pediatrics and Neonatology, NICU, Abha General Hospital, Abha, K S A. Email: drmizan007@hotmail.com Mobile:00966562197542

she was put back on Nasal prong O<sub>2</sub> via O<sub>2</sub> blender. On the 14<sup>th</sup> day of life, another erythematous indurated tender skin lesion was observed on the medial aspect of right arm in addition to the previous location. On 25<sup>th</sup> day of life, multiple similar lesions were also observed on the back of the chest and on the occipital area of the skull. Total nine skin lesions were developed. Biggest one was on the lateral aspect of the right arm (size 7 cm × 5 cm) and another one on the right axillary region, size 5 cm × 4 cm (fig. 1). On consultation with dermatologist skin biopsy, some investigations and Inj. Hydrocortisone 5mg I.M for 5 days were given. CBC, peripheral blood film, serum calcium were found normal. X-ray of the lesion did not show any evidence of calcification. Result of skin biopsy showed 'Fat necrosis of subcutaneous fat lobule with infiltration by macrophages, giant cells and few eosinophils' consistent with 'subcutaneous fat necrosis of newborn' (fig. 2)



**Fig 1:** Subcutaneous fat necrosis in a newborn involving right axillary region including upper and inner aspect of right arm



**Fig 2:** Magnifying histological picture of SCFN showing necrosis of subcutaneous fat lobule with infiltration by macrophages, giant cells and few eosinophils

The baby was discharged home on 44 days of life with follow up advice to attend neonatal outpatient department. At five months of age, her skin lesion disappeared completely without any residual lesion.

**Discussion:**

Though exact etiology of subcutaneous fat necrosis of newborn is not yet known but some of the risk factors like traumatic delivery, perinatal asphyxia, local ischemia, hypothermia, maternal diabetes mellitus, maternal cocaine use and preeclampsia of the mother are postulated to be related. Perinatal asphyxia is the most commonly identified predisposing factor<sup>1</sup>. In our case, severe asphyxia with HIE, birth injury and meconium aspiration syndrome were present. Large babies are prone to develop SCFN due to birth injury and due to more subcutaneous fat. Rare examples of SCFN have been described after prostaglandin E administration. The histopathologic picture of SCFN is mostly lobular panniculitis, with a dense inflammatory infiltrate composed of lymphocytes, histiocytes, lipophages, multinucleated giant cells and sometimes, eosinophils interspersed among the adipocytes of fat lobule. Many adipocytes are replaced by cells with finely eosinophilic granular cytoplasm looks like the shape of a narrow needle<sup>2</sup>. Similar consistent histological picture of our case reveals uniform nature of the disease. Perinatal asphyxia triggers the “diving reflex” whereby blood is shunted from the skin and splanchnic beds to the brain, heart and adrenal glands in neonates. The shunting of blood away from subcutaneous tissue creates an environment of hypoxia and hypothermia, which lead to a cycle of granulomatous inflammation and necrosis of adipose tissue<sup>3,4</sup>. Local pressure or trauma during delivery may play a role in the induction of necrosis. SCFN has been reported in children delivered by cesarean delivery, suggesting that pressure necrosis cannot be the only cause<sup>5</sup>. It has been described that hypercalcemia is the most serious potential complication of SCFN which carries a risk of intellectual impairment, calcifications of soft tissues, seizure, cardiac arrest, renal failure and death<sup>6</sup>. We were able to maintain serum calcium level within normal range. One report showed head cooling therapy in HIE stage III is infrequently associated with SCFN<sup>7</sup>. Similar clinical complications developed in our case. Therapeutic hypothermia has neuroprotective benefits and reduces the risk of death or severe functional impairment in newborn with HIE<sup>8</sup>.

SCFN is commonly confused with sclerema neonatorum and cold panniculitis. Sclerema neonatorum can easily be differentiated from SCFN as it occurs in premature, sick baby and generalized nature<sup>9,10</sup>. Cold panniculitis neonatorum can easily be differentiated by its more localized, nodular erythematous lesion developed in cold exposed area only without preceding risk factors or complications. It is also self limiting disorder and requires only symptomatic relief and slow rewarming<sup>11</sup>. SCFN is a very rarely reported condition, so far about 200 cases have been reported all over the world<sup>12</sup>. Though its benign nature due to rarity we are reporting this case.

### Conclusion

Subcutaneous fat necrosis of newborn is a benign hypodermatitis occurs soon after birth, usually within 4 weeks of life among the baby with risk factors. Neonatologists who are taking care of babies with the risk factors associated with SCFN should be vigilant to look for this condition. Though some benign complications like SCFN may arise, still therapeutic hypothermia is a good option for asphyxia with HIE.

### References:

- Vikash O, James T, Noah C, Michel T, Tetzlaff, Albert Y. Subcutaneous Fat Necrosis as a Complication of Whole Body Cooling for Birth Asphyxia. *Archives of Dermatology* 2010;146(8):882-85.
- Requena L, Yus E S, Kutzner H. Panniculitis. In: Wolf K, Goldsmith L A, Katz S I, Gilchrist B A, Paller A S, Leffell D J, editors. *Fitzpatrick's Dermatology in General Medicine*. 7<sup>th</sup> ed. New York: Mc Graw Hill; 2008.p.569- 85.
- Burden AD, Krafchik BR. Subcutaneous fat necrosis of the newborn: a review of 11 cases. *Pediatr Dermatol* 1999;16(5):384-87.
- Mahe E, Girszyn N, Hadj-Rabia S, Bodemer C, Hamel-Teillac D, De Prost Y. Subcutaneous fat necrosis of the newborn: a systemic evaluation of the risk factors, clinical manifestations, complications and outcome of 16 children. *Br J Dermatol* 2007;156(4):709-15.
- Pride H, James WD. Subcutaneous Fat Necrosis of the Newborn, e-medicine. *Medscape. com/article/1081910-overview*. Updated Jan, 2012.
- Diamantis S, Bastek T, Groben P, Morrell D. Subcutaneous fat necrosis in a newborn following iceberg application for treatment of supraventricular tachycardia. *Journal of Perinatology* 2006;26:518-20.
- Adcock L M, Papile L A. Perinatal Asphyxia. In: Cloherty JP, Eichenwald EC, Stark AR, editors. *Manual of Neonatal Care*. 6<sup>th</sup> ed. Philadelphia: Lippincott Williams & Wilkins; 2008. p. 518-28.
- Therapeutic hypothermia is a new method for treating HIE following birth asphyxia and is used to complement standard treatment. Available at [http://www.sbu.se/upload/Publikationer/Content0/3/Therapeutic\\_Hypothermia\\_Perinatal\\_Asphyxia\\_200901.pdf](http://www.sbu.se/upload/Publikationer/Content0/3/Therapeutic_Hypothermia_Perinatal_Asphyxia_200901.pdf), early assessment of new health technologies. sbu alert report 2009-01; 2009-02-25.
- Patterson J W. Panniculitis. In: Bologna J L, Jorizzo J L, Rappini R P. editors. *Dermatology*. 2<sup>nd</sup> ed. Spain: Mosby Elsevier; 2008. p. 1515-35.
- Vijayakumar M, Prahlad N, Nammalwar BR, Shanmughasundharam R. Subcutaneous Fat Necrosis with Hypercalcemia. *Indian Pediatrics* 2006;43:360-63.
- Holla RG, Marendra A, Prasad N. Cold Panniculitis Neonatorum. *Indian Pediatrics* 2009;46: 75.
- Fenniche S, Daoud L, Benmously R, Ammar F, Ammar F Ben , Khelifa I, et al. Subcutaneous fat necrosis: Report of two cases. *Dermatology Online Journal* 2004;10(2):12.