

Case Report

Infantile Cortical Hyperostosis (Caffey Disease): A Case Report

NASREEN ISLAM¹, ABID HOSSAIN MOLLAH², ABU TALHA³, TASNIMA AHMED⁴, JEBUN NAHAR⁵

Introduction

Infantile Cortical Hyperostosis or Caffey disease first described by Caffey in 1945 is a rare self-limiting inflammatory bone disorder of young infants that causes a triad of symptom irritability, soft tissue swelling and underlying cortical bone thickening. The condition may present at birth or thereafter, but almost all cases occur by the age of 5 months. The symmetrical distribution of hyperostosis involving the diaphysis of the long bones and the involvement of the mandible before the age of 5 months together with the fluctuating disease course differentiates this disease from others.^{1, 2}

Case Report

A 4 months old boy was admitted to the department of Paediatrics, BIRDEM General Hospital, Dhaka, Bangladesh on 7/2/2017 with the complaints of swellings in different parts of body from 2 month of age with irritability, inconsolable crying and limitation of movements of both the legs for 1½ months. According to the statement of mother her baby was reasonably alright till 2 month of age. Thereafter mother noticed a swelling in his right arm during feeding. The swelling was non-tender and disappeared spontaneously after a few days. After 7 days there were 2 new swellings over extensor surfaces of both legs. These were bigger and seemed to be tender as he could not move his legs (pseudo-paralysis) and was became irritable this time. There was history of

frequent crying, usually more on handling. Mother also noticed a firm swelling in his lower jaw. On enquiry there was no feeding difficulty. He had no history of fever, trauma/ injury, bleeding in any part of the body. He was seen by number of doctors and was treated with vitamin C and vitamin D time to time. He was also required hospitalization in a local hospital (9/1/2017- 15/1/2017) and treated with injectable antibiotics considering as a case of osteomyelitis but condition did not improved as expected. In this situation the baby was admitted in BIRDEM general hospital for further evaluation and management.

Mother, 32yrs, 3rdgravida with 2 abortions, para 1 had history of regular and uneventful antenatal period . The baby was delivered by caesarean section on 26/09/2016 in a local hospital due to cephalo -pelvic disproportion. He was on exclusive breast feeding for two months, thereafter infant formula was given in feeding bottle. He received BCG vaccine and 1st dose of DPT, Hepatitis B, HIB (penta), Pneumococcal vaccine and oral polio. His mile stones of development was age appropriate. He is the only issue of non-consanguineous parent. There was no such illness in the family. Physical examination showed the baby was afebrile, mildly anemic and other vital signs were within normal limit. Skin survey showed no bleeding manifestation. Anthropometry showed weight 6.4 kg and length 65 cm (both lie between 50th & 75th centiles) and OFC 42cm (between 25th & 50th centiles). Local examination revealed two swellings on extensor surfaces of both legs, firm in consistency, non-tender with shiny overlying skin. Left leg swelling was bigger (6.6 x 7.6 cm) and right leg swelling was smaller and softer. Jaw was enlarged, firm, non-tender. There was no restriction of movement, no external wounds or bruises. Blood examination showed Hb % was low (9.1 gm /dl), total WBC count and platelet count were 14,140 and 5,34000 /cumm of blood respectively. Although Alkaline phosphatase level was slightly raised at 660 U/l (normal upto < 600 U/L), S. calcium, inorganic phosphate, ESR and CRP were normal. Radiographs of long bones (Humerus, both tibiae)

1. Registrar, Department of Pediatrics, BIRDEM General Hospital and Ibrahim Medical College.

2. Professor and Head of the Department of Pediatrics, BIRDEM General Hospital and Ibrahim Medical College.

3. Asstt. Registrar, Department of Pediatrics, BIRDEM General Hospital and Ibrahim Medical College.

4. Registrar, Department of Pediatrics, BIRDEM General Hospital and Ibrahim Medical College.

5. Associate Professor, Department of Pediatrics, BIRDEM General Hospital and Ibrahim Medical College.

Correspondence: Prof. Abid Hossain Mollah, Professor and Head of the Department, Department of Pediatrics, BIRDEM General Hospital and Ibrahim Medical College. E-mail: professorahm@yahoo.com

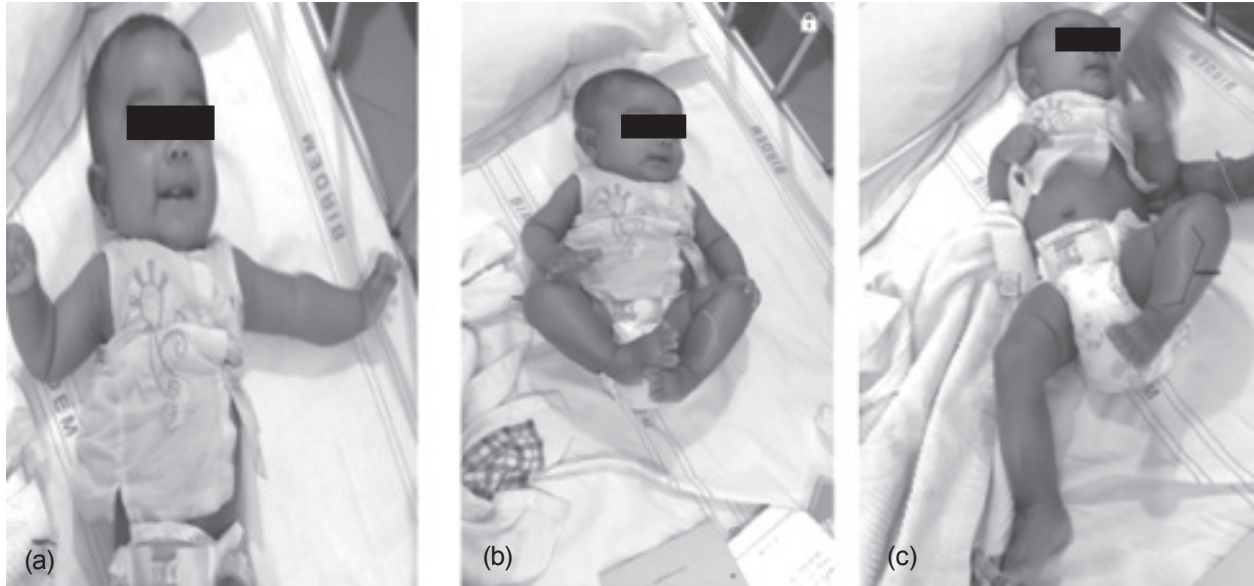


Fig. 1: (a) Jaw swelling, (b) Swellings in the limbs, (c) Swelling in the limbs

and mandible showed presence of bone changes – layers of sub-periosteal new bone with cortical thickening of bone involving the diaphysis of long bones and rami of mandible and overlying soft tissue swelling, both metaphases and epiphyses of the long bones were normal in appearance. Bone density was preserved, no lytic area of bone destruction. A clinical

diagnosis of Caffey disease was made and no medication was advised. On first follow-up two weeks after discharge, right leg swelling completely disappeared, the swelling on left leg was getting smaller. In next two weeks there was further regression of the swelling and no new complaint was mentioned.

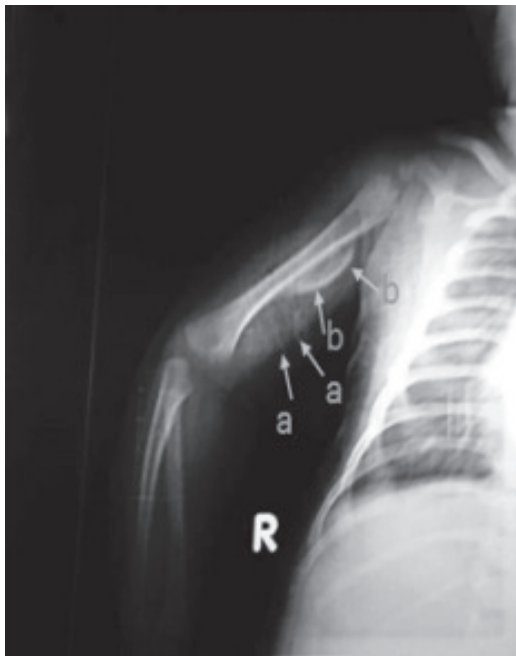

Fig. 1(d): X-ray right upper limb

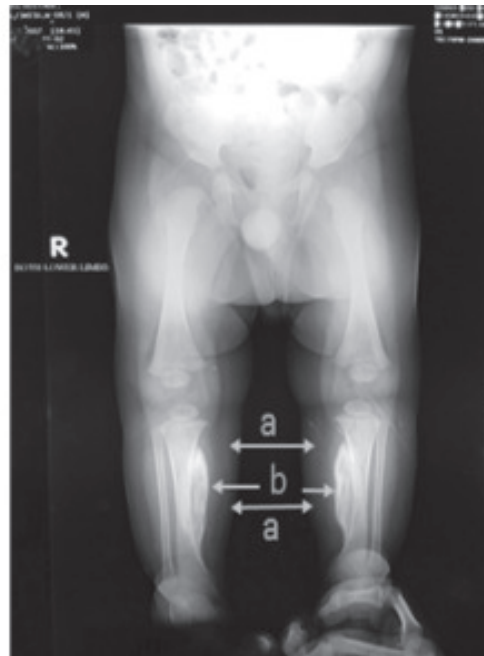

Fig. 1(e): X-ray both lower limbs

Radiographs of long bones (Humerus and Tibiae) showing (a) overlying soft tissue swelling and (b) cortical thickening in the diaphyses sparing metaphases and epiphyses

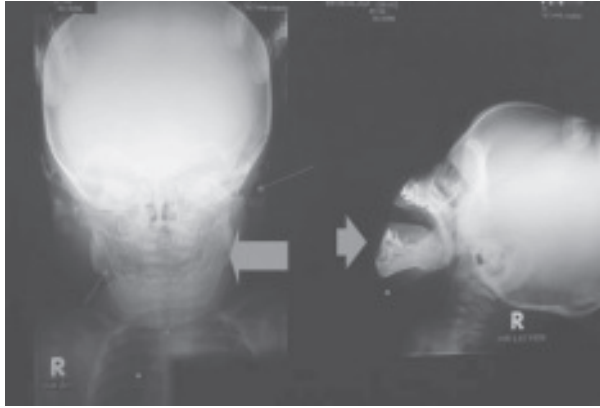


Fig. 1(f) : Radiograph of the jaw (both view) showing jaw enlargement which was depicted as double contour of rami of the mandible as well as overlying soft tissue swelling

Discussion

Infantile Cortical Hyperostosis or Caffey disease is a self-limiting disorder. It was first reported as a disease entity by Caffey and Silverman in 1945.² Initially there was inflammation of the periosteum and adjacent soft tissues ; later periosteal inflammation and sub periosteal changes resolved but there was hyperplasia of lamellar cortical bones and it was responsible for cortical thickening and double contour of cortex. The exact etiology of this condition is still unknown. Most cases are sporadic, but a few familial cases with autosomal dominant and recessive patterns have been described. Among the proposed causes are infectious, immunological defects and genetic abnormalities.³ There is a growing evidence of a genetic component, a mutation in Type I collagen alfa-1 chain gene (COL1A1, 17q21), the gene encoding the alpha 1 chain of type 1 collagen and this has raised some doubts whether some cases are a type of collagenopathy like Osteogenesis imperfecta.⁴⁻⁶ Similar conditions have also been reported following prolonged treatment with Prostaglandin E1 for maintaining ductal patency in infants with cyanotic heart disease.^{7,8} There are two forms of Caffey disease -a classical mild infantile form delineated by Caffey and Silverman and a severe form with prenatal onset. Although the exact incidence of the more common classic form of infantile cortical hyperostosis is unknown, a total of 44 cases have been reported with the severe prenatal onset of cortical hyperostosis.^{2,9,10} The classic form has an onset within the first 6 months of life. The manifestations include irritability, swelling of the overlying soft tissue

and cortical thickening of the underlying bones. The swelling is painful with a wood like induration but with no redness or warmth, thus suppuration is absent. There are usually no other signs and symptoms. The pain can be severe and can also result in pseudo paralysis. The bones involved include the mandible, clavicle, ribs, long bones, scapulae, ilia and skull. The mandible is the most commonly involved site and its involvement is virtually pathognomic.⁴ Other clinical findings are fever, anorexia, dysphagia, nasal obstruction and proptosis.^{9,11,12} Laboratory findings include elevated ESR, and in some patients high alkaline phosphatase, thrombocytosis, anemia and raised immunoglobulin levels.^{13,14} Radiography is the most valuable diagnostic study in Caffey disease. Cortical new bone formation (Cortical Hyperostosis) beneath the regions of soft tissue swelling in the diaphysis, sparing metaphysis and epiphysis is the characteristic feature.³

In our case the baby was presented with multiple swellings with varying degree of tenderness in different parts of the body appeared one following the other with irritability and pseudo paralysis. His jaw was involved, which was pathognomic. He had thrombocytosis and anemia, the alkaline phosphatase was slightly elevated with normal levels of serum calcium and phosphate. There is no specific investigation for the diagnosis of the condition . The characteristic radiological findings of cortical hyperostosis confined to the mandible and the diaphysis of both tibiae helped us to consider this rare diagnosis.

Many a times children may present in this way in certain conditions like osteogenesis imperfecta, osteomyelitis, scurvy, congenital syphilis, hypervitaminosis A, bone tumour and child abuse.^{1,2} But absence of blue sclera, total absence of fractures differentiate this condition from osteogenesis imperfecta. Similarly physical signs, clinical progression, natural history of the other conditions and relevant investigations including radiology are different from the characteristic clinical and radiological feature of Caffey disease.

Caffey disease is generally benign and self-limiting and resolves within six months to one year and may not need any treatment.¹¹ Sometimes Indomethacin and glucocorticoid have been given for the relief of symptoms. The condition may flare up and remit spontaneously and repeatedly without persistent bony deformity.^{11, 12}

Conclusion

The diagnosis of this disease needs an awareness of this condition along with a high index of suspicion. A thorough history, clinical evaluation, basic laboratory investigations to rule out the differential diagnoses and plain radiographs are sufficient enough to confirm the diagnosis in most cases.

References

1. Kutty N, Thomas D, George L, John BT. Caffey disease or Infantile Cortical Hyperostosis: A Case Report. *Oman Medical Journal*. 2010; 25:134-6.
2. Caffey J, Silverman W. Infantile cortical hyperostosis, preliminary report of a new syndrome. *Am J Roentgenol Rad Therapy*. 1945; 54:1-16.
3. Caffey J. Infantile cortical hyperostosis; a review of the clinical and radiographic features. *Proc R Soc. Med* 1957; 50 : 247-54.
4. Restrepo S, Sánchez AM, Palacios E. Infantile cortical hyperostosis of the mandible. *Ear Nose Throat Journal*. 2004; 83:454-5.
5. Glorieux FH. Caffey disease: an unlikely collagenopathy. *J Clin Invest*. 2005; 115: 1142-4.
6. Caffey Disease a type 1 Collagenopathy. *Current GGH*. 2005; 24.
7. de Almeida JFL, Helio K, Luiz H, Eduardo JT. Cortical Hyperostosis secondary to prolonged use of prostaglandin. *Clinics. Sao Paulo* 2007; 62.
8. Nadroo AM, Shivangi S, Garg M. , Al-Sowailen M. Prostaglandin induced Infantile Cortical Hyperostosis. *J Perinat Med*. 2000; 28: 447-52.
9. Susan S, Rabih C, Comelia T, Katharina L, Stephan M, Sigrid T. Antenatal onset of cortical hyperostosis. *Am J Med Genet*. 2003; 120: 547-52.
10. Hall C. Caffey disease. *Orphanet encyclopedia*. Feb 2005.
11. Couper RT, McPheeA, Morris L. Indomethacin treatment of infantile cortical periostosis in twins. *J Paediatr Child Health*. 2001; 37:305-8.
12. Thometz JG, DiRimondo CA. A case of recurrent Caffey disease treated with Naproxen. *Clin Orthop Relat Res*. 1996; 323: 304-9.
13. Temperley IJ, Douglas SJ, Rees JP. Raised immunoglobulin levels and thrombocytosis in infantile cortical hyperostosis. *Arch Dis Child*. 1972; 47:982-3.
14. Kumar TS, Scott JX, Mathew LG. Caffey disease with raised immunoglobulin levels and thrombocytosis. *Indian J Pediatr*. 2008; 75: 181-2.