

Case Reports

Blue Rubber Bleb Nevus Syndrome: A Case Report

ROUSHAN JAHAN¹, RUMANARIAAZ², MD. WAHIDUZZAMUN MAZUMDER³, SHOHELA AKHTER⁴, SHAHANAA RAHMAN⁵

Abstract

Blue rubber bleb nevus syndrome (BRBNS) is a rare condition that is characterized by malformations of the venous system that significantly involve the skin and viscera. Cutaneous malformations are usually asymptomatic and do not require treatment except cosmetic purpose. The treatment of gastrointestinal lesions is determined by the extent of involvement and severity of the disease. We are presenting a case of BRBNS who was admitted in the paediatric ward of Bangabandhu Sheikh Mujib Medical University (BSMMU) with the complaints of progressive pallor since one year of age, passage of blackish stool for last two years, presence of soft bluish/and swelling all over the body and multiple dark blue to blackish nodule present in palm and sole. She got blood transfusion over one hundred (100) times. Endoscopy showed multiple haemangioma with active bleeding in upper GIT. After possible investigations she was diagnosed as a case of BRBNS and treated with available treatment facility.

Keywords: Anemia, Blue rubber bleb nevus syndrome, Haemangioma, Vascular, malformations.

Introduction

Blue Rubber Bleb Nevus Syndrome (BRBNS) is a very uncommon disorder characterized by multiple cutaneous venous malformations in the skin and gastrointestinal tract associated with intestinal hemorrhage and iron deficiency anemia.¹ Other organs may also be involved. In this condition the blood vessels do not develop properly in skin or other organs (particularly in the intestines). The malformed blood vessels appear as a spot or lesion called a nevus.² The underlying blood vessel malformations

usually present from birth or early childhood.³ The size, number, location, and severity of these malformations vary from person to person.² BRBNS has a potential for serious or fatal bleeding. The causes of this syndrome are unknown. Commonly BRBNS presents as sporadic cases, but autosomal dominant inheritance has also been described in some families, where family members usually have other multifocal venous malformations as well.³ It was first recognized by Gascoyen in 1860, but one hundred years later Bean further described these lesions and coined the term Blue rubber bleb nevus syndrome.⁴ Only about 200 hundred case reports published to date. The incidence of BRBNS is very low.⁵ BRBNS affects males and females in equal numbers. We are reporting a 5-year old girl of Blue rubber bleb nevus syndrome who was admitted in the Department of Paediatrics, BSMMU.

Case report

Our patient, a 5-year old girl of non-consanguineous parents, was admitted with the complaints of progressive pallor since one year of age, passage of blackish stool and multiple swelling on different parts

1. Resident Phase-B, Department of Pediatrics, Bangabandhu Sheikh Mujib Medical University, Dhaka
2. Resident Phase-B, Department of Pediatrics, Bangabandhu Sheikh Mujib Medical University, Dhaka
3. Assistant Professor, Department of Pediatric Gastroenterology and Nutrition, Bangabandhu Sheikh Mujib Medical University, Dhaka
4. Associate Professor, Department of Pediatrics, Bangabandhu Sheikh Mujib Medical University, Dhaka
5. Professor and Chairman, Department of Pediatrics, Bangabandhu Sheikh Mujib Medical University, Dhaka

Correspondence: Dr. Roushan Jahan, Resident Phase-B, Department of Pediatrics, Bangabandhu Sheikh Mujib Medical University, Dhaka, E-mail: roushan_koli@yahoo.com Tel: 01711142096.

Received: 05 July, 2017

Accepted: 27 July, 2017

of body for last two years. Her birth history was uneventful, milestones of development were within normal limits, vision, hearing and intelligence was apparently normal. There was no history of similar type of problem in her family. She had history of repeated blood transfusion since one year of her age for severe pallor. Initially she needed monthly blood transfusion, but later on weekly transfusion was needed. She had no history of bleeding from gums, epistaxis, hemoptysis, hematemesis, dyspnea and dysphagia. She did not have any history liver disease and there was no history of taking of any non-steroidal anti-inflammatory drugs.

On examination, she was ill looking, severely pale, severe underweight (WAZ-3.15), severely stunted (HAZ-3) and severely wasted (WHZ-3.6). Haemangiomas were present on different parts of body (Fig.-1). including both elbow, both ankle and right wrist. Multiple blackish nodules were present on sole (Fig.-2), tongue, sclera, scalp and palm. (Fig.-3) The abdomen was soft and non-tender. Hepatomegaly (liver- palpable 5.5cm) was present.

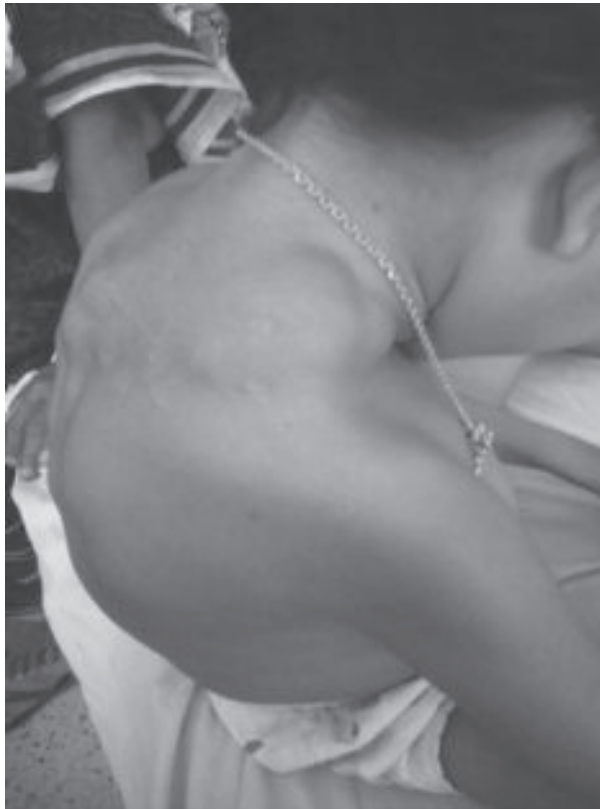

Fig.-1

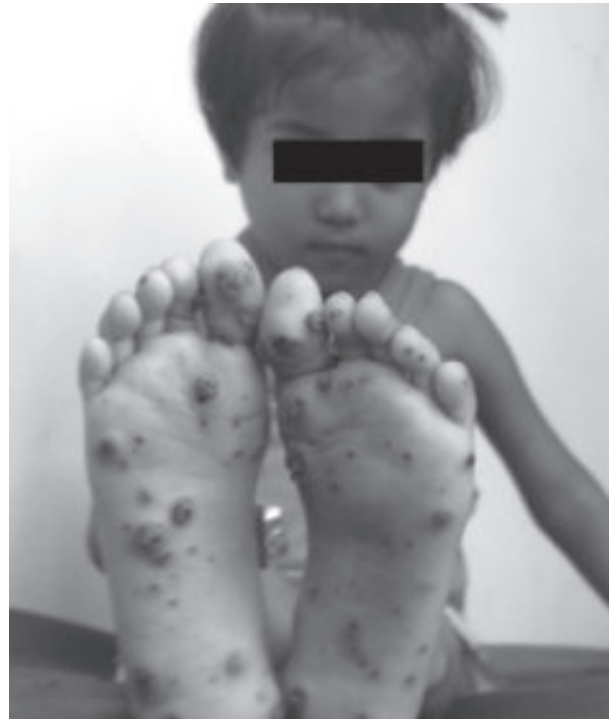

Fig.-2

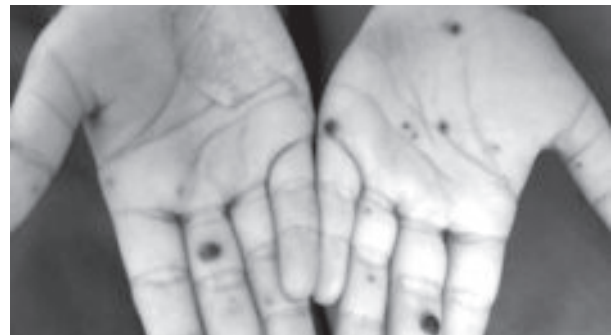

Fig.-3

Investigations showed severe anemia (hemoglobin 4.8g/dL) and normal total, differential and platelet count. Serum ferritin level was normal (16.6 ng/ml). She also had normal PT, APTT level and negative coombs (direct & indirect) test. Fecal occult blood test was positive. Upper GIT endoscopy was done which showed multiple bluish haemangiomas throughout the whole esophagus and stomach (Fig:4), along with old hemorrhagic lesion (Fig.-5). On the basis of the above findings, the diagnosis of venous malformations was compatible with BRBNS. As the disease was very extensive evidenced by clinical and endoscopic finding (multiple haemangiomas and bleeding spot present throughout the gut), hemostatic procedures like sclerotherapy and band ligation were not possible.

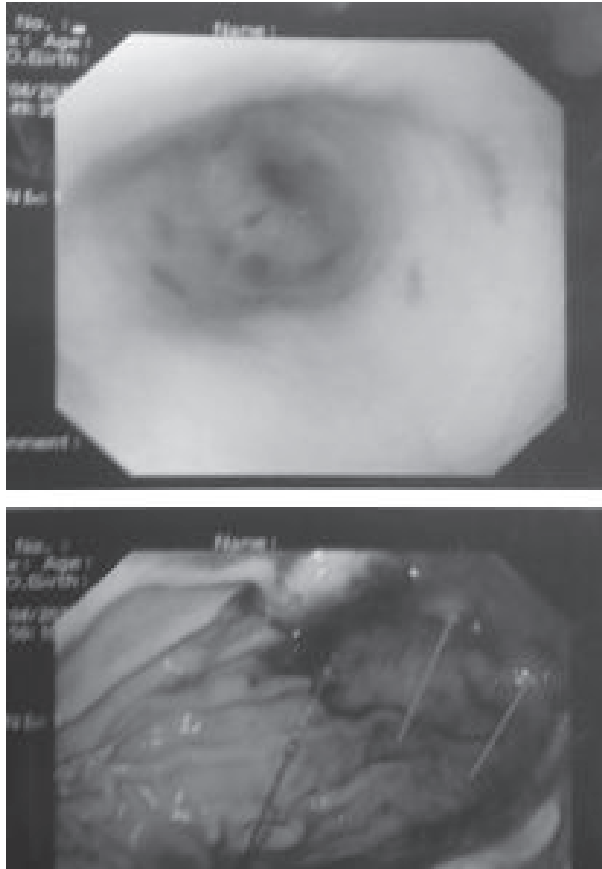


Fig.-4

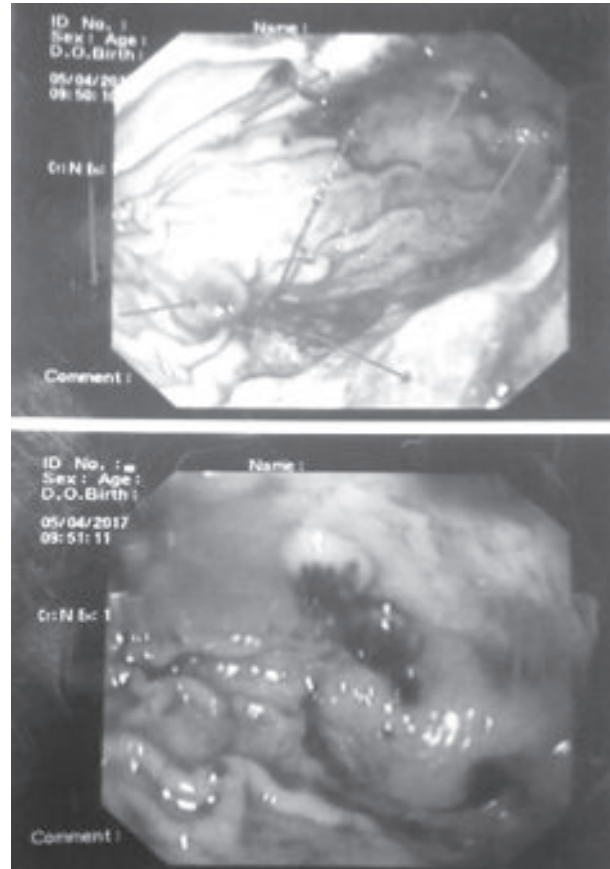


Fig.-3

So she was treated with blood transfusion, iron supplementation, vitamin C supplementation, proton pump inhibitor, propranolol and inj. octreotide (2 micro g/kg intra venous over 20 minutes, then 2 micro g/kg/hr in 500ml 5% DA over 24 hours by continuous infusions). After giving injection octreotide, malaena was stopped. At the same time systemic steroid and H2 blocker was started as no other options was available because of logistics constraints. She was discharged with advice for blood transfusion and regular follow up.

Discussion

BRBNS is a rare disease of venous malformations and haemangiomas which mostly involve the cutaneous and gastrointestinal systems.¹ The cutaneous malformations are bluish and their size vary from a few millimeters to several centimeters in diameter and occur mostly in the trunk and upper extremities⁶, but in our patient it was present all over the body but mostly on feet. The intestinal lesions are most commonly present in the small bowel, but

any part of GI tract may be affected.^{6,7} Upper GI endoscopy of our patient showed lesions present in esophagus and stomach. Rest of the part of the gut could not be visualized. Capsule endoscopy, enteroscopy can directly visualize the lesions in small gut and colonoscopy can visualize colonic lesions.⁸ Capsule endoscope is not available in our set up, and due to very sick condition, colonoscopy could not be done. Complications like intussusception, volvulus, and infarction may occur in BRBNS⁷. Lesions outside the gastrointestinal tract usually do not bleed. The diagnosis of BRBNS is based on the presence of characteristic cutaneous lesion with or without GI bleeding and / or involvement of other organs.⁹ Selective arteriography and scintigraphy can be done for detection of active bleeding. In case of GI lesions, push endoscopic examination is one of the important diagnostic methods. Mucosal resection, argon plasma coagulation, laser photocoagulation, sclerotherapy or band ligation are often necessary to control bleeding⁴. Capsule endoscopy is a new, noninvasive, reliable imaging technique and quite well accepted for the

diagnosis of BRBNS.⁸ Cutaneous angiomas are found on the surface of the skin and can affect the whole body from the scalp to the sole of the foot, which are rubbery, soft, tender and hemorrhagic, easily compressible and promptly refill after compression. Other two types of cutaneous lesions are large disfiguring cavernous lesions and blue black irregular macules or papules⁴. Our patient had typical characteristics of the syndrome including skin lesions, GI lesions and iron deficiency anemia.

She had massive bleeding from gastrointestinal tract and she required frequent blood transfusions even twice in a week. Endoscopy showed extensive bleeding spots and haemangiomas present in esophagus and stomach. Her condition did not allow to do endotherapy like sclerotherapy or band ligation. So we started injection Octreotide (continuous I/V infusion in drip) to stop bleeding and gave propranolol. Previously the only therapeutic measure in BRBNS was frequent blood transfusions to replace blood loss. This strategy unfortunately led to infection by HIV, HBV and HCV. A new treatment method has now been introduced. Yuksekkaya et al first reported the use of low doses irilimus (anti-angiogenic agent) in an 8 year old girl with BRBNS characterized by recurrent severe GI bleeding. The vascular lesions were rapidly reduced after sirolimus treatment, and GI bleeding and muscle hematomas disappeared². No adverse drug reaction due to sirolimus was found over a 20 month follow-up period². As sirolimus is not available in Bangladesh we could not use it.

If conservative therapy is unsuccessful, resection may be needed in BRBNS. The prognosis of BRBNS depends on the organ involvement and their extent of involvement². Most patients live a long life with the disease, but the quality of life is limited due to GI bleeding and symptoms of anemia.

Conclusion

BRBNS is a rare disease of multiple cutaneous venous malformations in the skin and gastrointestinal tract associated with intestinal hemorrhage. Cutaneous manifestation may be symptomless and death can

occur due to GI bleeding. Our patient had the same risk of GI hemorrhages which requires careful follow up and blood transfusion frequently.

Ethical Issue

Written and signed informed consent from the guardian was taken for publishing this case report.

References

1. Dobru D, Seucea N, Dorin M, Careianu V. Blue Rubber Bleb Nevus Syndrome: Case Report and literature Review. *Romanian Journal of Gastroenterology* 2004;13(3):137-40.
2. Jin XL, Wang ZH, Xea XB, Huang LS, Zhao XY. Blue Rubber Bleb Nevus Syndrome: A Case Report and Literature Review. *World Journal of Gastroenterology* 2014;20(45): 17254-9.
3. Krishnappa A, Padmini J. Blue Rubber Bleb Nevus Syndrome. *Indian J Pathol Microbiol* 2010;53:168-70.
4. Bean WB. Blue Rubber Bleb Nevi of the Skin and Gastrointestinal Tract. In: Bean WB, editor. *Vascular Spiders and Related Lesions of the Skin*. Springfield, IL: Charles C Thomas 1958;178-85.
5. Terata M, Kikuchi A, Kanasugi T, Fukushima A, Sugiyama T. Association of Blue Rubber Bleb Nevus Syndrome and Placenta Previa: Report of a Case. *J Clin Ultrasound* 2013;41:517-20.
6. Rodrigues D, Bourroul MLM, Ferrer APC, Deng ZH. Blue Rubber Bleb Nevus Syndrome. *Rev Hosp Clin Fac Med S Paulo*. 2000;55:29-34.
7. Radke M, Waldschmidt J, Stolpe HJ, Keser M, Ozbek O. Blue Rubber Bleb Nevus Syndrome with Predominate Urinary Bladder Haemangiomas. *Eur J Pediatr Surg*. 1993;3:313-6.
8. Munoz-Navas M. Capsule Endoscopy. *World J Gastroenterol*. 2009;15:1584-6.
9. Agnese M, Cipolletta L, Biamco MA, Quitadamo P, Miele E, Staiano A. Blue Rubber Bleb Nevus Syndrome. *Acta Pediatr.w* 2010;99:632-5.