

Subacute Sclerosing Panencephalitis (SSPE) in Toddlers and Young Children: A Case Series

SARAH ALAM¹, NARAYAN CHANDRA SAHA², SEIKH AZIMUL HOQUE³,
CHOWDHURY MUHAMMAD FUAD GALIB⁴, YAMIN SHAHRIAR CHOWDHURY⁵

Abstract

SSPE is a neurodegenerative disorder caused by persistent defective or mutant measles virus. The disease has a gradual progressive course leading to death within 1-3 yrs or even early. SSPE is a disease of childhood and early adolescence. The classic age at presentation is 8-11 years and usually occurs after a latent period of average 6 years. Here we report 3 cases of SSPE in toddlers. Diagnosis was made on the basis of clinical presentation, EEG pattern and elevated CSF anti measles antibody titer as described in Dykan criteria for diagnosis of SSPE. Clinical presentation was very early with a relatively shorter latency and fatal progression. Two patients had past history of measles and all patients were immunized against measles. One patient died within 4 months of disease expression and 2 patients went into vegetative state within 3 months of disease onset.

Key words: Subacute Sclerosing Panencephalitis (SSPE), Measles, Toddlers.

Introduction

SSPE is a progressive neurological disease with fatal consequence. With effective measles vaccination the burden is now reduced in developed countries but still Asian and African countries accounts for majority of measles related deaths.¹ According to World Health Organization (WHO) global incidence is 4-11 SSPE patients per 100,000 measles cases. If measles occurs in early childhood, the risk of SSPE is much higher (18 per 100,000 measles case).² Measles vaccine has a great protective effect against SSPE by protecting against measles. The probability of developing SSPE after measles infection is also genetically influenced. Variation in the global incidence indicates that genetic factors are involved.³ Measles virus undergoes genetic mutation after entry into the brain.⁴ Due to genetic changes it becomes hyperfusogenic which facilitate their neuron to neuron transmission. This leads to persistence of measles

virus within brain leading to panencephalitis, demyelination, ultimately neuronal loss and reactive astrocytosis. SSPE diagnosis was made by using Dykan criteria which includes: 1) clinical features of decreasing cognition and myoclonus, 2) periodic discharge on EEG, 3) raised CSF Ig level, 4) elevated titers of anti-measles antibody and 5) brain biopsy. Definitive SSPE is diagnosed with 3 or more criteria. CSF anti-measles antibody was measured by quantitative ELISA.

Here we described three cases who presented to us with gait disturbance, progressive myoclonus, decline in cognition and other development milestones. All the patients were below five years and minimum age was three years. So, our main differentials were degenerative brain disease, progressive myoclonic epilepsy, myoclonic atstatic epilepsy and SSPE. The age of presentation was quite early than the usual age (8 to 11 years) for SSPE. Moreover, all the children were immunized against measles but two children had past history of measles. Clinical implication would mean investigating for SSPE even in completely immunized toddlers with compatible clinical features and with or without prior history of measles. The relatively shorter latency period and the fatal progression were also another concern.

1. Medical officer, Paediatric Neurology National Institute of Neuroscience (NINS), Dhaka.
2. Professor Paediatric Neurology, NINS, Dhaka.
3. Associate Professor, Paediatric Neurology NINS, Dhaka.
4. Assistant Registrar, Paediatric Neurology NINS, Dhaka.
5. Assistant Professor, Paediatric Neurology, NINS, Dhaka.

Correspondence: Dr. Sarah Alam, Medical officer, Paediatric Neurology, National Institute of Neuroscience, Dhaka, Bangladesh, Mobile no: +8801714558800, Email: sarahalam3@gmail.com

Received: 6/01/2020

Accepted: 27/06/2020

Case Report

Case-1:

A 3Yrs old immunized boy, born to a non-consanguineous parent with no perinatal complication was referred to National Institute of Neuroscience, Dhaka with the complaints of frequent fall during walking and jerky movement of the body for 25 days, gradual deterioration of cognition and speech during the course of illness and became bed bound for 10 days. Myoclonic jerks were present from beginning of illness with increasing frequency. Regarding cognition patient did not follow any command. There was no history of fever, trauma and measles in the past or any family history of such type of illness.

On examination patient was restless, irritable, vitals were stable, did not follow any command and frequent myoclonic jerks were observed. BCG mark was present, GCS: 10/15. Cranial nerves were intact,

motor-bulk (N), tone-variable, power- $\frac{3}{5}$, jerks-exaggerated in all four limbs and planter-bilaterally extensor. Regarding investigations routine investigations & CT scan of brain were normal. EEG showed frequent periodic generalized high voltage discharge with slow background (Fig. 1). CSF routine study was normal. But CSF anti-measles IgG was 673.9 mIU/ml which was positive. We treated the patient supportively. Antiepileptic drugs were started – Na valproate and clonazepam. Counseling was done regarding disease progression, outcome & treatment option. Patient was discharged with plan for F/up. The patient died within 3 months after discharge.

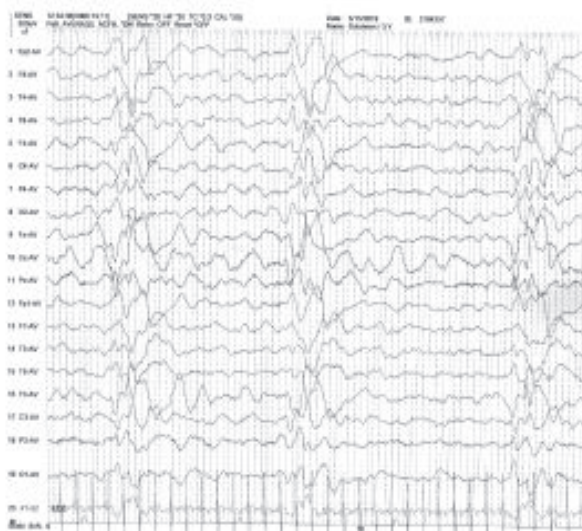


Fig 1: EEG showing periodic slow wave complex (Duration 20 Sec)

Case-2:

A boy of 4 and half years old presented with the complaints of frequent fall during walking, jerky movement of body and developmental regression for 35 days. Patient gradually developed walking difficulty and then unable to walk for 15 days. Patient gradually lost his achieved milestone of development during the period of his illness. He was mute with marked cognitive deterioration. Parents gave history of measles at 19 months of age. On examination he was minimally conscious, no communication with surroundings, vitals-stable, cranial nerves-intact. Motor findings: tone-hypotonic, power-2/5, jerks-present in all four limbs, planter flexor bilaterally. No social smile, neck control, sitting, walking and speech.

Routine investigations CBC, S. creatinine, S.ALT, S. electrolytes, ABG were normal. EEG showing generalized high voltage slow wave discharge (fig 2). Neuro imaging revealed no significant abnormality. CSF routine, lactate was normal but CSF anti-measles antibody titer was 579.4:1 which was positive. AED was started with other supportive measures. Counseling was done then discharged the patient with F/up plan.

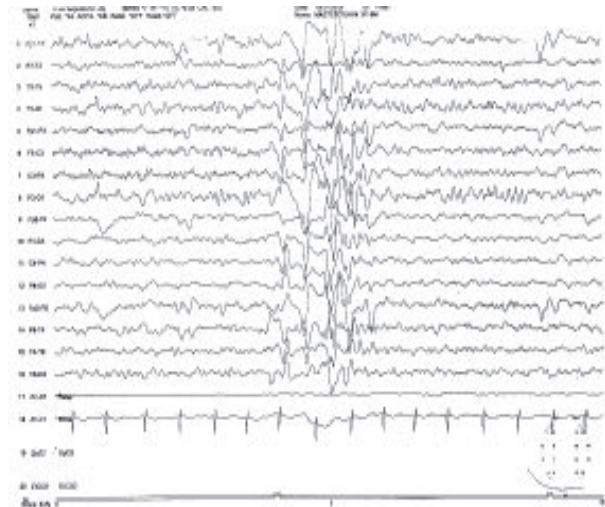


Fig 2: EEG showing high voltage generalized slow wave discharge (Duration 10 Sec)

Case-3:

A 3 Year 8 months old boy admitted with the complaint of frequent fall due to sudden jerky movement of body for 1 month, loss of speech and unable to walk for 2 wks. Myoclonic jerks progressively increased and patient became unable to sit and walk. He also lost

his achieved development milestone including speech with marked deterioration of cognition and motor function. He had measles infection at 18 months of age but completely immunized against measles. On examination higher psychic function was impaired, vitals-stable, frequent myoclonic jerks 2-3 episodes/min, cranial nerves- intact, motor findings were, tone-variable, power-diminished, jerks-brisk in all four limb and planter was withdrawal. Routine investigations-CBC, urine R/E, S. electrolytes, SGPT, creatinin and basic metabolic screening were within normal limit. CT scan of brain was normal. EEG reveled generalized periodic complex (fig 3) Eye assessment showed macular lesion in left eye. CSF for routine and lactate was normal and CSF for anti-measles antibody IgG titer was 312.3:1 which was positive.

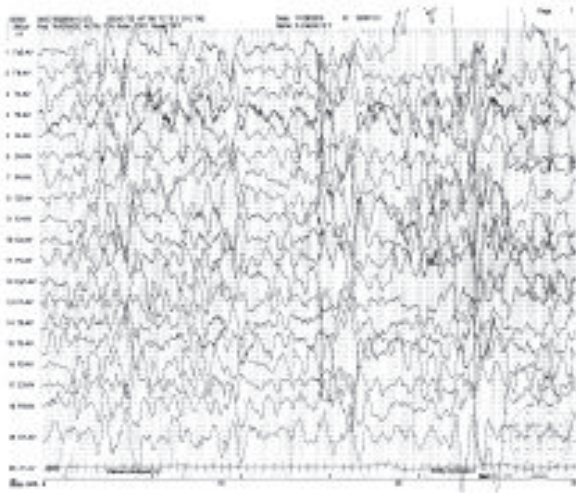


Fig.-3: EEG showing periodic complex (duration 60 sec)

DISCUSSION

Measles is a highly infectious viral disease and spreads rapidly by air borne route. Measles related neurological syndromes include primary measles encephalitis, acute post measles encephalitis, measles inclusion body encephalitis and SSPE.⁵ A number of factors are associated in the development of SSPE following measles infection. Reported risk factors are younger age at measles, male child, poverty, rural area, overcrowding, higher birth order and higher no of siblings.⁶ Genetic susceptibilities also found to be associated with the development of SSPE following measles infection. In our case series two patients had history of measles infection at 18 months of age and disease symptoms started about two years after the initial infection. Clinical progression was so rapid that one patient died within

4 month of disease onset and another 2 patients went into vegetative state within 3 month of disease course. The early age of disease onset in a vaccinated child, with a relatively shorter latency period and of course the fatal progression was our main concern. Moreover, we got all the cases within 6 months of period between May to October 2019. Whether there is any seasonal variation or co-infection or association with other viral infection is needed to be ascertained. Atypical fulminant course, lowest age of onset of SSPE after measles infection was 10 month and minimum latency period 2 months were noted.⁷ Many case-control studies observed genetic defects in components of innate immunity including Toll like receptors and cytokines.⁸ So, it is now time to address the genetically determined immune dysfunction leading to these atypical presentations. Identification of mutation of wild measles virus strain and association with the fulminant course should be introduced. With changing epidemiological trends, it is now necessary to put suspicion to detect SSPE with atypical presentation like early onset and shorter latency period with or without typical clinical pictures.

One of our patients did not have any H/O previous measles infection. In children with SSPE, without definitive evidence of prior measles infection it is likely that children either had a subclinical or under diagnosed measles in the early childhood.⁹ Measles vaccine is highly protective against SSPE. All the patients of our case series were properly immunized against measles. In a child with adequately covered measles vaccine, wild measles infection is presumed to occur before vaccination and two of our patient had history of measles infection at about 18 months of age which is also found by Bellini WJ et al.¹⁰ Vaccination failure should also be kept in consideration.

Clinical manifestations were almost similar in all 3 cases. Gait disturbance, progressive myoclonus, marked cognitive and speech deterioration and loss of achieved motor skill were prominent features. Visual problem was not marked but one patient had macular abnormalities. Green SH reported, every component of visual system starting from retina to visual cortex may be involved.¹¹ Routine investigations were within normal limit including brain imaging. EEG provides an important clue regarding SSPE and demonstrates bilaterally synchronous, high voltage spike or slow-wave periodic bursts. As

SSPE progress, the background activity becomes suppressed. In all the patients we found - high voltage generalized periodic slow wave complex on EEG recording and this was in favor of our diagnosis. In all three cases there were elevated IgG level (anti-measles antibody) in CSF measured by quantitative ELISA method. Boor S concluded when there is clinical suspicion evidence of measles antibody in CSF is enough for clinical diagnosis of SSPE.¹² Watanabe S reported that CSF antibody levels may fluctuate.¹³ So clinical and other criteria are to be relied upon for specific diagnosis of SSPE. Kasinathan A¹⁴ reported two cases of SSPE at 26 months and 27 month of age in India and after review of literature he concluded that atypical presentation of SSPE should be considered in the differential diagnosis of any unexplained neurological illness irrespective of age, especially in endemic countries, which is consistent with our observation.

Conclusion

Now a day a good number of SSPE cases are reported with very early onset & fatal progression. Atypical presentation of SSPE should be considered in the differential diagnosis of any unexplained neurological illness irrespective of age, especially in endemic countries. The cause behind this short latency & rapid progression need to be ascertained. SSPE in a completely vaccinated child is now a challenging issue. Because vaccination is the only preventive measure to combat SSPE.

References:

- World health organization. Progress towards regional measles elimination-worldwide,2000-2017. Weekly epidemiological record.2018, 93, 649-660. Downloaded from <https://apps.who.int/iris/bitstream/handle/10665/276217/WER9348.pdf?ua=1&ua=1>.
- World health organization. Weekly epidemiological record. No 2, 2006,81,13-20 http://www.who.int/vaccine_safety/committee/reports/wer8102.pdf?ua=1. accessed on 28 March,2019.
- Hashiguchi T, Fukuda Y, Matsuoka R, et al. Structures of the prefusion form of measles virus fusion protein in complex with inhibitors. Proc Natl Acad Sci USA.2018;115:2496-2501.
- Cattaneo R, Schmid A, Eschle D, Baczko K, V ter Meulen, M A Billeter. Biased hypermutation and other genetic changes in defective measles viruses in human brain infections. Cell. 1988;55:215-25.
- Anlar B. Subacute sclerosing panencephalitis and chronic viral encephalitis. Handb Clin Neurol 2013; 112:1183-89.
- Gutierrez J, Issacson RS. Subacute sclerosing panencephalitis: An update. Dev Med Child Neurol 2010; 52:901-7.
- Saurabh K, Gupta R, Khare S, Sharma S. Atypical subacute sclerosing panencephalitis with short onset latency. Indian Pediatr 2013; 50:244-5.
- Karakas-Celik S, Piskin IE, Keni MF, Calik Mustafa, Iscan Akin, Dursun. May TLR4 Asp299 Glyand IL17 His161Arg polymorphism be associated with progression of primary measles infection to subacute sclerosing panencephalitis Gene. 2014; 547:186-90.
- Zilber N, Kahana E. Environmental risk factors for subacute sclerosing panencephalitis (SSPE). Acta Neurol Scand.1998;98: 49-54.
- Bellini WJ, Rota JS, Lowe LE, Katz RS, Dyken PR, Zaki SR et al. Subacute sclerosing panencephalitis: more cases of the fatal disease are prevented by measles immunization than was previously recognized. J Infect Dis. 2005; 192: 1686-93.
- Green SH, Wirtschafter JD. Ophthalmoscopic findings in subacute sclerosing panencephalitis. Br J Ophthalmol. 1973;579:780-787.
- Broor S, Pal SR. Subacute sclerosing panence-phalitis in Chandigarh. Indian J Med Res. 1979: 536-39.
- Watanabe S, Shirogane Y, Sato Y, Hashiguchi T, Yanagi Y. New insights into measles virus brain infections. Trends Microbiol.2019;27:164-75.
- Kasinathan A, Sharwat IK, Kesavan S, Suthar R, Sankhyan N. Early onset subacute sclerosing panencephalitis: Report of two cases and review of literature. Ann Indian Acad Neurol 2019;22:361-63.