

Clinical Pattern and Associated Comorbidities of Corpus Callosum Agenesis- A Tertiary Hospital Study

GOPEN KUMAR KUNDU¹, ANJIR ANOWER², RUMANA ISLAM³

Abstract

Background: The corpus callosum is the main commissural bundle of fibers interconnecting the two cerebral hemispheres. Defective embryogenesis during 8 and 20 weeks of gestation can lead to partial or complete agenesis of the corpus callosum.

Objective: To see the patient's clinical, neurophysiological profile, and comorbidities with corpus callosum agenesis presented in tertiary care hospital.

Materials & Methods: This descriptive cross-sectional study was conducted in the department of Paediatric Neurology, BSMMU, Dhaka, from January to December 2018. Patients who were diagnosed clinically and neuro-radiologically as corpus callosum agenesis were included in this study.

Results: Out of 20 patients, 45% were in 13-24 months and 30% were in the 0-12 months' age group. Female patients (55%) were predominant. Forty percent of patients had microcephaly and 30% facial dysmorphism. The majority of patients presented with developmental delay (90%), followed by epilepsy, speech impairment, and mental retardation. About one-fourth (25%) of patients were diagnosed as quadriplegic cerebral palsy and one-third (30%) dyskinetic cerebral palsy. Abnormal ophthalmological findings were found in 40% of cases. EEG showed hypsarrhythmia in 30%, partial seizure with secondary generalization in 15%, and myoclonic epilepsy in 15% of patients.

Conclusion: In this study, common clinical features of patients with corpus callosal agenesis were developmental delay, facial dysmorphism, and microcephaly. About half of the patients had epilepsy, speech impairment, and mental retardation. About two-thirds of the patients had EEG changes and the most common EEG change was hypsarrhythmia.

Keywords: Corpus callosal agenesis, Co-morbidities, Cerebral Palsy (CP)

Introduction

The corpus callosum is the largest commissural fibers interconnecting the two cerebral hemispheres.¹ It consists of about 200 billion neurons. Embryologically, it is derived from the midline prosencephalic commissural plate and the timing of formation of the corpus callosum between the ten to twenty weeks of

gestation coincides and overlaps with the occurrence of complex processes involving neuronal proliferation.² Defective embryogenesis during this period can lead to the partial or complete absence of corpus callosum. Corpus callosum development begins from the cranial part and progresses caudally, so partial agenesis always involves the posterior segment of it.³ In addition to agenesis of corpus callosum, there may be hypogenesis, dysgenesis, and hypoplasia.

The incidence of agenesis of the corpus callosum has not been well defined, varying in surveys of patients undergoing neuroimaging.⁴ The incidence of corpus callosum agenesis has been difficult to estimate because of the inherent unrecognizability of asymptomatic cases. An incidence of 2 to 3% has been reported from the developmentally disabled

1. Professor, Department of Paediatric Neurology, BSMMU, Dhaka
2. FCPS Part II Student (Paediatric Neurology & Neuro-development) BSMMU, Dhaka.
3. Resident, Department of Paediatric Neurology, BSMMU, Dhaka

Corresponding author: Dr Gopen Kumar Kundu, Professor, Paediatric Neurology, Bangabandhu Sheikh Mujib Medical University (BSMMU), Dhaka, Bangladesh, Mobile : +8801718590768
Email: gopen.kundu@gmail.com

Received: 15/05/2020

Accepted: 13/03/2021

population.⁵ Development of corpus callosum begins in the front and progresses caudally so partial defect always involves the posterior segment of the corpus callosum.² Etiopathogenesis of this malformation is not exactly known. It is multifactorial such as genetic, chromosomal, metabolic, and exogenous factors (bleeding, infections).^{1,6} Anomalies of the corpus callosum often occur with other brain malformations (Chiari II malformation, encephalocele, and anomalies of neuronal migration such as schizencephaly, lissencephaly, pachygyria, and heterotopias).^{1,2,7} They can be part of chromosomal syndromes (trisomy 8, 13, 18, or 21), as well as some X-linked syndromes, in particular, Aicardi's syndrome; CRASH (corpus callosum hypoplasia, retardation, adducted thumbs, spastic paraparesis, and hydrocephalus); and FG syndrome. They also can accompany some inborn errors of metabolism (nonketotic hyperglycinemia, lactic acidosis, pyruvate dehydrogenase complex deficiency, Zellweger syndrome, Menkes's syndrome, or hurler's syndrome).^{1-6,8-11}

Diagnosis of agenesis of corpus callosum requires neuroimaging observations which are undertaken for developmental delay or epilepsy. Neuroimaging findings include widely displaced and parallel lateral ventricle, selective dilatation of posterior horns (colpocephaly), upward displacement of the third ventricle, displaced orientation of gyral markings, and absence of corpus callosum.¹² The aim of the study was to see the clinical, neurophysiological profile, and comorbidities of corpus callosum agenesis patients presented in the tertiary care center.

Materials & Methods

This descriptive cross-sectional study was conducted in the Paediatric Neurology Department of Bangabandhu Sheikh Mujib Medical University (BSMMU), Dhaka from 1st January 2018 to 31st December 2018 to observe the clinical, neurophysiological profile and comorbidities of corpus callosum agenesis patients. Patients who attended in paediatric neurology OPD, BSMMU and neuro-radiologically diagnosed as corpus callosum agenesis were included in this study.

All children with neuro-radiologically diagnosed as corpus callosum agenesis were evaluated clinically.

Psychological, neurophysiological and ophthalmological evaluation was done in all cases. Associated comorbid conditions such as down syndrome, hypospadias, dandy walker malformation, congenital heart disease, and hypothyroidism were evaluated by specific investigations. Informed written consent of the parents or guardians of eligible children was obtained. Data were collected in structured data collection sheets. Ethical permission was taken from ethical review board of BSMMU.

Result:

Out of total 20 patients, about half of the patients (45%) were in the 13-24 months age group, and one-third of patients (30%) in 0-12 months, Majority of the patients were female (55%) and 45% patients were male. Forty percent of patients had microcephaly, 30% of patients had facial dysmorphism including V-shaped upper lip and large ear.

The majority of patients (90%) presented with developmental delay, 60% had epilepsy and speech impairment and 50% had intellectual disability, 25% of patients had quadriplegic CP and 30% were dyskinetic CP. Other patients had Down syndrome, dandy walker malformation, congenital heart disease, hypothyroidism. Among abnormal ophthalmological findings, optic atrophy was found in 15%, coloboma iris in 10%, coloboma eyelid in 5%, cataract in 5%, chorioretinal lacunae in 5% cases. Normal eye findings were found in 60% of patients. EEG showed hypersarrhythmia in 30% of patients, partial seizure with secondary generalization in 15%, and myoclonic in 5% of patients. EEG was normal in 35% of cases.

Table-I
Distribution of study cases by age and gender
(n = 20)

Age (month)	Number (%)
0 – 12	6 (30%)
13 – 24	9 (45%)
25 – 36	2 (10%)
>36	3 (15%)
Gender	
Male	9 (45%)
Female	11 (55%)

Table-II

Clinical features of the study population (n=20)

Physical Abnormality	n (%)
Developmental delay	18 (90%)
Microcephaly	8 (40%)
Facial Dysmorphism	6 (30%)
Failure to thrive (FTT)	3 (15%)
Craniofacial abnormalities	2 (10%)

Table-III

Neurologic Impairment of study subject (n=20)

Neurologic Impairment	n (%)
Epilepsy	12 (60%)
Speech impairment	12 (60%)
Intellectual disability	10 (50%)
Dyskinetic CP	6 (30%)
Quadriplegic CP	5 (25%)

Table -IV

Ophthalmological findings of the study population (n=20)

Ophthalmological findings	n (%)
Optic atrophy	3 (15%)
Coloboma iris	2 (10%)
Coloboma eyelid	1 (5%)
Cataract	1 (5%)
Chorioretinal lacunae	1 (5%)
Normal	12 (60%)

Table V

Associated co-morbid condition of the study subject (n=20)

Co-morbid condition	n (%)
Down syndrome	1
Hypospadias	1
Other Syndrome	2
Dandy-Walker malformation	1
Congenital heart disease	1
Hypothyroidism	1

Table VII

EEG findings in study population(n=20)

EEG Changes	n (%)
Hypsarrhythmia	6 (30%)
Generalized epilepsy	3 (15%)
Partial with secondary generalized epilepsy	3 (15%)
Myoclonic Epilepsy	1 (5%)
Normal	7 (35%)

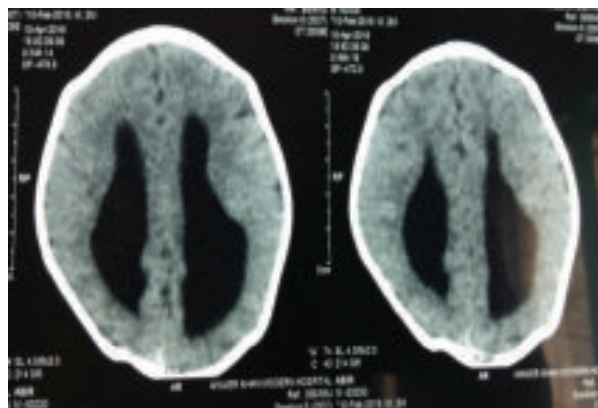


Fig.-1: Widely displaced and parallel lateral ventricles (racing car appearance) indicate corpus callosum agenesis.

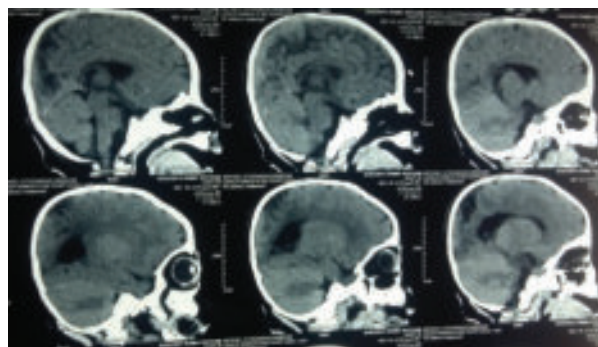


Fig.-2: Dilatation of posterior horn of lateral ventricle indicates colpocephaly

Discussion

This descriptive cross-sectional study was carried out to see the clinical, neurophysiological profile of children with corpus callosum agenesis and to evaluate the comorbidities of corpus callosum agenesis. This study reported slight female preponderance of those affected with agenesis of the corpus callosum. Different neurologic symptoms and signs like spastic paresis, hypotonia, pyramidal syndromes, eye abnormalities (nystagmus, ptosis, microphthalmia,

blindness, cataracts, and lacunar chorioretinal lesions), and hearing disturbances were found in children with corpus callosal agenesis.^{2,5,13-18} Most symptoms and signs are the part of syndromic forms of callosal agenesis. In our present series 40% of the patients presented with eye abnormalities and common eye abnormalities were optic atrophy (15%), coloboma iris (10%), coloboma eyelid (5%), cataract (5%), chorioretinal lacunae (5%). Epilepsy had been reported as a frequent symptoms in most of the series of callosal agenesis.^{1,4,16-18} In our study more than half (60%) of the children had associated epilepsy, which was similar to the study done by Taylor & David¹⁶ and Marszal E et al.¹³ In this study microcephaly was found in 40% of cases which was similar to Michael Shevell¹⁷ where they found it in 37.5% cases.

Marszal E et al.¹³ in their study found that about 83.3% of patients had developmental delay, which was similar to our study as we found in 90% cases with corpus callosum agenesis. Intellectual disability were most commonly reported symptoms of many series.^{5,16,18} Our study showed intellectual disability in 50% of cases that were compatible to findings of Taylor and David.¹⁶ EEG findings of corpus callosum agenesis are nonspecific and interpretation of EEG is difficult since the frequent seizures caused by brain anomalies complicate the wave pattern of EEG.^{5,19-21}

We found epileptic discharges in 65% cases and most commonly hypsarrhythmias, in 30% of cases. Marszal E et al.¹³ found hypsarrhythmia in majority of the cases in their study that was compatible with our study. In this study, 5% of the cases had associated Down syndrome, 5% Dandy-Walker malformation and congenital heart disease in 5% of cases with corpus callosal agenesis. Agenesis of the corpus callosum also reported within the context of readily recognized specific major malformation syndromes^{20,22} (eg, holoprosencephaly, lissencephaly, Dandy-Walker, Chiari II).

Conclusion:

Common clinical features of corpus callosal agenesis were developmental delay, facial dysmorphism and microcephaly. About half of the patient had comorbidities like epilepsy, speech impairment, and intellectual disability. About two-third of the patient had EEG changes and the most common EEG change was hypsarrhythmia.

References

- Giedd JN, Rumsey JM, Castellanos FX, Rajapakse JC, Kaysen D, Vaituzis AC et al. A quantitative MRI study of the corpus callosum in children and adolescents. *Brain Res Dev Brain Res.* 1996 ;91:274-80.
- Volpe JJ. Neural tube formation and prosencephalic development. *Neurology in Newborn.* 1995:3-42.
- Ettlinger G.: Agenesis of the corpus callosum, in Vinken PJ, Bruyn GW (eds): *Handbook of Clinical Neurology*, Vol. 30. New York, Elsevier/North-Holland Biomedical Press, 1975, 285-297.
- Luef G, Birbamer G, Marosi M, Felber S, Kampfl A, Aichner F et al. Agenesis of the corpus callosum and epilepsy in two brothers. *Neurophysiological and MRI features Wien Klin Wochenschr.* 1992; 104:301-4.
- Jeret JS, Serur D, Wisniewski K, Fisch C. Frequency of agenesis of the corpus callosum in the developmentally disabled population as determined by computerized tomography. *Pediatr Neurosci.* 1985;12:101-3.
- Warkany J, Lemire RJ, Cohen Jr MM: *Mental Retardation and Congenital Malformations of the Central Nervous System.* London, Year Book Medical Publishers, 1981, pp 224-244.
- Castro-Gago M, Rodriguez-Nuñez A, Eiris J, Peña J, Tojo R, Novo-Rodriguez I et al. Familial agenesis of the corpus callosum: A new form. *Archives francaises de pediatrie.* 1993;50:327-30.
- McKusick VA: *Mendelian Inheritance in Man. A Catalog of Human Genes and Genetic Disorders*, 11th ed, vol 2. Baltimore, Johns Hopkins University Press, 1994, pp 2338-2339, 2355.
- Yamasaki M, Thompson P, Lemmon V. CRASH syndrome: mutations in L1CAM correlate with severity of the disease. *Neuropediatrics.* 1997; 28:175.
- Vergani P, Ghidini A, Strobelt N, Locatelli A, Mariani S, Bertalero C et al. Prognostic indicators in the prenatal diagnosis of agenesis of corpus callosum. *Am J Obstet Gynecol.* 1994 ;170(3):753-8.
- De Meirleir L, Lissens W, Denis R, Wayenberg JL, Michotte A, Brucher JM et al. Pyruvate dehydrogenase deficiency: clinical and biochemical diagnosis. *Pediatr Neurol.* 1993 ;9:216-20.
- Cardoza JD, Herfkens RJ: *MRI Survival Guide.* New York, Raven Press, 1994, p 66.
- Kolodny EH. Agenesis of the corpus callosum: A marker for inherited metabolic disease? 1989: 847.
- Marsza³ E, Jamroz E, Pilch J, Kluczevska E, Jab³ecka-Deja H, Krawczyk Ret al. Agenesis of corpus callosum: clinical description and etiology. *J Child Neurol.* 2000 ;15: 401-5.
- Jeret JS, Serur D, Wisniewski KE, Lubin RA. Clinicopathological findings associated with agenesis of the corpus callosum. *Brain Dev.* 1987; 9 (3):255-64.
- Taylor M, David AS. Agenesis of the corpus callosum: a United Kingdom series of 56 cases. *J Neurol Neurosurg Psychiatry.* 1998 ;64:131-4.
- Shevell MI. Clinical and diagnostic profile of agenesis of the corpus callosum. *J Child Neurol.* 2002 ;17:895-9.

18. Aicardi J, Bax M, Gillberg C, Ogier H. Diseases of the nervous system in childhood. London: Mac Keith Press; 1992 ,pp 108-202.
19. Campos P, Cruz G, Lizarraga R, Bancalari E, Guillen D, Castañeda Cetal . Electroencephalography in congenital malformations of the central nervous system. Arquivos de neuro-psiquiatria. 1994 ;52:515-22.
20. Limperopoulos C, Majnemer A, Shevell MI, Rosenblatt B, Rohlicek C, Tchervenkov C et al. Neurodevelopmental status of newborns and infants with congenital heart defects before and after open heart surgery. J Pediatr. 2000 ;137:638-45.
21. Menezes AV, MacGregor DL, Buncic JR. Aicardi syndrome: natural history and possible predictors of severity. Pediatr Neurol. 1994; :313-8.
22. Shevell MI, Matthews PM, Scriver CR, Brown RM, Otero LJ, Legris MS et al. Cerebral dysgenesis and lactic acidemia: an MRI/MRS phenotype associated with pyruvate dehydrogenase deficiency. Pediatr Neurol. 1994 ;11:224-9.