

Neurodevelopmental Outcome in A Child With West Syndrome On Multidisciplinary Intervention – A Case Report

SAMIR DALWAI¹, ARADHANA ROHIL², MANISH GARG³, BARKHA CHAWLA⁴, MADHURA JOSHI⁴, SUPRIYA MATHUR⁵

Abstract

West syndrome is a triad of infantile spasms with hypsarrhythmia and developmental regression. It results in a poor neurodevelopmental outcome due to delayed diagnosis and treatment which is further compounded by a delay in referral to multidisciplinary interventions. Our case was a male child with west syndrome who came to us at 3 years of age with neurodevelopmental concerns of global developmental delay with features of autism spectrum disorder. Based on thorough developmental evaluation he was started on an individualised, short term, goal oriented multidisciplinary therapy with physiotherapy, occupational therapy and parental counselling for his neurodevelopmental concerns. As a result improvement was noted in his motor as well as socioemotional skills. Early intervention with multidisciplinary therapy with adherence by motivated parents is essential for a better neurodevelopmental outcome in a case of west syndrome.

Key words: West syndrome, Neurodevelopmental outcome, occupational therapy, parental counselling, physiotherapy.

Introduction:

West syndrome is an age-dependent epileptic encephalopathy with peak age of onset 3-7 months. It is described as a triad of infantile spasms, interictal EEG demonstrating hypsarrhythmias and developmental delay or regression.^{1,2} It contributes to 2% of childhood epilepsies and 13-45% of infantile onset epilepsies.³ It has poor prognosis in terms of both seizure control and psychomotor and cognitive development.^{2,4} Studies in India have highlighted the lack of awareness about the condition leading to delayed diagnosis and treatment, further complicated by delayed referral to multidisciplinary intervention for

improving neuro-developmental outcome.^{3,5} As a result, many children miss out the golden period of their development when the plasticity of brain could be used to improve their neuro-developmental outcomes. This is a case report of a child with West syndrome who received multidisciplinary intervention for developmental concerns contributing to better neuro-developmental outcome.

Case Report:

A male child, third born to a second-degree consanguineous marriage with uneventful antenatal history, born at term by normal vaginal delivery, with birth weight 2.5 kg and cried immediately after birth with no significant postnatal history. The child seemed to be normal till 5 months of age, when he had 2 episodes of generalised tonic-clonic seizures (GTCS) 12 hours apart with developmental regression. He was treated with phenobarbitone initially. He was noted to have tonic spasms during admission and his EEG was suggestive of hypsarrhythmia. Hence, he was started on ACTH that was gradually tapered over 3 months after which there was reduction in spasms which was maintained for a year. Repeat EEG after a

1. Developmental and Behavioural Pediatrician, Director, New Horizons Child Development Centre, Mumbai, India
2. Fellow, New Horizons Child Development Centre, Mumbai, India
3. Associate Director, New Horizons Child Development Centre, Mumbai, India
4. New Horizons Child Development Centre, Mumbai, India
5. Neurologist, New Horizons Child Development Centre, Mumbai, India

Corresponding author: Dr Samir Dalwai, Director, New Horizons Health and Research Foundation, Mumbai, India. Cell no: 7738146666, email: samyrdalwai@gmail.com

Received: 13/08/2021

Accepted: 16/11/2021

year did not record any interictal abnormalities. However subsequently by 2.5 years of age he developed multiple seizure semiology which included GTCS, tonic spasms, focal seizures requiring multiple admissions. His repeat EEG at 3 years of age was suggestive of epileptic encephalopathy with generalized spike and sharp wave discharge of 4 to 5 Hz with intermittent slowing in background activity (low amplitude delta theta waves). He was tried on multiple AED like valproate, levetiracetam, lamotrigine, clonazepam, phenytoin and carbamazepine in different combinations. He was also started on Ketogenic diet but was discontinued due to lack of compliance.

Developmentally, the child had achieved neck holding at 3 months but subsequently parents noted loss of all attained milestones after seizure onset. Parents reported head holding at 1 year, rolling over 15 months, sitting with support 18 months, crawling 24 months, standing with support 24-30 months, reaching for objects after 1 year, no pincer grasp, social smile after 1 year, no vocalization till 2.5 years. Parents reported to a multidisciplinary child development centre, with these concerns at 3 years of age, while he was on antiepileptics. On examination child was found microcephalic (head circumference - 48 cm at 3 years), equinovarus deformity, large ears, convergent squint. Cardiovascular and respiratory system examination was within normal limits, no organomegaly on abdominal examination. Neurological examination revealed hypotonia of trunk and extremities. He showed full range of motion at all joints, muscle strength was grade 4/5 at upper and lower extremities along with brisk deep tendon reflexes and flexor plantar response. Developmental assessment of gross motor functions at 3 years of age revealed he was able to crawl, required assistance to sit upright. Among fine motor skills he was able to grasp objects within reach and mouth but could not transfer objects or grasp objects with his thumb and fingers, needed assistance to drink from a cup and remove socks and could not eat with hands. He could not chew solid food and required assistance during all activities and physiological functions. In the social interaction and communication domain he showed fleeting eye-contact and occasional social smiling. He did not respond to his name. He could not understand gestures or make gestures. He was

unable to indicate his needs or follow commands and had not learnt to speak any meaningful word. Drooling was observed. He was restless, easily distractible, inattentive and hyperactive with tendencies to hit or bite others. He would not interact with other children. He flapped his hands, on getting irritated. He showed vestibular and sensory concerns –discomfort with cutting hair, combing, washing face. The child had poor visual tracking and fixation. Ophthalmological assessment showed refractive error, retinitis and cortico-visual impairment. The child occasionally turned towards the source of sound. Hearing evaluation by BERA was normal.

For psychometric evaluation he was screened for Autism Spectrum Disorder (ASD) using the Childhood Autism Rating Scale (CARS) where he scored 36.5 (met the criteria for severe autism). On Vineland social maturity scale (VSMS), social quotient was 25, indicative of severe sub-normality in social functioning.

Etiological workup included neuroimaging (MRI brain) at 5 months which revealed signal hyperintensities on bilateral frontal white matter suggestive of delayed myelination. He tested positive for anti-CMV IgG antibody at 5 months of age. Subsequent MRI at 2 years of age revealed dilated perivascular (Virchow-Robin or VR) spaces in cortico-medullary junction, subcortical cystic lesions with hyperintensities in anterior temporal region. Repeat testing at 7 years showed light mesial temporal sclerosis with associated structural changes (? dysplasia) in the right anterior temporal lobe. The prominent VR spaces were noted as a normal variant with questionable clinical significance. On the basis of the above findings, he was labelled as symptomatic West syndrome (probably secondary to CMV infection) with global developmental delay with ASD with severe subnormality in social functioning with cortico-visual impairment and normal hearing.

He was advised a multidisciplinary, individualized intervention program with physiotherapy for muscle strengthening and improvement in posture, occupational therapy for fine motor skills, attention span and improving eye contact, motor exercises and parental counselling sessions. Based on the child's assessment, short term goals were formulated for 6 months interval and accordingly

activities were formulated which were also conveyed to the intervening psychologist and parents. Mother also followed the home program, as taught during the sessions. The parental counselling sessions focussed on developing meaningful and purposeful interaction with the child, nonverbal followed by verbal, by persistently including the child in all activities. After 1 year of therapy, child showed significant improvement in motor as well as socio-emotional skills, based on which the programme was

revised with continued parental counselling sessions focussed on developing interaction. The child's GMGCS level had improved from level 4 to level 2 after 1 year. He continued independent follow up with a neurologist and continued to be on multiple antiepileptics with seizures reduced to 1 in 2-3 days with persisting abnormalities on his latest EEG. The domains and interventions focussed have been summarized in table 1 and the details of improvements are described in Figure-1.

Table-I
Interventions

Concerned areas	At start of intervention	1 year post intervention	
	Activities	Concerned areas	Activities
Improve muscle strength in extremities	Sit ups on therapy ball Weight bearing exercises on bolter and therapy ball Kneeling activities with support Weight shifting on bilt board and therapy ball	Attention span without distraction Restlessness	To sit and attend task for 20 min To sit and attend task for 30 min
Improve posture	Pushing activities Pulling activities	Develop perceptual skill	Body parts identification Color recognition Shape recognition
Improve eye contact	Visual tracking using torch Use of colourful toys	Eye hand coordination	Target hitting Ball catch and throw
Improve attention span	Making the child sit with support Giving him bigger peg boards Shifting from one place to another wih assistance	Personal social skills	Response to name call Initiation and completion of task Meaningful play Group play (Later) Behavior modification technique
Developing fine motor skills	Removing beads from strings Clay rolling and molding with assistance	Posture and Tone	Cross-legged sitting Lifting or transferring of objects Weight bearing exercises
Vegetative functions	Oromotor exercises	Gross motor skills	Sitting independently for 15min and more Sit to stand Trunk rotation in sitting position Bilateral coordination
		Develop fine motor skills	Hand functions Pincer grasp Reach out for objects Transfer objects
		Activities of Daily Living	Involve and teach with interaction

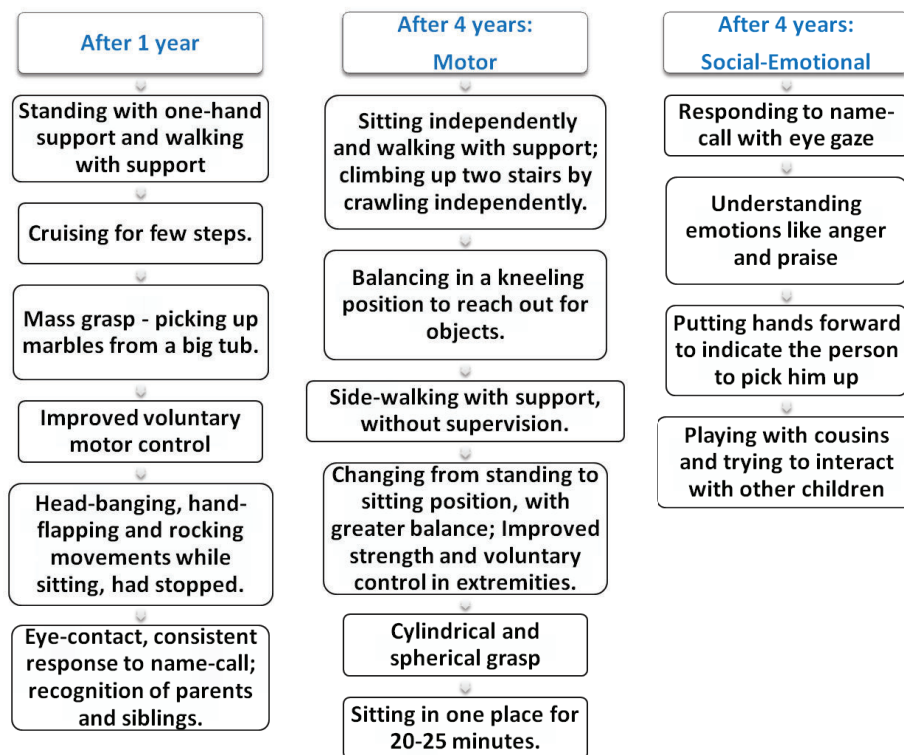


Figure-1: Post-intervention changes in functioning

Discussion:

The purpose of the case report was to highlight the gradual progress of a child with West Syndrome, with coordinated multidisciplinary approach. In West syndrome, the insult to the developing brain during the early developmental stages culminates into psychomotor retardation and cognitive and behavioural developmental disabilities. Poor prognostic factors include early age of onset, poor response to treatment, premorbid neurodevelopmental delay and delay in treatment initiation.² Most of these factors were present in our child. However, he showed significant improvement in functioning after an individualised short-term goal oriented multidisciplinary intervention.

Data from India and developing countries focussing on multidisciplinary rehabilitation therapy and its outcome are limited.^{3,5} However, studies from developed countries focus on rehabilitation of a child with West Syndrome being multilateral, with aims to improve the quality of life, social adaptation and optimization of the cognitive and emotional functioning over and above seizure control.^{2,6} The therapy needs to be long-lasting but with short term goals, adapting to constantly changing psychophysical conditions,

with frequent assessments. A detailed neurological assessment of the child, his behaviour, strengths and limitations is the foundation for developing a comprehensive but individualised plan, instead of showering parents with various training methods. Goals should be tailored around the skills the child possesses. Better results are achieved with measured amounts of exercise conducted systematically and sequentially.⁷ Regular involvement of a child neurologist, developmental pediatrician, speech, occupational and physical therapist, child psychologist, and parental counsellor seems productive, as in our case.⁶ Sensory integration and neurodevelopmental therapy is given keeping in mind the plasticity of the developing brain.^{7,8} A major task during physical rehabilitation is a removal or possibly maximal diminishment of the movement disturbances, as well as gaining control of the kinetic functions like locomotive and manipulative activities for everyday functioning.⁷ Sensory stimulation is equally important for motor learning as it helps in modulating and active participation in environment.^{7,8} In one study, 33.9% had severe outcome and 2/3rd had acceptable quality of life requiring assistance with early diagnosis and multidisciplinary treatment.⁹

Conclusion

The wide gap between medical treatment for seizure control and multidisciplinary intervention needs to be narrowed for a better neurodevelopmental outcome. Early individualized, short term goal oriented intervention and adherence of home program by motivated parents is essential for a better neurodevelopmental outcome in patients with west syndrome.

References

1. Sharma S, Kaushik J.S., Srivastava K, Goswami J.N., Sahu J.K., Vinayak K.P. et al. Association of Child Neurology (AOCN) – Indian Epilepsy Society (IES) Consensus Guidelines for the Diagnosis and Management of West Syndrome. *Indian Pediatr.* 2021;58:54-66.
2. Pavone P, Polizzi A, Marino S.D., Corsello G, Falsaperla R, Mamo S et al. West syndrome : A comprehensive review. *Neurol Sci.* 2020; 41:3547-62.
3. Madaan P, Chand P, Linn K, Wanigasinghe J, LhamuMynak M, Poudel P et al. Management practices for West syndrome in South Asia: A survey study and meta-analysis. *Epilepsia Open.* 2020 ;5:461-74.
4. Gupta J, Sharma S, Mukherjee SB, Jain P, Aneja S. Neuro-Developmental and Epilepsy Outcomes of Children with West Syndrome: A Cross-Sectional Study from North India. *Ann Indian Acad Neurol.* 2020;23:177-81.
5. Vaddi, V.K., Sahu, J.K., Dhawan, S.R. Suthar R, Sankhyan N. Knowledge, Attitude and Practice (KAP) Study of Pediatricians on Infantile Spasms. *Indian J Pediatr.* 2018; 85:836-40.
6. Wheless JW, Gibson PA, Rosheck K L, Hardin M, O'Dell C, Wittemore V et al. Infantile spasms (west syndrome) : update and resources for pediatricians and providers to share with parents. *BMC Pediatr.* 2012; 12:108.
7. Gajewska E, Mojs E, Sobioska M, Samborski W. Developmental and psychokinetic therapy of children suffering from West Syndrome – an overview. *Rocz Akad Med Biyalmist.* 2005;50:297-301.
8. Kunde CA, Ganvir SS. Combined sensory motor approach to enhance participation of a child with west syndrome: a follow-up case study. *Int Phys Med Rehab J.* 2017;2:52-54.
9. Guveli B.T., Cokar O., Dortan N, Benhis G, Demirbilck V, Dervent A. Long term outcomes in patients with West syndrome : An outpatient Clinical Study. *Seizure.* 2015; 25:68-71.