

Case Reports

A 7-year-boy with Recurrent Acute Disseminated Encephalomyelitis: A case report.

NAZNIN AKTER^{1*}, SHEIKH AZIMUL HAQUE², RUMANA ISLAM³, TANIA SAAD⁴

Abstract:

Acute Disseminated Encephalomyelitis (ADEM) is one form of inflammatory demyelinating disorder of central nervous system affecting the children following an idiopathic course of onset and usually monophasic. Recurrent ADEM is a rare entity and will arise a confusion about its diagnosis. There is no definite clinical criteria and treatment protocol for the management of ADEM. Here we report a case of recurrent ADEM where a 6 year old boy presented with recurrent episodes of low grade fever, difficulty in walking, altered sensorium and focal seizure. MRI of brain showed reappearance of demyelinating lesion on the previous site. The gap between first and second episode was six months. After the first attack of ADEM patient was completely recovered both clinically and neuroradiologically with immunotherapy. But after 7 months of disease free remission, patient again developed same features. So we diagnosed the baby as recurrent ADEM based on the consensus criteria of International Pediatric MS study group (IPMSSG).

Key words: ADEM, Recurrent, Magnetic Resonance Imaging of Brain

DOI: <https://doi.org/10.3329/bjch.v46i3.72678>

Introduction:

Acute disseminated encephalomyelitis (ADEM) is an acquired idiopathic inflammatory demyelinating disorder mostly affecting the children. ¹ Usually ADEM in children follows a monophasic course but 10-18% may experience second or multiphasic course. ^{2,3}. ADEM has its well established clinicopathological entity where it may present with features of acute encephalitis like syndrome, or it may present with only myelitic features or in combined encephalomyelitic form. Posinfectious, postexanthem or post vaccinal clinical situation may be triggered by an immune mediated reaction in children or adolescence which

is pathologically characterized by numerous foci of demyelination in brain and spinal cord. ^{4,5}

According to International Pediatric MS Study Group (IPMSSG) to diagnose paediatric ADEM (all are required)

- A first polyfocal, clinical CNS events with presumed inflammatory demyelinating cause.
- Encephalopathy that cannot be explained by fever.
- No new clinical and MRI findings emerge three months or more after the onset
- Brain MRI is abnormal during the acute (three month) phase.
- Typically on brain MRI:
 - Diffuse poorly demarcated large (>1-2 cm) lesions involving predominantly the cerebral white matter.
 - T1 hypointense lesions in the white matter are rare.
 - Deep grey matter lesions (e.g. thalamus or basal ganglion) can be present.

1. Assistant professor of Paediatric Neurology & Development, Dhaka Medical College
2. Professor and head of the department of Paediatric Neurology & Development, Dhaka Medical College
3. Assistant Professor of Paediatric Neurology & Development, Dhaka Medical College
4. Assistant Professor of Paediatric Neurology & Development, Shahid Suhrawardy Medical College

Correspondence: Dr. Naznin Akter, Assistant professor of Paediatric Neurology & Development, Dhaka Medical College. e-mail: nazninrubby73@gmail.com, Mobile: 01712552740

The term encephalopathy was defined by consensus as an alteration of sensorium e.g. stupor, lethargy or behavioural change cannot be explained by fever, systemic illness or postictal symptoms. Recurrence or second events is defined as presence of new symptoms at least three months after the incident illness irrespective of use of immunotherapy and will be associated with new MRI findings consistent with revised radiologic criteria for dissemination in space (DIS).^{1,6}

Case Report:

A 6-year-old boy (Fig 1), only child of non-consanguineous marriage presented with fever, sudden onset of weakness of lower limbs, reduced playfulness, and lethargy. He had no history of bowel or bladder abnormalities. He had a history of cough and cold

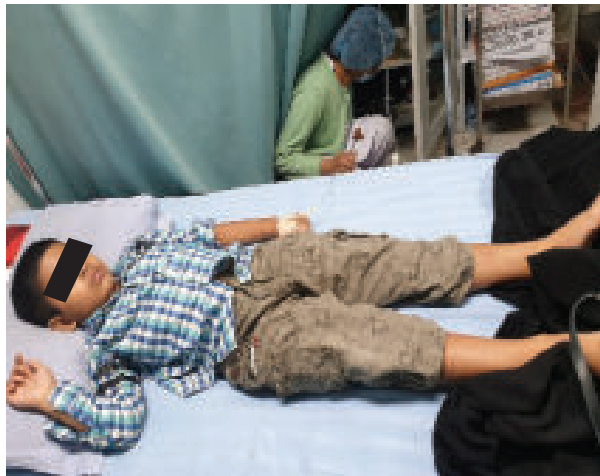

Fig.-1: *The Case*

with low grade fever 3 weeks back. But he was not evaluated by any registered physician during that events. He was developmentally age appropriate, no significant family history, or no history of contact with tubercular patients, no recent vaccination. On examination patient was conscious but in drowsy state with Glasgow coma score 11/15. Anthropometrically well thrived, occipital frontal circumference was on 50th centile. All cranial nerves were intact, no signs of meningeal irritation were present, tone of both lower limbs was normal, power was 3/5 in both lower limbs, deep tendon reflexes were exaggerated (right>left) in both lower limbs. Plantar was bilaterally extensor. Other systemic examinations revealed no abnormalities. On laboratory investigations complete blood picture and biochemical test were within normal limit. Cerebrospinal fluid (CSF) study was within normal range, cell count 4-5/HPF, all were lymphocytes, sugar 55mg/dl, protein 25 mg/dl, no gram stainable or AFB stainable organisms.

MRI of brain with contrast was done which showed focal hyperintense lesion involving periventricular and subcortical white matter region of both cerebral hemispheres in FLAIR and T2 weighted image without meningeal or parenchymal enhancement of gadolinium in contrast MRI. This boy was treated with five doses of injectable methylprednisolone then oral prednisolone for next 6 weeks with gradual tapering. Patient recovered completely within five days of treatment, a repeat MRI of brain was done after three month of initial attack and it was normal. (Fig 2,3,4)

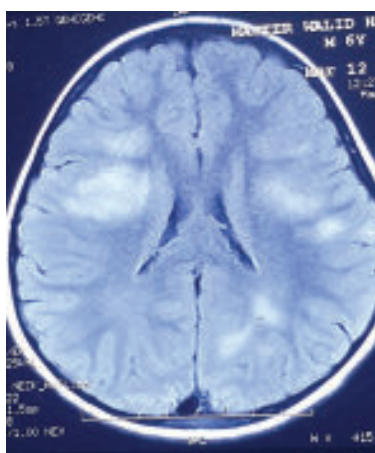


Fig-2: *MRI during first attack, focal hyperintense lesion*

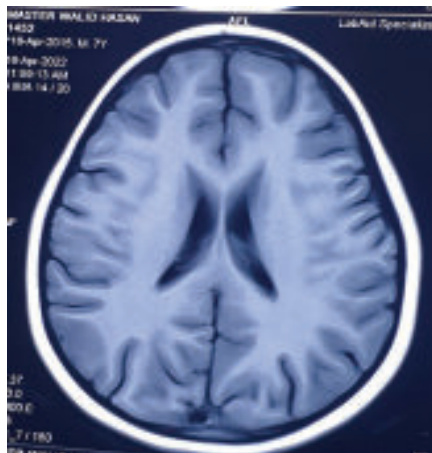


Fig-3: *Repeat normal MRI after 3 months of initial attack*

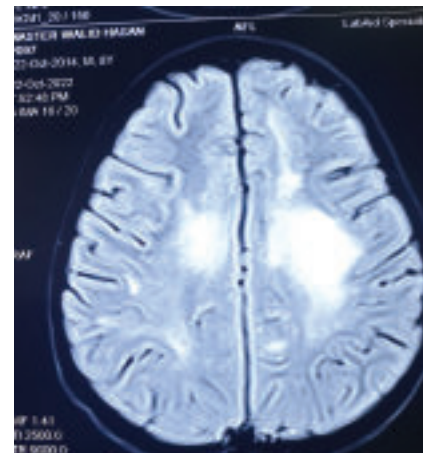


Fig-4: *MRI during recurrence after 7 months of initial attack*

After 7 months of initial attack the patient again was admitted with the complaints of walking difficulty and repeated focal seizure and low grade fever, on examinations patient was drowsy with GCS 12/15, no signs of meningeal irritation was there, all cranial nerves were intact, deep tendon reflexes were exaggerated with bilateral extensor plantar response. CSF study was normal as previous reports, MRI of brain showed hyperintense lesions involving the previous site of brain but lesion size were larger than the previous one. Immunological markers: Antinuclear antibody, anti ds-DNA, lupus anticoagulant all were negative, metabolic screening test were negative, electroencephalography was normal. He was again treated with inj. Methylprednisolone for 5 days with oral prednisolone for further 6 weeks with gradual tapering, patient responded well within 3 days of treatment.

Discussion:

Though ADEM is considered mostly as monophasic illness, subsequent ADEM events has also been reported. Nearly 10% of children with an initial ADEM attack experienced another episode of ADEM, usually within 2–8 years after the initial illness.⁷ Recurrent ADEM and multiphasic ADEM were described for children who experience a subsequent event after an initial ADEM attack. Though recurrent demyelinating events are characteristic of multiple sclerosis (MS), some children may experience self-limited multiphasic demyelinating process which is usually transient.⁷

International Pediatric MS study group (IPMSSG) defined recurrent ADEM as occurrence of new episodes with a recurrence of the first symptoms and signs, 3 or more months after the first ADEM event and after at least 1 month completing therapy, without new central nervous system (CNS) lesion (clinical or neuroimaging).⁸ According to 2007 IPMSSG definitions, multiphasic ADEM is defined as ADEM followed by a new clinical event at least 3 months after the onset of the initial ADEM event and at least 1 month after completing steroid therapy. The subsequent event must include a polysymptomatic presentation including encephalopathy, with neurologic symptoms or signs that differ from the initial event (mental status changes may not differ from the initial event). The brain MRI must show new areas of involvement but also demonstrate complete or partial resolution of those lesions associated with the first ADEM event.⁸ This index case was levelled as

recurrent ADEM, as he presented with the features as his illness both clinically and radiologically.

The distinction between multiphasic and recurrent lies on whether the second ADEM illness involves new brain regions, that is multiphasic or whether the second event is a repetition of the prior illness, that is recurrent. In both, the new event must meet clinical criteria for ADEM, including the presence of encephalopathy. Due to low frequency, the category of 'recurrent ADEM' has been eliminated from 2013 IPMSSG criteria. The definition of multiphasic ADEM is revised and is now defined as two episodes consistent with ADEM separated by three months but not followed by any further events. The second ADEM event can involve either new or a re-emergence of prior neurologic symptoms, signs and MRI findings.^{1,9}

Cases in which more than two events occurred, that raises the suspicion for Multiple sclerosis (MS).³ MS is a chronic demyelinating disease with characteristically relapsing– remitting course. Encephalopathy, seizure, absent oligoclonal band in CSF, and bilateral basal ganglia MRI lesions are suggestive of ADEM.

Other than recurrent demyelinating CNS disease such recurrent CNS symptoms raise the possibilities of other systemic disease with CNS involvement such as collagen vascular disease, recurrent meningoencephalitis or MELAS. In this case other differentials were excluded as autoimmune markers and metabolic screening were normal.

Cohen *et al.* reported a largest case series of recurrent ADEM with 5 patients.¹⁰ The longest intervals of 12 years were found in a patient with three episodes of recurrent ADEM.¹¹ Another study regarding clinical and neuroimaging features of recurrent ADEM carried out by Kariyawasam *et al* where he found 25% of relapse among the cohort and the infratentorial radiological involvement at presentation have higher frequency of relapse.¹² Chatterjee *et al* also reported a case of recurrent ADEM with favorable outcome in a three year old boy with prompt treatment with immunotherapy.¹³ Though there is no specific clinical or radiological features which may predict relapse following a first episode of ADEM but strong clinical suspicion early initiation of treatment is utmost important for better outcome, regular follow up is another priority to exclude the diagnosis of MS.^{3,13}

Conclusion

Though rare, recurrent event of ADEM may also occur and warrant further investigations to rule out other differentials. Subsequent long term clinical and neuroradiological follow up is also necessary.

References:

1. Krupp LB, Tardieu M, Amato MP, Banwell B, Chitnis T, Dale RC et al. International Pediatric Multiple Sclerosis Study Group. International Pediatric Multiple Sclerosis Study Group criteria for pediatric multiple sclerosis and immune mediated central nervous system demyelinating disorders: revisions to the 2007 definitions. *Mult Scler*. 2013, Sep; 19:1261-7.
2. Incecik F, Herguner MO, Altanbasak S. Acute disseminated encephalomyelitis: An evaluation of 15 cases in childhood. *Turk J Pediatr*. 2013; 55:253-9.
3. Mikaeloff Y, Cardade G, Husson B, Suissa S, Tardieu M. Neuropediatric KIDSEP studygroup of the French Neuropediatric society. Acute disseminated encephalomyelitis cohort study: Prognostic factors for relapse. *Eur J Paediatr Neurol*. 2007; 11: 90-5.
4. Victor M, Ropper AH. Adams and Victor's Principles of Neurology. 7TH edition. McGraw-Hill. New York. 2001:954-982.
5. Mitsunori M. Recurrent ADEM or MS? Editorial. *Internal Medicine* 2004; 43 (8):647-8.
6. Polman CH, Reingold SC, Banwell B, Clanet M, Cohen JA, Flippi M et al. Diagnostic criteria for multiple sclerosis: 2010 revisions to the McDonald criteria. *Ann Neurol*. 2011.Feb;69(2): 292-302.
7. Tenembaum S, Chamoles N, Fejerman N. Acute disseminated encephalomyelitis: a long-term follow-up study of 84 pediatric patients. *Neurology* 2002 Oct 22; 59(8):1224-31.
8. Krupp LB, Banwell B, Tenembaum S. Consensus definitions proposed for pediatric multiple sclerosis and related disorders. *Neurology* 2007 Apr 17;68(16 suppl 2):S7-12.
9. Neuteboom RF, Boon M, Catsman Berrevoets CE. Prognostic factors after a first attack of inflammatory CNS demyelination in children. *Neurology* 2008; 71:967-73.
10. Cohen O, Steiner-Birmanns B, Biran I, Abramsky O, Honigman S, Steiner I. Recurrence of acute disseminated encephalomyelitis at the previously affected brain site. *Archives of Neurology*. 2001 May 1; 58(5):797-801.
11. Ohtake T, Hirai S. Recurrence of acute disseminated encephalomyelitis after a 12-year symptom-free interval. *Internal medicine* 2004; 43(8):746-9.
12. Kariyawasam S, Singh RR, Gadian J, Lumbsden DE, Lin J-P, Siddiqui A et al. Clinical and radiologic features of recurrent demyelination following acute disseminated encephalomyelitis (ADEM). *Multiple Sclerosis and Related Disorders* 2015 September; 4 (5): 451-6.
13. Chatterjee A, Datta S. Recurrent acute disseminated encephalomyelitis: A favourable outcome among recurrent brain diseases in pediatric patient. *Journal of Pediatric Neurosciences* 2016 July; 11(3): 241-3.