

Endodontic-Periodontal Interrelationship, a Phenomenon Dealt with Dilemma: a Review

F Rashid¹, CM Jan², MAA Polan³, NA Nomann⁴, AJ Rashid⁵, MM Zaki⁶

Abstract

The term "perio-endo" lesion has been established to describe any lesion caused by any inflammatory product found in varying degrees in both the periodontium and the pulpal tissues and this inter-relationship between periodontal and pulpal disease was first described by Simring and Goldberg in 1964. As the pulpal and periodontal tissues have close embryonic, anatomical and functional inter-relationship; so, simultaneous existence of pulpal problems and inflammatory periodontal disease can be found frequently. This certainly can complicate diagnosis and also influencing outcome of treatment planning. A perio-endo lesion can have a varied pathogenesis which ranges from quite simple to relatively most complex one, thus coming to a definitive diagnosis a hard judged one. Having a thorough knowledge over these disease processes plays a key role in coming to the correct diagnosis and also subsequent treatment planning. This certainly can be achieved by careful history taking, a thorough intra and extra oral examination and the use of modern day special test apparatuses. Radiographic evaluations can also aid in clarifying the nature of the problem, even modern day Radio-Visio Graph or, RVG can also be a great tool that can come into aid. The prognosis and treatment of each endo-perio disease type varies a lot. Stating so, primary periodontal disease with secondary endodontic involvement and true combined endodontic-periodontal diseases require both endodontic and periodontal therapies along with proper medication & oral hygiene maintenance. The prognosis of each case depends on the severity of periodontal disease and the response to periodontal treatment, while the treatment of affected tooth/teeth with endodontic involvement also requires the same. This review paper is focused on enabling the operator to construct a suitable treatment plan where unnecessary, prolonged or even detrimental treatment is avoided, thus avoiding breaking of Hippocratic Oath taken by a dental surgeon in his/her maiden practice life.

Key Words: Endo-perio lesion, pulp, periodontal disease, diagnosis, treatment.

Introduction

A single lesion may present signs of both endodontic and periodontal involvement, so the differential diagnosis of this disease can sometimes be difficult and complex and it is of vital importance to make a correct diagnosis for providing an appropriate treatment plan.

Diagnosis and prognosis of a tooth affected with endodontic and periodontal lesion poses a great challenge to the clinician also. Many contributing factors such as bacteria, fungi, and viruses as well as various contributing factors such as trauma, root resorptions, perforations, and developmental malformations play a considerable role in the onset and progression of such lesions. The endo-perio lesion is a condition characterized by the association of periodontal and pulpal disease in the same dental element. The relationship between periodontal and pulpal disease was first described by Simring and Goldberg in 1964¹. Since then, the term 'perio-endo lesion' is being used to describe lesions due to inflammatory products found in varying degrees in both periodontium and pulpal tissues.

Pulp of a tooth and its periodontium maintain a close interrelationship. The communication between these two structures is observed just at the beginning of the odontogenesis, as they are derived from the same mesodermic source, being reduced as the root and their structures are formed². The apical foramen acts as the main access route between the pulp and the periodontium, with the participation of all root canal systems: accessory, lateral, and secondary canals as well as the dentinal tubules through which the microbes and its products usually contaminate the medium.

1. Dr. Fahmida Rashid, BDS, PhD (Japan)
Associate Professor and Head,
Department of Oral Pathology, Periodontology & Oral Medicine
MARKS Dental College & Hospital, Dhaka
2. Dr. Chowdhury Moin Jan, BDS, PhD (Japan)
Associate Professor and Head,
Department of Conservative Dentistry & Endodontics
MARKS Dental College & Hospital, Dhaka
3. Dr. Md. Ali Akbor Polan, BDS, MPH, Doctoral Fellow
Division of Clinical Cariology & Endodontology
Health Sciences University of Hokkaido, Japan
4. Dr. Nahid Al Nomann, BDS, Doctoral Fellow
Division of Clinical Cariology & Endodontology
Health Sciences University of Hokkaido, Japan
5. Dr. Ahmed Jishan Rashid, BDS
Dental Surgeon, Hiroshima Dental Clinic, Dhaka
6. Dr. Md. Mahbub Zaki, BDS, MCPS
Consultant, BSMMU, Dhaka

Address of Correspondence:

Dr. Fahmida Rashid, BDS, PhD (Japan)
Associate Professor and Head,
Department of Oral Pathology, Periodontology & Oral Medicine
MARKS Dental College & Hospital, Dhaka
E-mail: cmoinjan@yahoo.com

It is established that the main cause of the periodontal lesions is the presence of the bacterial plaque, formed by aerobic and anaerobic microorganisms which may originate from infectious process. Pulpal exposures, periodontitis and carious lesions are of significant importance in the development of a periodontal-endodontic lesion. If the lesions are not well treated and the canals are not disinfected correctly and sealed, they will house bacterial necrotic rests, which account for the progression of the lesion or even for the endodontic reinfection³.

Other form of the inter-relationship that can occur is because of the iatrogenic perforations due to either rotary instrumentation or improper handling of the endodontic instruments⁴. Vertical root fractures and cracks may serve as a “channel/pathway” for pulp contamination. If this periodontium shows a previous inflammation, it may have the dissemination of the inflammation which can result in pulp necrosis⁵. Rubach and Mitchell⁶ opined that the periodontal disease may affect the pulp health when the accessory canal exposure occurs, allowing the periodonto-pathogenic bacterias to cause inflammatory reactions followed by pulp necrosis. Lindhe⁷ also reported that bacterial infiltrates of the inflammatory process may reach the pulp when there is exposure of accessory canal, through apical foramens and canaliculi of the furcation area. Adriaens *et al.*⁸ demonstrated that bacterias coming from the periodontal pockets have the capacity of crossing the root canals towards the pulp, suggesting that the dentinal tubules may serve as a reservoir for these microorganisms and that a recolonization of the treated root surface may occur.

It is highlighted that the root planning and scaling may determine the rupture of the vessels and destruction of the neurovascular bundle in the lateral canals, provoking the reduction of the blood support and consequently leading to pulp alterations. Langeland *et al.*⁹ affirmed that the pulp would only be affected by the periodontal disease if the apical foramen was involved. A histological evaluation performed by Czarnecki and Schilder¹⁰, comparing the pulp of teeth with periodontal involvement with that of healthy teeth, observed that regardless of the severity of the periodontal disease the pulp of all teeth was histologically normal. These authors concluded that the pulp alterations occur only in teeth with deep caries and extensive restorations, that is, these evidences pointed out that the periodontal disease alone does not affect the pulp.

The aim of this literature review was to search for the information on the diagnosis and treatment of the periodontal-endodontic lesions, which are of extreme importance in Dentistry because of its severity and involvement in many patients.

Inter-relationship between pulpal & periodontal tissues

The effect of periodontal inflammation on dental pulp is controversial and conflicting¹¹⁻¹⁴. It has been found that, periodontal disease has no effect on the pulp before it involves the apex of the tooth¹⁴. On the other hand, the effect of periodontal disease on the pulp is degenerative in nature in addition to the direct inflammatory sequelae^{15,16}. Dental pulp and periodontium have close embryonic, anatomic and functional inter-relationships¹⁷. They all are ectomesenchymal in origin, the cells from which proliferate to form dental papilla and follicle, which are the precursors of the pulp and periodontium respectively. They are separated by the formation and development of tooth bud from the overlying ectoderm into enamel and dentine¹⁸. The apical foramen decreases in size as the proliferation of the Sheath of Hertwig continues. It remains patent and serves as the communication for vascular and nervous innervations. As the root of the tooth develops, ectomesenchymal channels get incorporated, either due to dentine formation around existing blood vessels or break the continuity of the Sheath of Hertwig, to become accessory or lateral canals¹⁹.

The majority of accessory canals are found in the apical part of the root and lateral canals in the molar furcation regions²⁰. Tubular communication between the pulp & periodontium may occur when dentinal tubules become exposed to the periodontium by the absence of overlying cementum. These are the pathways that may provide a means by which pathological agents pass between the pulp and periodontium, thereby creating the perio-endo lesion¹⁹. Besides, noxious elements of pulpal origin including inflammatory mediators and bacterial byproducts may leach out through the apex, lateral and accessory canals, and dentinal tubules to trigger an inflammatory response in the periodontium including an early expression of antigen presentation²¹. Released byproducts are from living bacterial strains including spirochetes as well as of non-living pathogen²²⁻²⁴. Fungi and viruses are also implicated^{25,26}.

The organisms most often involved in an endo-perio lesion are probably bacteroides, fusobacteria, eubacteria, spirochetes, wolinelias, selenomonas, campylobacter, and pepto-streptococci. Important qualities of cross-infecting organisms may be the ability to survive in highly reduced environments and motility. Precautions should be taken to prevent in vivo seeding of such micro-organisms, particularly in compromised teeth and hosts.

Etiological factors

1. Live pathogens: *Bacteria
 - *Fungi
 - *Viruses
2. Intrinsic agents: *Cholesterol,
 - *Russell bodies
 - *Rushton hyaline bodies
 - *Charcot-Leyden crystals.
3. Contributing factors: *Poor endodontic treatment and perforation
 - *Poor restorations
 - *Resorptions

Bacteriology

Bacteria plays an important role both endodontic & periodontal disease. Periapical tissues involve following bacterial invasion of the pulp leading to partial or, total pulpal necrosis. Rupf et al. studied the profiles of periodontal pathogens in pulpal and periodontal diseases associated with the same tooth²⁷. These pathogens were found in all endodontic samples and the same proteolytic pathogens were found in teeth with chronic apical periodontitis and chronic (adult) periodontitis. Spirochetes especially *T. denticola* are another type of microorganisms associated with both endodontic and periodontal diseases.^{28,29}

Fungi (Yeast)

The majority of the recovered fungi were *Candida albicans*. Other species such as *Candida glabrata*, *Candida guilliermondii*, and *Candida inconspicua* and *Rodotorula mucilaginosa* were also detected²⁸. Fungi may gain access to the root canal from the oral cavity as a result of poor asepsis during operative treatment procedure. The presence of fungi in the root canals directly associates with their presence in saliva.

Viruses

In patients with periodontal disease-herpes simplex, human cytomegalovirus and Epstein - Barr virus (EBV) were detected in periodontal tissues. In endodontics, the presence of viruses in the dental pulp was first reported in a patient with AIDS (Glick et. al. 1989). DNA of HIV virus has also been detected in periradicular lesions. However, it has not been established that HIV virus can directly cause pulpal diseases³⁰.

Contributing factors

*Poor endodontic treatment - it is often found associated with periradicular inflammation. Poor endodontic treatment also allows canal re-infection, which may often lead to treatment failure.

*Poor restorations - Coronal leakage is an important cause of failure of endodontic treatment. Madison and Wilcox (1988) found that exposure of root canals to the oral environment allowed coronal leakage to occur, and in some cases along the whole length of the root canal³¹. Ray and Trope (1995) reported that defective restorations and adequate root fillings had a higher incidence of failures than teeth with inadequate root fillings and adequate restorations³².

*Resorption - Root resorption due to pathological process resulting in a loss of dentine, cementum and/or bone. It may be initiated in the periodontium and affects initially the external surfaces of the tooth or it may start within the pulp space affecting primarily the internal dentine surfaces (internal resorption).

*Perforations - Root perforation causes communications between the root canal systems and either periradicular tissues or the oral cavity may often reduce the prognosis of treatment.

Signs & Symptoms

*Swelling and bleeding of the gum indicating gingivitis with deep pockets and suppuration.

*Tenderness to percussion.

*Radiograph showing angular bone loss.

*Tooth mobility and sinus formation.

Effect of periodontal disease on the pulp

*Periodontal disease may involve pulp through apical foramen, lateral and accessory canals, dentinal tubules or iatrogenic errors.

*Chemical irritants and medicaments irritate pulpal tissue.

Classification of Endo-Perio lesions

There are four types of perio-endo lesions and they are classified due to their pathogenesis. The classification runs as follows:

1. Endodontic lesions: an inflammatory process in the periodontal tissues resulting from noxious agents present in the root canal system of the tooth.

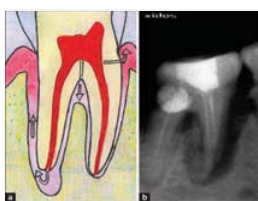

Figure 1: Diagrammatic & Radiographic Representation of Endodontic lesion

2. Periodontal lesions: an inflammatory process in the pulpal tissues resulting from accumulation of dental plaque on the external root surfaces.

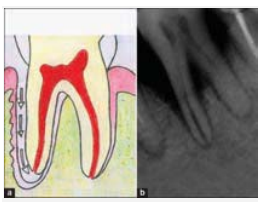


Figure 2: Diagrammatic & Radiographic Representation of Periodontic lesion

3. True-combined lesions: both an endodontic and periodontal lesion developing independently and progressing concurrently which meet and merge at a point along the root surface.

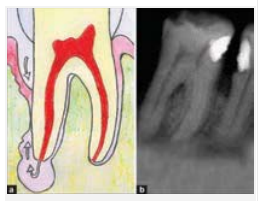


Figure 3: Diagrammatic & Radiographic Representation of True-combined lesion

4. Iatrogenic lesions: usually endodontic lesions are produced as a result of treatment modalities.

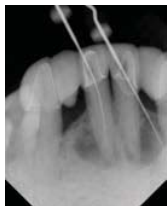

Figure 4: Radiographic Representation of Iatrogenic lesions

Pathogenesis

A. Endodontic lesions: When the pulp becomes inflamed/infected, it elicits an inflammatory response of the periodontal ligament at the apical foramen and/or adjacent to openings of accessory canals. These inflammatory lesions cause localized edema and a resulting increase in intra-pulpal pressure and cell death¹⁴. Increased damage associated with an inflammatory exudates cause local collapse of the venous part of the local microvasculature. This causes local tissue hypoxia and anoxia resulting in localized necrosis, the chemical mediators of which cause further localized edema, completing the cycle³³. Carious lesions or any direct exposure to the oral cavity of dentine or pulp may ingress bacteria to contaminate an otherwise sterile lesion. Endodontic lesions are most frequently initiated and sustained by the apical foramen, followed by accessory and lateral canals, and most infrequently by dentinal tubules. A periapical lesion may perforate the cortical bone close to the apex, elevating the periosteum and overlying soft tissues, and drain into the gingival sulcus³⁴, and form pseudo pockets that simulate periodontal disease without necessarily causing permanent damage of the cementum and its fibres¹⁹. If the acute periapical drainage becomes chronic and drainage through the gingival sulcus continues a downgrowth of epithelium along the tract can result in a periodontal pocket in which secondary periodontal disease may complicate the lesion³⁵. Simon *et. al.*³⁶ further categorized endodontic lesions into two subcategories:

1. Primary endodontic lesions-when a sinus tract has formed to establish drainage.

2. Primary endodontic lesions with secondary periodontal involvement-when plaque formation is occurring in the sinus tract with progression to periodontitis and associated calculus formation.

B. Periodontal lesions: Plaque and calculus usually initiate a periodontal lesion. Inflammatory mediators cause destruction of gingival connective tissue, periodontal ligament and alveolar bone. Alteration of the root surface occurs by loss of the outer cementoblast layer and results in shallow resorptive lesions of cementum. Endotoxins produced by plaque bacteria also have an irritant effect on overlying soft tissue, preventing repair³⁷ Although periodontal disease has been shown to have a cumulative damaging effect on the pulp tissue, total disintegration of the pulp will only be a certainty if bacterial plaque involves the main apical foramina, compromising the vascular supply^{19,34}.

The presence of an intact cementum layer is important for the protection of the pulp from pathogenic agents produced by the plaque bacteria³⁴. Therefore, the exposure of dentinal tubules by the removal of cementum due to rigorous scaling and root-planning for the treatment of periodontal disease will allow bacterial invasion of the tubules. This would increase the likelihood of cumulative damage to the pulp¹⁹. Results from microbiological and immunological studies support the suggestion that the source of endodontic infection in perio-endo lesions with periodontal origin is the periodontal pocket bacteria³⁸. Categorization of periodontal lesions into two subcategories, are as follows:

1. Primary periodontal lesions-when there is a progression of periodontal lesion to involve the apex of tooth while the pulp is vital (there may be some pulpal degenerative changes).
2. Primary periodontal lesions with secondary endodontic involvement-when a periodontal disease causes a resultant pulpal necrosis as it progresses apically.

C. Combined lesions: The pathogenesis of a true-combined lesion is identical to the pathogenesis of primary endodontic and periodontal lesions. These lesions are often indistinguishable from an advanced primary endodontic lesion with secondary periodontal involvement and/or a primary periodontal lesion with secondary endodontic involvement³⁷. True combined endodontic-periodontal disease occurs with less frequency. It is formed when a coronally progressing endodontic disease joins an infected periodontal pocket progressing apically^{11,36}. The radiographic appearance of combined endodontic-periodontal disease may be similar to that of a vertically fractured tooth. A fracture that has invaded the pulp space, with resultant necrosis, may also be labeled a true combined lesion and yet not be amenable to successful treatment.

D. Iatrogenic lesions: These include root perforations, overfilling of root canals, coronal leakage, trauma, chemical induced root resorption, intra-canal medicaments and vertical root fractures³⁷. Root perforations are undesirable clinical complications that may lead to periodontal lesions. When root perforation occurs, communications between the root canal system and either peri-radicular tissues or the oral cavity may often reduce the prognosis of treatment. Root perforations may result from extensive carious lesions, resorption, or from operator error occurring during root canal instrumentation or post preparation^{39,40}.

At the site of perforation, an inflammatory reaction in periodontal ligament produces a degradation of surrounding tissues and formation of a lesion which can progress as a conventional primary endodontic lesion³⁴.

The overfilling of root canals produces a lesion in exactly the same way as the lesion originating adjacent to the apical foramen rather than the lateral wall or pulpal floor. Coronal leakage is the leakage of bacterial elements from the oral environment along the restoration's margin to the endodontic filling. Studies have indicated that this factor may be an important cause of endodontic treatment failure^{41,42}. Root canals may be recontaminated by microorganisms due to delay in placement of a coronal restoration and fracture of the coronal restoration and/or the tooth⁴¹.

Dental injuries or trauma may take on many shapes but generally can be classified as enamel fractures, crown fractures without pulp involvement, crown fractures with pulp involvement, crown-root fracture, root fracture, luxation, and avulsion⁴³. Treatment of traumatic dental injuries varies depending on the type of injury and it will determine pulpal and periodontal ligament healing prognosis.

The most common cause of vertical root fracture in endodontically treated teeth is the excessive force used during lateral condensation of gutta-percha. Widening of the periodontal ligament along one or both sides of the root, or bone loss in solitary tooth are the major radiographic findings. Mild pain or discomfort and swelling are the major clinical symptoms, and solitary pocket around one aspect of the suspected tooth is the major clinical sign. Certain chemicals used in dentistry have the potential to cause root resorption as for example intracoronary bleaching agents like 30-35% hydrogen peroxide (H₂O₂)⁴⁴. Chemicals may diffuse through the dentinal tubules and when combined with heat, they are likely to cause necrosis of the cementum, inflammation of the periodontal ligament, and subsequently root resorption⁴⁵. Replacement resorption or ankylosis occurs following extensive necrosis of the periodontal ligament with formation of bone onto a denuded area of the root surface.

This condition is most often seen as a complication of luxation injuries, especially in avulsed teeth that have been out of their sockets in dry conditions for several hours. Certain periodontal procedures have been reported to induce replacement root resorption. The potential for replacement resorption was also associated with periodontal wound healing. Granulation tissue derived from bone or gingival connective tissue may induce root resorption and ankylosis. Vertical root fractures are most often caused when a tooth, often weakened due to undermining by caries, previous restorative treatment or a non-vital pulp becomes traumatised³⁷.

Leaching of the root canal contents or bacterial contamination of the fracture line may cause an inflammatory lesion in periodontal tissues³⁴. The continuing lesion mimics those due to root perforation or over-filling of root canals.

Treatment Regimen

The important objectives of treatment of a tooth that has both periodontal and pulpal disorders are elimination of the existing cause, restoring tooth function to maximum efficiency and creation of an esthetic appearance^{46,47}. The treatment of endo-perio lesions can be of emergency treatment and local treatment.

The emergency includes control of pain and infection both. In case of acute pulpitis with severe pain, the emergency treatment like pulpectomy is advised and if pain is mild due to periodontal origin analgesics are preferred. Infection control is achieved mainly by the use of antibiotics such as Penicillin and Erythromycin for endodontic origin⁴⁸ and chemotherapeutic agents for management of lesions of periodontal origin. Tetracyclines are effective against *A. actinomycetem comitans* and Metronidazole (750 – 1000 mg / day / 2 weeks) is effective against anaerobes, *Porphyromonas gingivalis*, *Prevotella intermedia*. The locally delivered antimicrobials are as follows:

- a) Tetracycline – containing fibers (Non-resorbable fibers, diameter 0.5 mm containing tetracycline-12.7 mg / 9 inches. It sustains tetracycline exceeding 1300 µg/ml for 10 days).
- b) Sub gingival delivery of Doxycycline, (Biodegradable) Atridox incorporates the antibiotic doxycycline (10%) in a syringe-able gel system.
- c) Sub gingival delivery system for Minocycline, 2% minocycline Hcl is available as a syringe-able gel suspension system.
- d) Sub gingival delivery of Metronidazole, 25% dental gel is applied in the periodontal pocket, where it is liquidized by body heat and then hardens again forming crystal in contact with H₂O.

The local delivery of antiseptic agents is mainly by the use of a resorbable, small chip composed of a biodegradable hydrolyzed gelatin matrix cross linked with glutaraldehyde, glysine and H₂O into which 2.5 mg chlorhexidine gluconate is incorporated to maintain drug concentration in gingival crevicular fluid greater than 100 µg / ml for 7 days.

Treatment of primary endodontic lesions: According to Simon et. al. root canal therapy should be performed with multiple appointments. Healing is rapid and is usually accomplished within 3-6 months⁴⁹ (Figure: 5-7).

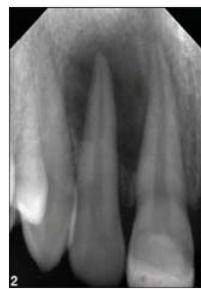

Figure 5: Primary endodontic lesion treated endodontically

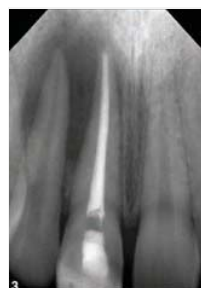

Figure 6: Primary endodontic lesion treated endodontically

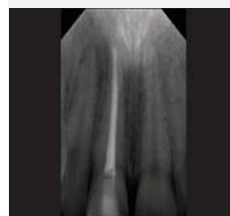

Figure 7: Complete healing after 6 months

Treatment of primary endodontic lesion with secondary periodontal involvement: It necessitates both endodontic and periodontal treatment as there is pulpal involvement and presence of a periodontal pocket⁵⁰.

Treatment of primary periodontal lesion: It needs a sequence of treatment. If periodontitis progresses and periodontal pocket deepens, with continuous loss of bony attachment, surgical pocket eradication procedures are indicated.

Treatment of primary periodontal lesion with secondary endodontic involvement: It is managed as follows, if a tooth does not respond to periodontal therapy alone the possible presence of a necrotic pulp may be suspected then endodontic therapy must be done to support the periodontal therapy along with osseous surgery if any bony defect is present⁵¹.

Treatment of true combined lesion: It requires periodontal therapy be performed during or, an endodontic treatment⁵¹. According to Solomon et. al. using calcium hydroxide in endo-perio cases; inhibits resorption and favors repair by inhibiting periodontal contamination⁵².

Alternative for endo-perio lesion management are resective approaches / anatomical redesigning like Root amputation, Tooth resection and Bicuspidization⁵³.

Root amputation is done in advanced marginal periodontitis if left untreated and in cases of close root proximity the disto-buccal root of the maxillary first molar and the mesiobuccal root of the second molar often tend to flare towards each other. Selective root removal allows the re-establishment of a proper embrasure area. Tooth resection is the treatment of choice in deep furcation involvements. Bicuspidization is done when there is a gross perforation in the furcation and close root proximity.

Various regenerative approaches for the management of en-do-perio lesions which are more aggressive & surgical in nature includes the use of Tricalcium phosphate graft (TCP), Platelet Rich Plasma (PRP) and Guided tissue regeneration (GTR)^{53,54}. Albee and Morrison noticed when Tricalcium phosphate graft (TCP) is placed in close to vital bone, ceramic matrix of the material serves as a carcass for bone formation⁵⁴. Platelet Rich Plasma (PRP) is a rich source of growth factors and is effective in inducing tissue repair and regeneration⁵⁵. Guided tissue regeneration (GTR) barrier prevents contact of connective tissue with the osseous walls of the defect, protecting the underlying blood clot and stabilizing the wound⁵⁶.

Having a thorough knowledge of the disease processes is essential for the correct treatment planning. The endodontic treatment can be completed before periodontal treatment provided when there is no communication between the disease processes. When there is a communication between the lesions of the two diseases the use of non-toxic therapeutic medicaments is essential to destroy bacteria and to help encourage tissue repair. The prognosis of primary periodontal disease with secondary endodontic involvement and true combined diseases depends primarily upon severity of the periodontal disease and periodontal tissue treatment.

Treatment of iatrogenic lesions: Although the first priority is to close the iatrogenic communication, the aim is to produce a seal. Root perforations are treated according to their etiology. The outcome of the treatment of root perforations depends on the size, location, time of diagnosis and treatment, degree of periodontal damage as well as the sealing ability and biocompatibility of the sealer. It has been recognized that the success of the treatment depends mainly on immediate sealing of the perforation and appropriate infection control. Several materials such as MTA (Mineral Tri-oxide aggregate), Cavit, IRM (Interim Restorative material), Glass ionomer cements (GIC), composites, and amalgam have been recommended to seal root perforations^{57,58,59}.

Palatal perforations are difficult to manage, even surgically & frequently leads to extraction. Lesions attributable to over-filling of root canals and intra-canal medicaments can usually be resolved by peri-radicular surgery, probably accompanied by a retrograde root filling.

Teeth with lesions caused by vertical root fractures have a hopeless prognosis and should be extracted.

Conclusion

In a nut shell it can be said that, endodontic-periodontal lesions often presents a diagnostic and treatment dilemma. Based on the literature review, it can be concluded that the dentist should know to differentiate the origins of the periodontal-endodontic lesions, including all the routes of communication between the pulp and the periodontium which acts as possible "bridges" for changing the microorganisms, therefore enabling the dissemination of the infection from one site to another. Through this knowledge, the dentist will achieve the correct diagnosis and adequate treatment, resulting in greater chances of obtaining the success in the treatment of the periodontal-endodontic lesions.

Once, periodontal disease progresses to involve pulp, careful diagnosis will enable a clinician to determine the treatment plan and subsequent prognosis. Those teeth that appear to have periodontal problem of endodontic origin have an excellent prognosis. Some cases may require only endodontic therapy or periodontal treatment and other cases may require a combined approach. If prognosis is questionable/poor extraction of affected tooth may be indicated. The treatment rendered and subsequent success or failure of treatment is directly dependent on making accurate diagnosis of lesion.

References

1. Simring M, Goldberg M. The pulpal pocket approach: retrograde periodontitis. *J Periodontol* 1964; 35: 22-48.
2. Carranza FA, Newman MG, Takei HH, Klokkevold PR. *Periodontia clínica*. 10. ed. São Paulo: Saunders Elsevier; 2007.
3. Adriaens PA, De Boever JA, Loesche WJ. Bacterial invasion in root cementum and radicular dentin of periodontally diseased teeth in humans. A reservoir of periodontopathic bacteria. *J Periodontol*. 1988; 59:222-30.
4. Loesche WJ, Bretz WA, Kerschensteiner D, Stoll J, Socransky SS, Hujuel P et al. Development of a diagnostic test for anaerobic periodontal infections based on plaquehydrolysis of benzoyl – DL-arginine – aphthylamide. *J Clin Microbiol*. 1990 Jul; 28(7):1551-9.
5. Mata AC, Toledo B, Sampaio J. Prevalência de canais cavo inter-radulares. *Revista Brasileira de Cirurgia e Periodontia*. 2003; 1(2):107-21.
6. Harrington GW, Steiner DR, Ammons Jr. WF. Controvérsias em periodontia-endodontia. *J Periodontol* 2000. 2002; 30:123-30.

6. Rubach WC, Mitchell DF. Periodontal disease, accessory canals and pulp pathosis. *J Periodontol* 1965;36:34-8.
7. Lindhe J. Tratado de periodontia clínica e implantologia oral. 3. ed. Rio de Janeiro: Guanabara Koogan; 1999.
8. Adriaens PA, De Boever JA, Loesche WJ. Bacterial invasion in root cementum and radicular dentin of periodontally diseased teeth in humans.
9. Langeland K, Rodrigues H, Dowden W. Periodontal disease, bacteria and pulp histopathology. *Oral Surg Med Oral Pathol* 1974 Feb; 37(2):257-70.
10. Czarnecki RT, Schilder H. A histologic evaluation of the human pulp in teeth with varying degrees of periodontal disease. *J Endod* 1979; 5: 242-53.
11. Seltzer S, Bender IB, Ziontz M. The interrelationship of pulp and periodontal disease. *Oral Surg Oral Med Oral Pathol* 1963; 16(12): 1474-90.
12. Mazur B, Massler M. Influence of periodontal disease of the dental pulp. *Oral Surg Oral Med Oral Pathol* 1964; 17(5): 592-603.
13. Bender IB, Seltzer S. The effect of periodontal disease on the pulp. *Oral Surg Oral Med Oral Pathol* 1972; 33(3): 458-74.
14. Czarnecki RT, Schilder H. A histological evaluation of the human pulp in teeth with varying degrees of periodontal disease. *J Endod* 1979; 5(8): 242-53.
15. Langeland K, Rodrigues H, Dowden W. Periodontal disease, bacteria, and pulpal histopathology. *Oral Surg Oral Med Oral Pathol* 1974; 37(2): 257-70.
16. Mandi FA. Histological study of the pulp changes caused by periodontal disease. *International Endodontic Journal* 1972; 6(4): 80-3.
17. Mandel E, Machtou P, Torabinejad M. Clinical diagnosis and treatment of endodontic and periodontal lesions. *Quintessence Int* 1993; 24(2): 135-9.
18. Ten Cate A R. Oral histology, development, structure and function. 4th ed. Philadelphia: Mosby; 1994.
19. Solomon C, Chalfin H, Kellert M, Weseley P. The endodontic-periodontal lesion: a rational approach to treatment. *J Am Dent Assoc* 1995; 126(4): 473-9.
20. Whyman RA. Endodontic-periodontic lesions. Part I: Prevalence, aetiology, and diagnosis. *N Z Dent J* 1988; 84(377): 74-7.
21. Okiji T, Kawashima N, Kosaka T, Kobayashi C, Suda H. Distribution of Ia antigen-expressing nonlymphoid cells in various stages of induced periapical lesions in rat molars. *J Endod* 1994; 20(1): 27-31.
22. Haapasalo M, Ranta H, Ranta K, Shah H. Blackpigmented *Bacteroides* spp. in human apical periodontitis. *Infect Immun* 1986; 53(1): 149-53.
23. Trope M, Tronstad L, Rosenberg ES, Listgarten M. Darkfield microscopy as a diagnostic aid in differentiating exudates from endodontic and periodontal abscesses. *J Endod* 1988; 14(1): 35-8.
24. Dahle UR, Tronstad L, Olsen I. Characterization of new periodontal and endodontic isolates of spirochetes. *Eur J Oral Sci* 1996; 104(1): 41-7.
25. Baumgartner JC. Microbiologic aspects of endodontic infections. *J Calif Dent Assoc* 2004; 32(6): 459-68.
26. Nair PN. Pathogenesis of apical periodontitis and the causes of endodontic failures. *Crit Rev Oral Biol Med* 2004; 15(6): 348-81.
27. Rupf S, Kannengressir S, Merte K, Pfister W, Sugusch B, Eschrich K. Comparison of profiles of key periodontal pathogens in periodontium and endodontium. *Endod Dent Traumatol* 2000;16(6): 269-275.
28. Dewhuist FE, Fox JG, On SL. Recommended minimal standards for describing new species of genus *Helicobacter*. *Int J Syst Evol Microbiol* 2000; 50(6):2231- 237.
29. Kasuga Y, Ishikara K, Okuda K. Significance of detection of *Porphyromonas gingivalis*, *Bacteroides forsythus* and *Treponema denticola* in periodontal pockets. *Bull Tokyo Dent Coll* 2000; 41 (3): 109-117.
30. Glick M, Trope M, Pliskin ME. Detection of HIV in the dental pulp of a patient with AIDS. *J Am Dent Assoc* 1989;119(5):649-650.
31. Madison S, Wilcox LR. An evaluation of coronal microleakage in endodontically treated teeth. Part III. In vivo study. *J Endod* 1988;14 (9):455-458.
32. Ray HA, Trope M. Periapical status of endodontically treated teeth in relation to the technical quality of the root filling and coronal restoration. *Int Endod J* 1995; 28(1):12-18.
33. Soames J V, Southam J C. Oral pathology. 3rd ed. Oxford: Oxford University Press, USA; 1998.
34. Lindhe J. Clinical periodontology and implant dentistry. 3rd ed. Denmark: Munksgaard Intl Pub; 1997. p. 296-328.
35. Christie WH, Holthuis AF. The endo-perio problem in dental practice: diagnosis and prognosis. *J Can Dent Assoc* 1990; 56(11): 1005-11.
36. Simon JH, Glick DH, Frank AL. The relationship of endodontic-periodontic lesions. *J Periodontol* 1972; 43(4): 202-8.
37. Jenkins WM, Allan CJ. Guide to Periodontics. 3rd ed. California: Wright Publishing Company; 1994. p. 146-52.

38. Kurihara H, Kobayashi Y, Francisco IA, Ishishima O, Nagai A, Murayama Y. A microbiological and immunological study of endodontic-periodontic lesions. *J Endod* 1995; 21(12): 617-21.
39. Torabinejad M, Lemon RL. Procedural accidents. In: Walton RE, Torabinejad M, eds. *Principles and Practice of Endodontics*, 2nd ed. Philadelphia: W.B. Saunders; 1996. p. 306-23.
40. Kvinnsland I, Oswald RJ, Halse A, Gronningsaeter AG. A clinical and roentgenological study of 55 cases of root perforation. *Int Endod J* 1989; 22(2): 75-84.
41. Saunders WP, Saunders EM. Coronal leakage as a cause of failure in root-canal therapy: a review. *Endod Dent Traumatol* 1994; 10(3): 105-8.
42. Madison S, Wilcox LR. An evaluation of coronal microleakage in endodontically treated teeth. Part III. In vivo study. *J Endod* 1988; 14(9): 455-8.
43. Bakland LK, Andreasen FM, Andreasen JO. Management of traumatized teeth. In: Walton RE, Torabinejad T, eds. *Principles and Practice of Endodontics*, 3rd ed. Philadelphia: WB Saunders; 2002. p. 445-65.
44. Cvek M, Lindvall AM. External root resorption following bleaching of pulpless teeth with oxygen peroxide. *Endod Dent Traumatol* 1985; 1(2): 56-60.
45. Rotstein I, Torek Y, Lewinstein I. Effect of bleaching time and temperature on the radicular penetration of hydrogen peroxide. *Endod Dent Traumatol* 1991; 7(5): 196-8.
46. Kumar R, Patil S, Hoshing U, Medha A, Mahaparale R. Non-surgical endodontic management of the combined Endo-perio lesion. *International Journal of Dental Clinics*. 2011; 3(2).
47. Patil VA, Despande P. Endo-Perio Lesion: An Interdisciplinary Approach. *International Journal of Dental Clinics*. 2009; 1(1).
48. Grossman LI, Oliet S, Carlos E, Rio D. *Endodontic practice*: Lea & Febiger; 1988.
49. Simon J, Glick D, Frank A. The relationship of endodontic-periodontic lesions. *Journal of periodontology*. 1972; 43(4):202-8.
50. Gargiulo Jr A. Endodontic-periodontic interrelationships. Diagnosis and treatment. *Dent Clin North Am*. 1984; 28(4):767-81.
51. Snyder B, Ryerson CC, Corona H, Grogan EA, Reynolds HS, Contestable PB, et. al. Analytical performance of an immunologic- based periodontal bacterial test for simultaneous detection and differentiation of *Actinobacillus actinomycetemcomitans*, *Porphyromonas gingivalis*, and *Prevotella intermedia*. *Journal of periodontology*. 1996; 67(5):497-505.
52. Solomon C, Chalfin H, Kellert M, Weseley P. The endodontic- periodontal lesion: a rational approach to treatment. *The Journal of the American Dental Association*. 1995; 126(4):473-9.
53. Harrington G. The perio-endo question: differential diagnosis. *Dental Clinics of North America*. 1979; 23(4):673.
54. Albee FH. Studies in bone growth: triple calcium phosphate as a stimulus to osteogenesis. *Annals of surgery*. 1920; 71(1):32-9.
55. Marx RE, Carlson ER, Eichstaedt RM, Schimmele SR, Strauss JE, Georgeff KR. Platelet-rich plasma: Growth factor enhancement for bone grafts. *Oral Surgery, Oral Medicine, Oral Pathology, Oral Radiology, and Endodontology*. 1998; 85(6): 638-46.
56. Nyman S, Lindhe J, Karring T, Rylander H. New attachment following surgical treatment of human periodontal disease. *Journal of clinical periodontology*. 1982; 9(4):290-6.
57. Jew RC, Weine FS, Keene JJ, Jr., Smulson MH. A histologic evaluation of periodontal tissues adjacent to root perforations filled with Cavit. *Oral Surg Oral Med Oral Pathol* 1982; 54(1): 124-35.
58. Oynick J, Oynick T. Treatment of endodontic perforations. *J Endod* 1985; 11(4): 191-2.
59. Lee SJ, Monsef M, Torabinejad M. Sealing ability of a mineral trioxide aggregate for repair of lateral root perforations. *J Endod* 1993; 19(11): 541-4.