

Sequelae of Wearing Complete Dentures

MAA Khan¹, MS Jahan², A Yousuf³, S Parveen⁴, N Mohsina⁵, S Banik⁶, MM Hossain⁷

Abstract

The use of complete dentures is not free of trouble. The dentures can produce severe side effects, which if left unchecked will produce, destabilization of occlusion, loss of retention, decreased masticatory efficiency, poor aesthetics, increase ridge resorption, tissue injury. The problems will progress till the stage where the patient will be considered 'prosthodontically maladaptive' and cannot wear dentures any more. The interaction of prosthesis and oral environment has several aspects. The surface properties of the prosthesis may affect plaque formation. Surface irregularities and microporosities can enhance microbial colonization. Plaque formation is also influenced by: design of prosthesis, health of adjacent mucosa, composition of saliva, salivary secretion rate, oral hygiene, denture wearing habits. Thus, a prosthesis may promote infection of the underlying mucosa, caries and periodontal diseases of the overdenture abutments, perimplantitis (inflammation of the peri-implant membrane), chemical degradation or corrosion of prosthesis. All these disorders produced/ accelerated in the oral tissues due to the presence of a denture are grouped as sequelae of wearing complete dentures. Sequelae of complete denture wear can be divided into direct and indirect types depending on the effect of the prosthesis on the tissues are discussed and hence the current literature is reviewed.

Key words: Complete dentures, oral environment, prosthesis.

1. Dr. Md. Ali Afzal Khan. BDS, MS., Assistant Professor, Department of Prosthodontics, Update Dental College & Hospital.

2. Dr. Md. Shahed Jahan . BDS, MPH., Assistant Professor, Department of Dental Public Health, Update Dental College and Hospital.

3. Dr. Anwar Yousuf, BDS, PhD, Associate Professor & Head, Dental Unit, Somorita Medical College.

4. Dr. Saleha Parveen. BDS, DDS., Assistant Professor, Department of science of dental materials, Dhaka Dental College & Hospital.

5. Dr. Newaz Mohsina. BDS, FCPS (Trainee), Department of oral and maxillofacial surgery, Dhaka Dental College and Hospital.

6. Dr. Shoma Banik. BDS, FCPS., Assistant Professor and Head Department of oral and maxillofacial surgery, Update Dental College & Hospital.

7. Dr. MD. Mahfuz Hossain. BDS, DDS., Assistant Professor and Head, Department of oral anatomy and physiology, Update Dental College & Hospital.

Address of Correspondence:

Dr. Md. Ali Afzal Khan. BDS, MS., Assistant Professor, Department of Prosthodontics, Update dental college & Hospital.

Introduction

The direct sequelae caused by wearing complete denture; Mucosal reactions, oral galvanic currents, altered taste perception, flabby ridge, traumatic ulcers, burning mouth syndrome, denture irritation hyperplasia, oral cancer in denture wearers, gagging, residual ridge resorption, periodontal disease (abutments), caries (abutments).¹

Denture Stomatitis

It is the pathological reaction of the palatal portion of the denture-bearing mucosa. It is commonly known as 'Denture induced stomatitis', 'Denture sore mouth', 'Denture stomatitis', 'Inflammatory papillary hyperplasia' (or) 'Chronic atrophic candidiasis'. It is seen in 50% of the complete denture wearers.

According to Newton, denture stomatitis can be classified as:

Type I: Localized simple infection with pinpoint hyperemia.

Type II: (Erythematous type) Generalized simple type presenting a more diffuse erythema involving a part or the entire denture covered mucosa.

Type III: Granular type involving the central part of the hard palate and alveolar ridge often seen in association with type I and II.

Type I is usually trauma induced, type II and III are associated with microbial plaque accumulation. Candida associated denture stomatitis is often seen along with angular cheilitis (or) glossitis.⁴

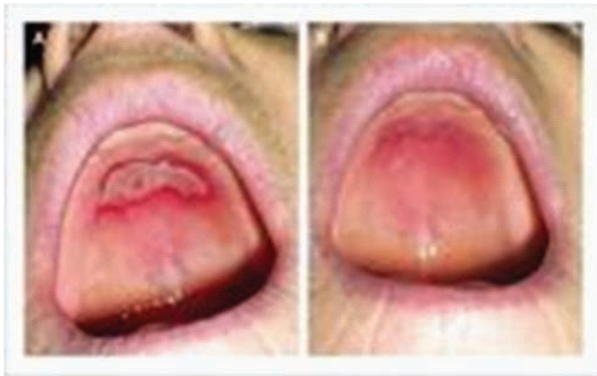

Figure: Denture Stomatitis

Diagnosis

The presence of Candida associated denture stomatitis (CADS) is confirmed by the presence of mycelia or the pseudohyphae in a direct smear. It can also be diagnosed by the isolation of more than 50 candidal colonies from the lesions. The candida usually resides on the fitting surface of the denture.

Etiology

Patients who wear their dentures both day and night. Trauma from the denture in addition to plaque accumulation. Candida associated denture stomatitis is also correlated with angular cheilitis. The infection may start beneath the maxillary denture and later spread to the angle of the mouth.

Management

Supportive measures

The patient is advised to store his dentures in 0.2 to 2% chlorhexidine during the night. The patient should be instructed to remove the denture after meals and scrub before reinserting it. The patient is advised not to use the dentures at night or leave it exposed to air. Polishing of the tissue surface of the dentures should be done routinely in order to facilitate denture cleansing.

Systemic factors

Old age, Diabetes mellitus, Nutritional deficiency (Iron, folate, Vit.B12), Malignancy (Acute leukemia), Immune defects.

Drug therapy

Local therapy with nystatin, amphotericin B, micorazole and clotrimazole. To reduce the risk of relapse antifungal treatment should continue for four weeks. When lozenges are prescribed the patient should be instructed to retain the dentures during its use.

Surgical Management

Surgical management includes the elimination of deep crypts in Type III denture stomatitis. This is preferably done by cryosurgery.

Flabby Ridge

Flabby ridge are most commonly seen in the anterior part of maxilla opposing natural mandibular anterior teeth. Flabby ridges provide poor support for the denture, Hence, they should be surgically removed.

Denture irritation hyperplasia

A common sequela of wearing ill-fitting dentures is the occurrence of tissue hyperplasia of the mucosa in contact with the denture border. The lesions are the result of chronic injury by unstable dentures or by thin, overextended denture flanges. The proliferation of tissue may take place relatively after placement of new denture and is normally not associated with marked symptoms.⁴⁻⁹

Traumatic ulcers

Traumatic ulcers or sore spots most commonly develop within 1 to 2 days after placement of new dentures. The ulcers are small and painful lesion covered by a gray necrotic membrane and surrounded by an inflammatory halo with firm, elevated borders. The direct cause is usually overextended denture flanges or unbalanced occlusion.⁴

Oral cancer in denture wearers

An association between oral carcinoma and chronic irritation of the mucosal by the denture has often been claimed, but no definite proof seems to exist. Case reports have detailed the development of oral carcinomas in patients who wear ill fitting dentures.

Burning mouth syndrome

Burning mouth syndrome is a painful and often frustrating condition. Some patients compare this to having burned their mouth with hot drinks. The burning sensation may affect the tongue, the roof of the mouth, the gums, the inside of the cheeks and the back of the mouth or throat.

The condition sometimes is known as burning tongue (or lips) syndrome, scalded mouth syndrome, glossodynia and stomatodynia. Burning mouth pain is often absent during the night but progressively increase throughout the day and into the evening. Damage to the cranial nerves that serve taste function is thought to decrease the inhibition of trigeminal-nerve pain fibers, which can lead to oral burning symptoms. The medical management of burning mouth syndrome follows the example of other neuropathic pain conditions and includes low dosage of benzodiazepines, tricyclic antidepressants and anticonvulsants.³

Etiology

External factors

Methyl methacrylate, Plasticizer, Free monomer, Excessive pressure from a denture base on the incisive papilla, Others, smoking, tobacco chewing, mouth breathing, chronic alcoholism and tongue habits. The continued ingestion of excessively seasoned foods. Various oral preparations such as mouthwashes, denture adhesive and cleansers and tooth pastes and powders, could possibly play a part.¹¹⁻¹⁵

Internal factors

Vitamin deficiency, Metabolic and circulatory disturbance, Pernicious and iron-deficiency anemia, Gastrointestinal disorder, Hormonal imbalance.

Psychological factors

Postmenopausal women, Nervous, Worried, Tense, Anxious.

Management of burning mouth syndrome

External factors

If methyl-methacrylate cause allergic reaction then denture remade by other resin such polysdyrene, nylon or polycarbonate or cast gold or chrome base may be constructed. Free monomer which is extracted by water or saliva disappears in a few ours when the denture is immersed in water or worn by the patients. Excessive pressure of the incisive papilla should be relieve. Other factors such as smoking, tobacco chewing etc. should be avoided.³

Internal factors

By flooding the body with vitamin-C (ascorbic acid), 1500 mg per day, two tablets of 250 mg taken with each meal for a four week period. He then reduces this dose to 750 mg per day, one tablet of 250 mg with each meal which is continued in definitely.³

Psychological factors

Patients understanding and constant reassurance on the part of the dentist are imperative. Psychiatric consultation, the consultation between the dentist and psychiatrist. The use of tranquilizer and sedatives if necessary.

Residual ridge reduction

Residual ridge resorption is a common and often incapacitating problem, particularly for person with edentulous mandibles. Several studies suggest a correlation between ridge resorption and osteoporosis. Recent radiologic studies indicate that the mineral density of the cortex and the bone mass in the mandible are correlated with skeletal bone density. Most resorption occurs in the alveolar process, whereas the basal portion remains relatively intact. On the other hand, radiologic measurements of bone density primarily yield information about the basal portion, where the bone mass of the mandible is greatest and functional stresses of mastication may affect bone density. Ironically, radiologic measurements may not accurately indicate the effect of osteoporosis on alveolar resorption.^{2,7,9}

Gross pathology

Residual ridge resorption (RRR) is a reduction in the size of the bony ridge under the mucoperiosteum. It is primarily a localized loss of bone structure. In overlying mucoperiosteum excessive and redundant. However, sometimes there is no redundant soft tissue in areas where severe bone loss has occurred. Numerous longitudinal radiographic cephalometric studies have provided excellent visualization of gross patterns of this bone loss from a lateral view.³²⁻³⁹

The six order of residual ridge form has been described as Order I: Preextraction, Order II : Postextraction, Order III: High well rounded, Order IV: Knife edge, Order V: Low well rounded, Order VI: Depressed.

The usual life history of RRR can be illustrated diagrammatically and radiographically. Immediately following the extraction (order II) any sharp edges remaining are rounded off by external osteoclastic resorption, leaving a high, well-rounded residual ridge (order III). As resorption continues from the labial and lingual aspects (see arrows), the crest of the ridge becomes increasingly narrow, ultimately becoming knife-edged. As the process continues, the knife edge becomes shorter and eventually disappears, leaving a low well-rounded or flat ridge (Order V). Eventually, this resorbs, leaving a depressed ridge (Order VI).

Some proposed etiological factors of reduction of residual ridges:

Anatomical factors

More important in the mandible versus the maxilla, Short and square face associated with elevated masticatory forces, Alveoloplasty.

Mechanical factors

Abnormal parafunctional activity such as bruxism

Prosthetic factors

Intensive denture wearing, Unstable occlusal conditions, Immediate denture treatment.

Metabolic and systemic factors

Osteoporosis, Calcium and vitamin D supplements for possible bone preservation.

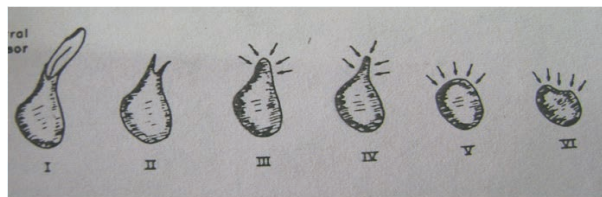


Figure: Pattern of resorption after extraction.

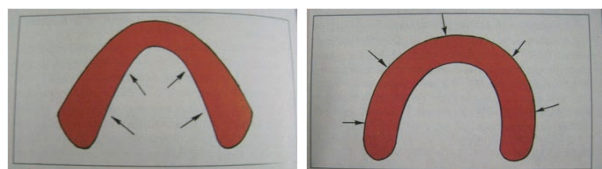


Figure: Pattern of resorption in mandible on the left and maxilla on the right

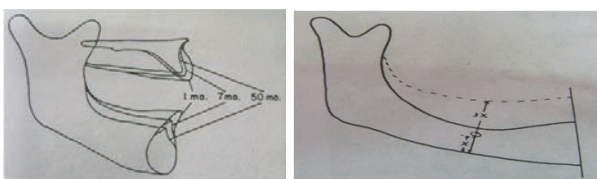


Figure: Ridge resorption after 1 month, 7 month, 50 month and Mandibular ridge resorption

Abutments (caries and periodontal diseases)

The retention of selected teeth to serve as abutments under complete dentures is an excellent prosthodontic technique. In this simple method, a few teeth in strategically good position are preserved and are treated endodontically before the crown is modified. The exposed root surface and canal are filled with amalgam or a composite restoration. In this way, even periodontally affected teeth can be maintained for several years in a relatively simple way.¹⁵⁻²⁴

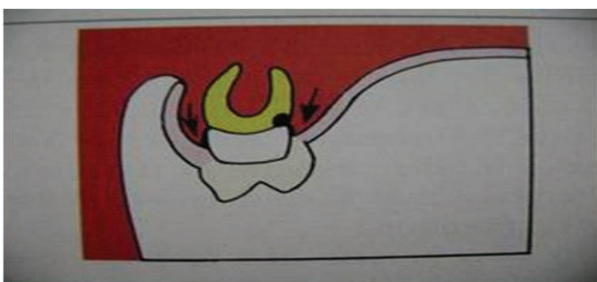


Figure: Abutment caries.

Management of the abutment caries & periodontal diseases

Treatment of the superficial caries of the over denture abutments includes application of fluoridechlorhexidine gel and polishing, and not exclusive placement of fillings, which could result in recurrent caries. The placement of coping that cover the exposed dentin and root surface is indicated only where caries is more deeply penetrating.²⁰⁻²⁷

Gagging

The gag reflex is a normal, healthy defense mechanism. Its function is to prevent foreign bodies from entering the trachea. Gagging can be triggered by tactile stimulation of the soft palate, the posterior part of the tongue, and the fauces. However, other stimuli such as slight taste, noise, as well as psychological factors, or a combination of these, may trigger gagging. In sensitive patients, the gag reflex is easily released after placement of new dentures, but it usually disappears in a few days as the patient adapts to the dentures.^{3,4,34}

Indirect sequelae**Atrophy of masticatory muscles**

It is essential that oral function in complete denture wearers is maintained throughout life. The masticatory function depends on the skeletal muscular force and the facility with which the patient is able to coordinate oral functional movements during mastication. Maximal bite forces tend to decrease in older patients. Furthermore, computed tomography studies of the masseter and the medial pterygoid muscles have demonstrated a greater atrophy in complete-denture wearers, particularly in women.^{5,6}

Management

To some extent, the retention of small number of teeth used as over denture abutments seems to play an important role in the maintenance of oral function in elderly denture wearers. Therefore treatment with over dentures has particular relevance in view of the increasing numbers of older people who are retaining a part of their natural dentition later in life.²⁸⁻³¹

Nutritional Deficiencies

Ageing is often associated with decrease in energy needs. Old patients show a decrease in muscle mass and decreased physical activity and reduced food intake. Masticatory efficiency is the capacity of a person to reduce food during mastication.⁸

Nutritional Status and Masticatory Function

The four factors that relate diet selection to the nutritional status of a patient are Masticatory function and oral health, General health, Socioeconomic status, Dietary habits.^{8,10}

Conclusion

General precautions, which will help prevent and control the sequelae of complete dentures are modified dietary habits wherein balanced diet is administered, food particles can be mechanically broken down before eating to reduce the burden on the oral musculature, the dentist should try to preserve the remaining teeth as much as possible and at least fabricate an overdenture, regular follow up overdenture patients should be frequently recalled to examine the status of the abutment.

References

- Bolender Z. Sequelae caused by wearing complete denture. *Prosthodontics treatment for edentulous patient*, 12th ed. 2004;34-49
- Klemetti E. A review of residual ridge resorption and bone density. *The Journal of Prosthetic Dentistry* 1996;75:512-514.
- Burning mouth syndrome. *J Am Dent Assoc* 2005;136:1191.
- Jeganthan S, Payne JA, Thean HPY. Denture stomatitis in an elderly edentulous Asian population. *Journal of Oral Rehabilitation* 1997;24:468-472.
- Grushka M. Burning mouth syndrome. *American Family Physician* 2002.
- Barbeau J, Seguin J, Goulet JP. Reassessing the presence of candida albicans in denture-related stomatitis. *Oral Surgery, Oral Medicine, Oral Pathology, Oral Radiology & Endodontics* 2003;95:51-59
- Mercier P, Bellavance F. Effect of artificial tooth material on mandibular residual ridge resorption. *Journal of the Canadian Dental Association* 2002;68:346-350.
- Sheldon Winker. *The Geriatric complete denture patient. Essential of complete denture prosthodontics.*
- Xie Q., Närhi T. O., Nevalainen J. M., Wolf J., Ainamo A., Oral status and prosthetic factors related to residual ridge resorption in elderly subjects, *Acta Odontol Scand*, 1997, 55(5):306-313.
- Păuna M., Preoteasa E., Practical aspects in the prosthetic therapy of complete edentulism, Cerma Publishing House, Bucharest, 2005, 17-59 (in Romanian).
- Heydecke G., Schnitzer S., Türp J. C., The color of human gingiva and mucosa: visual measurement and description of distribution, *Clin Oral Investig*, 2005, 9(4):257-265.
- Hüe O., Berteretche M. V., Complete dentures. *Clinic reality. Therapeutical solutions*, Quintessence International, Paris, 2004, 5-15, 27-38.
- Rignon-Bret C., Rignon-Bret J. M., Complete dentures. *Immediate prosthesis. Overdenture*, CdP, Langres, France, 2004, 21-60.
- Hutu EM., Păuna M., Bodnar V., Constantinescu M. V., Țăncu A., Complete edentulism, National Publishing House, Bucharest, 2005, 16-39, 240-245 (in Romanian).
- Lello G. E., Makek M., Submucosal nodular chondrometaplasia in denture wearers, *J Prosthet Dent*, 1985, 54(2):237-240.
- Waliszewski M., Restoring dentate appearance: a literature review for modern complete denture esthetics, *J Prosthet Dent*, 2005, 93(4):386-394.
- Basker IC, Davenport A. *Prosthetic treatment of the edentulous patient*. 4th ed. Blackwell Munksgaard; 2003.
- Devlin H, Hoad-Reddick G. Biological guides to the positioning of the artificial teeth in complete dentures. *Dent Update* 2001; 28: 492-5.
- Brunello DL, Mandikos MN. Construction faults, age, gender and relative medical health: Factors associated with complaints in complete denture patients. *J Prosthet Dent* 1998; 79: 545-54.
- Winkler S. Psychological aspects of treating complete denture patients: their relation to prosthodontic success. *J Geriatr Psychiatry Neurol* 1989; 2: 48-51.
- Douglass CW, Shih A, Osty L. Will there be a need for complete dentures in the United States in 2020? *J Prosthet Dent* 2002; 87: 5-8. 15. Jeganathan S, Payne IA. Common faults in complete dentures: a review. *Quintessence Int* 1993; 24: 483-7.
- Narhi TO, Ettinger RL, Lam EW. Radiographic findings, ridge resorption and subjective complaints of complete denture patients. *Int J Prosthodont* 1997;10:183-9.

23. Carlsson GE. Clinical morbidity and sequelae of treatment with complete dentures. *J Prosthet Dent* 1998; 79: 455-61.
24. Finbarr A, Carthy SMC. Complete dentures from planning to problem solving. London, Berlin, Chicago: Quintessence Publishing Co. Ltd.; 2003.p. 95-6.
25. Kuebker WA. Denture problems: causes, diagnostic procedures, and clinical treatment. 1. Retention problems. *Quintessence Int* 1984; 15: 1031-44.
26. Magnusson T. Clinical judgment and patient's evaluation of complete dentures five years after treatment. A follow-up study. *Swed Dent J* 1986; 10: 29-35.
27. Dong IK, Jin TH, Cho HW, Oh S. The esthetics of the smile: a review of some recent studies. *Int J Prosthodont* 1999;12: 9-19.
28. Fiske J, Davis DM, Horrocks P. A self – group for complete denture wearers. *Br Dent J* 1995;178: 18-22.
29. Vervoorn IM, Duinkerke AS, Kuteijn F, van de Poel AC. Assessment of denture satisfaction. *Community Dent Oral Epidemiol* 1988; 16:364-7.
30. Vallittu PK, Vallittu ASI, Lassila VP. Dental aesthetics- a survey of attitudes in different groups of patients. *J Dent* 1996; 24: 335-8.
32. Davis LG, Ash worth PD, Spriggs LS. Psychological effects of aesthetic dental treatment. *J Dent* 1998; 26: 547-52.
33. Owens EG, Goodacre CI, Loh PL, Hanke G, Okamura M, Jo KH, et al. A multicenter interracial study of facial appearance. Part 1; a comparison of extraoral parameters. *Int J Prosthodont* 2002; 15: 273-82.
34. Kokich VOIr, Kiyar HA, Shapiro PA. Comparing the perception of dentists and lay people to altered dental esthetics. *J Esthet Dent* 1999;11: 311-24.
35. Dong IK, Jin TH, Cho HW; Oh SC. The esthetics of the smile: a review of some recent studies. *Int J Prosthodont* 1999; 12: 9-19.
36. Field EA, Fear S, Higham SM, Ireland RS, Rostron J, Willetts RM, et al. Age and medication are significant risk factors for xerostomia in an English population, attending general dental practice. *Gerodontology* 2001; 18: 21-4.
37. Niedermeier W, Huber M, Fischer D, Beier K, Muller N, Schuler R, et al. Significance of saliva for denture- wearing population. *Gerodontology* 2000; 17:104-18.
38. Jagger DC, Harrison A, Jandt KD. The reinforcement of dentures. *J Oral Rehabil* 1999; 26: 185-94.
39. Kelly E. Changes caused by a mandibular removable partial denture opposing a maxillary complete denture.