

Orthopantomographic evaluation of third molar developmental stages in relation to chronological age of Bangladeshi female garment workers

SZ Mahmud¹, NA Nomann², MA Kabir³, CM Jan⁴

Abstract

Human teeth are among the most distinctive and long lasting features of mammal species. Various quantitative and qualitative methodologies have been developed by the researchers in order to establish an assessment format to determine the correlation between the dental age and the chronological age. The morphological and radiological examinations of third molars make up a part of the orthodontic, pedodontic, forensic odontology and oral surgical treatments and remain the most reliable biologic indicator available for age estimation during the middle teens and early twenties. This age calculation requirement is not only for differentiating the juvenile from the adult status in criminal law cases, but also for chronological age estimation in relation to school attendance, social benefits, employment and marriage. A case for actual need for age estimation using a developing third molar is presented here.

Key words: Age estimation, Chronological age, Dental age, Tooth development, Third molar.

Introduction

Growth is an essential feature of life of a child that distinguishes him or her from an adult. Growth denotes a net increase in the size or mass of tissues, whereas development specifies maturation of functions. Hereditary, functional, environmental, nutritional, sexual, metabolic, social, emotional, cultural factors affect growth and development greatly.¹

In advanced countries various quantitative and qualitative methodologies have been developed by the researchers in order to establish an assessment format to determine the correlation between the dental age and the chronological age. By the chronological age we mean the age of an individual in years while by the dental age we mean the age of an individual determined by the dentition.² However, the relationship between growth and chronological age is not linear and therefore the concept of 'biological' age is used which maybe expressed as either skeletal age or dental age. When the birth date is not known, there will be a strong need to estimate the biological or dental age.³ Over the last few years, age evaluation of live subjects has become very important in forensic sciences. People with incorrect birth certificates often need age estimation procedures to obtain regular documents. In adoption cases, it is frequently necessary to develop age estimation procedures to fulfill the purpose of the process. In criminal circumstances, lack of documents to confirm chronological age may have important consequences.⁴ This is surprising since, in criminal law a need exists to separate the juvenile from adult status for individuals lacking age documentation. Specifically around 18 years of age, all permanent teeth have completed their root formation and show closed apices, except for the third molars. These teeth, if present, offer the only possibility for dental age estimation between 16 and 22 years of age.⁵ This age calculation requirement is not only for differentiating the juvenile from the adult status in criminal law cases, but also for chronological age estimation in relation to school attendance, social benefits, employment and marriage.⁶

1. Dr. Shaikh Zakir Mahmud, BDS, MPH, Senior Medical Officer, Department of Dentistry, Ibrahim General Hospital, Mirpur, An Enterprise of the Diabetic Association of Bangladesh (BADAS), Dhaka, Bangladesh.

2. Dr. Nahid Al Nomann, BDS, Doctoral Fellow, Division of Clinical Cariology and Endodontology, Department of Oral Rehabilitation, School of Dentistry, Health Sciences University of Hokkaido, Japan.

3. Dr. Md. Arafat Kabir, BDS, Doctoral Fellow, Department of Oral & Maxillofacial Surgery, School of Dentistry, Health Sciences University of Hokkaido, Japan.

4. Dr. Chowdhury Moin Jan, BDS, PhD, Professor and Head, Department of Conservative Dentistry & Endodontics, MARKS Dental College & Hospital, Dhaka, Bangladesh.

Address of Correspondence:

Dr. Shaikh Zakir Mahmud, BDS, MPH, Senior Medical Officer, Department of Dentistry, Ibrahim General Hospital, Mirpur, An Enterprise of the Diabetic Association of Bangladesh (BADAS), Dhaka, Bangladesh.
E-mail: suman79_bd@yahoo.com

For the juvenile age group, there are two methods of identification: the morphological examination of skeletal features and radiological examination of the development of third molars. The morphological and radiological examinations of third molars make up a part of the orthodontic, pedodontic and oral surgical treatments and remain the most reliable biologic indicator available for estimation of age during the middle teens and early twenties.⁷ The age assessment methods are relatively simple and involve the identification of the stage of mineralization on radiographic images followed by their comparison with the standard stage to estimate the approximate age range. Various radiographic images that can be used in age identification are intraoral periapical radiographs, lateral oblique radiographs, cephalometric radiographs, panoramic radiographs, digital imaging and advanced imaging technologies.⁸ Several methods of determining the dental age according to the degree of calcification of the permanent teeth as seen in radiographs have been described. Currently, one of the most well-known and widely used methods for estimating dental age is the Demirjian method, first described in 1973 and based on a large sample of French-Canadian children.⁹

Case Report

An 18-years-old female patient was referred from a garment factory to collect medical report on her age determination whether she was 18 years or not. On examination of her teeth, it was observed that all the 3rd molars were clinically absent. As dental x-ray facilities were available, an orthopantomogram (panoramic radiograph) was taken to detect her chronological age based on the dental developmental stages of third molars.

Radiographic examination showed that both the maxillary and mandibular third molar crowns were completed but the roots have not yet been formed (Figure 01). In accordance with the chart of Demirjian *et. al.* (Figure 02) the morphology matched with stage D where the crown formations were completed.¹⁰ This finding was subsequently compared with Table 1 provided by Mincer *et. al.*¹¹ Stage D of mandibular third molars development had a mean age of 16.0 years with a range of 14.36 to 17.64 years at one standard deviation. As the morphology of the tooth formation of the female was in D stage, the probability of this female being 16 years was possible.

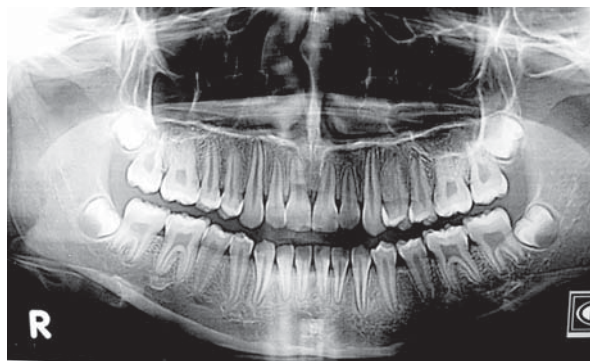

Figure 01: Orthopantomographic view of the female garment worker showing the developing third molar.

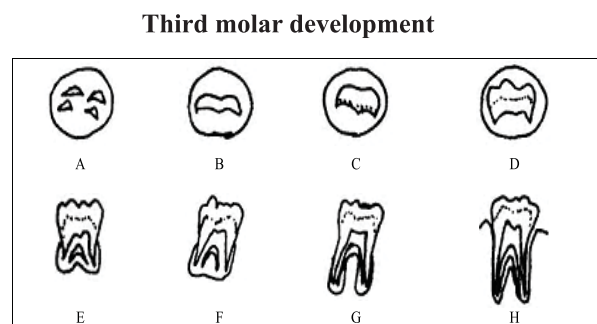


Figure 02: Schematic drawing of the eight stages of crown - root formation of the molars as proposed by Demirjian *et. al.*¹⁰ Stages A, B, C do not occur in the age group included in this study. Stage D crown formation is completed, stage E the root length is less than the crown height, stage F the root length is equal to or greater than the crown height, stage G the walls of the root canal are parallel and its apical end is still opened and stage H the apical formation is completed.

Table 1: Mean age at attainment of stages of third molar crown-root formation according to Mincer *et. al.*¹¹

Grade of formation		D	E	F	G	H
Maxilla						
Male	\bar{x}	16.0	16.6	17.7	18.2	20.2
	sd	1.97	2.38	2.28	1.92	2.09
Female	\bar{x}	16.0	16.9	18.0	18.8	20.6
	sd	1.55	1.83	1.95	2.27	2.09
Mandible						
Male	\bar{x}	15.5	17.3	17.5	18.3	20.5
	sd	1.59	2.47	2.14	1.93	1.97
Female	\bar{x}	16.0	16.9	17.7	19.1	20.9
	sd	1.64	1.75	1.80	2.18	2.01

SD = Standard Deviation
 \bar{x} = Mean Age

Discussion

Dental identification of humans occurs for a number of different reasons and in a number of different situations. The bodies of victims of violent crimes, fires, motor vehicle accidents and work place accidents, can be disfigured to such an extent that identification by a family member is neither reliable nor desirable. Persons who have deceased for some time prior to discovery and those found in water also present unpleasant and difficult visual identifications. Dental identifications have always played a key role in natural and man made disaster situations and in particular the mass casualties normally associated with aviation disasters. Because of the lack of a comprehensive fingerprint database, dental identification continues to be crucial in the United Kingdom.¹²

In July 1993, an unknown murdered male was examined whose facial features, skin color and dentition were suggestive that he was an Indo-European. All the third molar teeth were not present clinically in the deceased during oral examination. The third molars are prone to impaction as they are the last teeth to form and erupt. These teeth erupt when the roots are 3/4 formed. That is the reason why x-rays should be taken during every examination.¹³ Only viable examination method for this purpose is to take an OrthoPantomoGraphic (OPG) x-ray to analyze the development of the third permanent molar (wisdom tooth).¹⁴ In the present case, a panoramic radiograph was also taken to detect her chronological age in relation to dental age.

In between 2006 and 2010 an investigation studied third molar development in 329 orthopantomograms of Portuguese individuals with an age range between 14.0 to 22.8 years, through five different methods (Demirjian, Haavikko, Harris and Nortje, Kullman and Solari) to evaluate the dental development in the ages of Portuguese criminal law: 16 and 18 years old. It represented the probability of an individual in the different stages of dental development be respectively less than 18 years old or at least 16 years old.¹⁵ Similar result was found in the current case indicating that the probability of this female being 16 years was possible.

Table 1 provided in current study was for Caucasoids, which is strongly related to the racial origin of that female garment worker who was a Bangladeshi. However, it is not known if this table is suitable for the Mongoloid population. The stages from E-G there were earlier development in females in maxillary molars but it was earlier in males in mandibular molars. The full eruption of third molar (H stage) was earlier in females in the four molars compared with males.¹⁶

Orthopantomogram (OPG) is very useful for the inspection of child labor. The International Labor Organization (ILO) undertook a study of child worker in the urban informal economy, including the garment sector where it emerged that 70 percent of child workers in the industry were girls and that there was a pattern of informal recruitment, typically around 11 years of age, to do mostly casual jobs. The mean age of these children was 13 years.¹⁷ In 1993, the Government of Bangladesh created a National Labor Law Commission to revise and harmonize labor laws. The first draft of the recommendations, completed on March 31, 1994, proposes to eliminate the inconsistencies regarding the minimum age for employment by defining a child as a person who has not completed his fourteenth year of age.¹⁸ The new law in 2006 prohibits employment of children under 14 years old, as well as hazardous forms of child labor for persons under 18 years of age.¹⁹ In criminal circumstances, lack of documents to confirm chronological age may have important consequences.⁴

Tooth formation has been more widely used than tooth eruption for assessing dental maturation, because it is a continuous and progressive process that can be followed radiographically, and most teeth can be evaluated at each examination. It has been reported that development of each individual can be affected by genetic, racial, nutritional, climatic, hormonal and environmental factors.²⁰ Third molar growth and calcification are definitely not the favourite development marker. However, it is suitable because there are no other favourable indicators during the late teens and early twenties.¹³ In recent years, there has been great interest in the changes of the chemical composition of teeth. It has been reported that aspartic acid in tooth enamel and dentine exhibit increasing racemization with age. This reaction was found to be a good biochronological tool for assessing age and further research is being done in this area.²¹

Conclusion

For medico legal purposes, 18 years of age is an important cut off point. If a subject presents with a developmental stage A to D there is less likelihood that subject is 18 years old. On the other side if subject presents with developmental stage of H, there are more chances that the subject has crossed the 18 years of age. It is important to develop regional age estimation tables based on local surveys mainly considering ages of forensic interest.

References

1. Kumar V, Sundeep HK, Bhat SS. The relationship between dental age, bone age and chronological age in children with short stature. *Int Journal of Contemporary Dentistry* 2011; 2 :6-11.
2. Hamid WU, Firdos T, Asad S. Co-relation between the dental age and the chronological age. *Pakistan Oral & Dent Jr* 2004; 24 :171-80.
3. Ardakani F, Bashardoust N, Sheikhha M. The accuracy of dental panoramic radiography as an indicator of chronological age in Iranian individuals. *J Forensic Odontostomatol* 2007; 25 :30-35.
4. Carneiro APC, Guimarães JATL, Silva RMI, Santiago APCS, Filho JRL. Chronological table of third molar mineralization in a survey in the state of Alagoas, Brazil. *Braz J Oral Sci* 2010; 9 : 488-92.
5. Mesotten K, Gunst K, Carbonez A, Willems G. Dental age estimation and third molars: a preliminary study. *Forensic Sci Int* 2002; 129: 110-15.
6. Gunst K, Mesotten K, Carbonez A, Willems G. Third molar root development in relation to chronological age: a large sample sized retrospective study. *Forensic Sci Int* 2003; 136: 52-57.
7. Golovcencu L, Scripcaru C, Zegan G. Third molar development in relation to chronological age in Romanian children and young adults. *Rom J Leg Med* 2009; 17: 277-82.
8. Panchbhai AS. Dental radiographic indicators, a key to age estimation. *Dentomaxillofac Radiol* 2011; 40: 199-212.
9. Karatas OH, Ozturk F, Dedeoglu N, Colak C, Altun O. Dental age assessment: The applicability of Demirjian method in southwestern of eastern Anatolia region Turkish children. *Cumhuriyet Dent J* 2012; 15: 130-37.
10. Demirjian A, Goldstein H, Tanner JM. A new system of dental age assessment. *Hum Bio* 1973; 45: 211-27.
11. Mincer HH, Hanis EF, Berryman HE. The ABFO study of third molar development and its use as an estimator of chronological age. *J Forensic Sci* 1993; 38: 379-90.
12. Pretty IA, Sweet D. A look at forensic dentistry-Part 1: The role of teeth in the determination of human identity. *Br Dent J* 2001; 190: 359-66.
13. Narnbiar P. Age estimation using third molar development. *Malaysian J Pathol* 1995; 17: 31-34.
14. Australian Human Rights Commission. The use of dental x-ray analysis for the assessment of chronological age.
Available from: <http://www.humanrights.gov.au/publications/age-uncertainty-chapter-2> [accessed 01 July 2013]
15. Branco MS, Pestana D, Pereira CP. Medico-legal age estimation in living individual from a Portuguese population: Third Molar Mineralization. *J Forensic Res* 2012; 3: 1-8.
16. Hassan NA, Abo Hamila NAA. Orthopantomography and age determination using third molar mineralization in a sample of Egyptians. *Mansour. J Forensic Med Clin Toxicol* 2007; 15: 45-58.
17. Addressing child labor in the Bangladesh garments industry 1995-2001. A synthesis of UNICEF and ILO evaluation studies of the Bangladesh garment sector projects. Available from:
2003_BGMEA__synthesis_report_finaleval_en.pdf [assessed 29 June 2013]
18. The 2011 findings on the worst forms of child labor in Bangladesh. United States Department of Labor.
Available from:
<http://www.dol.gov/ilab/programs/ocft/2011TDA/bangladesh.pdf> [assessed 03 July 2013]
19. Child labor in the informal garment production in Bangladesh 2012. Available from:
<http://www.dol.gov/ilab/programs/ocft/PDF/2013Garm entBangladesh.pdf> [accessed 03 July 2013]
20. Rai B, Kaur J, Anand SC. Mandibular third molar development staging to chronological age and sex in North Indian children and young adult. *J Forensic Odontostomatol* 2009; 27:2: 45-49.
21. Gillard RD, Pollard AM, Sutton PA, Whittaker DK. An improved method for age at death determination from the measurement of D-Aspartic acid in dental collagen. *Archaeometry* 1990; 32: 61-70.