

# Needle-Assisted Laparoscopic Inguinal Hernia Repair in Children: Experience in Chittagong, Bangladesh

Md. Jafrul Hannan\*  
Md. Mozammel Hoque

Department of Paediatric Surgery  
Chattagram Maa-O-Shishu Hospital  
Medical College  
Chittagong, Bangladesh

## Abstract

**Purpose:** There are numerous procedures of minimally invasive surgery for repair of inguinal hernia in children including percutaneous techniques. We describe here our technique of using 18G or 20G needle in a very simple and effective way for this purpose. **Methods:** Needle-assisted laparoscopic percutaneous repair internal ring was performed in 55 children between 1st November 2010 and 31st July 2011. An 18G or 20G needle and a 3/0 polyglycolic acid thread were used. A 5-mm supraumbilical port for 30° 5 mm telescope and a 3-mm port in iliac fossa opposite to the lesion to handle the thread intra-abdominally were used. **Results:** Age ranged from 3 months to 12 years and 40 were males. Seven cases were bilateral making total 62 lesions. Mean operating time was  $30.54 \pm 5.84$  min (range 20–42) and there was no intraoperative complication. Postoperatively five cases had transient hydrocele which resolved spontaneously. One case recurred after 2 months. **Conclusions:** Needle-assisted laparoscopic inguinal hernia repair in children is a simple and effective technique that can be performed routinely in resource poor countries.

**Key words:** Inguinal hernia; Laparoscopy; Needle-assisted hernia repair.

## INTRODUCTION

Since the adaptation and progress of pediatric laparoscopy, laparoscopic repair of inguinal hernia in children has been widely practiced.<sup>1-5</sup> There are numerous procedures of minimally invasive surgery for repair of inguinal hernia in children including percutaneous techniques.<sup>6-11</sup> We have been practicing laparoscopy for inguinal hernia repair since 2005 by conventional 3 port intracorporeal knotting technique. The recurrence rate was about 4% with that technique, so we were in search for a more secure method. We describe here our technique of using 18G and 20G needle in a very simple and effective way for this purpose.

## MATERIALS AND METHODS

Needle-assisted laparoscopic percutaneous repair of internal ring was performed in 55 children between 1<sup>st</sup> November 2010 and 31<sup>st</sup> July 2011. An 18G or 20G needle depending on the ages of the children and a 3/0 polyglycolic acid thread was used. A 5 mm supraumbilical port for 30° 5 mm telescope and a 3 mm port in iliac fossa opposite to the lesion to handle the thread intra-abdominally were used (Figure 1). The 18G needle was used in older children and 20G needle in smaller

Correspondence to:

Md. Jafrul Hannan  
Department of Paediatric Surgery  
Chattagram Maa-O-Shishu Hospital  
Medical College  
Chittagong, Bangladesh  
Cell: +88-01819345305  
E-mail: jafrulhannan@gmail.com

ones. A piece of thread was passed through the needle core (Figure 2). A spot on the skin just above the upper limit of internal ring was selected. The needle with the thread was passed along half circle of internal ring and pierced the peritoneum to create and leave a loop of thread inside (Figure 3a & 3b). Then another longer piece of thread was passed into the needle core and piercing the same skin puncture spot passed along another half circle of internal ring and came inside peritoneal cavity close to the previous entry and leaving the thread end into the loop already present there (Figure 3c). The end of this thread is grasped with the 3-mm forceps and the loop pulled outwards. This maneuver brought the end of second thread out through the same puncture wound on the skin completing the circle around internal ring (Figure 3d & 3e). A secured tight knot at this point completed the hernia repair. Majority of the cases were done as day case and few were discharged the following morning after operation.

Age, sex, operative technique, operating time, complications, and outcomes were evaluated. The ethical review committee for thesis and research, Chattagram Maa-O-Shishu Hospital Medical College, has given permission to conduct this study.

## RESULTS

Mean age was  $5.77 \pm 3.29$  years (range 3 months to 12) and 40 were males. Seven cases were bilateral, constituting total 62 lesions. Mean operating time was  $30.54 \pm 5.84$  min (range 20–42) and there was no intraoperative complication. Post-operatively five cases had transient hydrocele which resolved spontaneously. One case recurred after 2 months.

## DISCUSSION

Operation for inguinal hernia is fairly common in pediatric surgical practice. Age old open technique is quite effective and safe although there are risk of missing the contra-lateral patent processus vaginalis and increased handling of vas and vessels.<sup>1-4,12-14</sup> At the hands of an experienced pediatric surgeon recurrence rate for open hernia repair is negligible, however laparoscopic techniques report up to 4%–6% recurrence.<sup>8,13</sup> In our series the recurrence is less than 2%, whether the rate is over 4% in our own cases done by intracorporeal knotting.

Now, a valid question may be asked about the necessity of laparoscopy in the treatment of inguinal hernia. Due to widespread use of laparoscopy for many disease conditions in children, even in a developing country like ours, parents frequently demand laparoscopy for each and every opera-

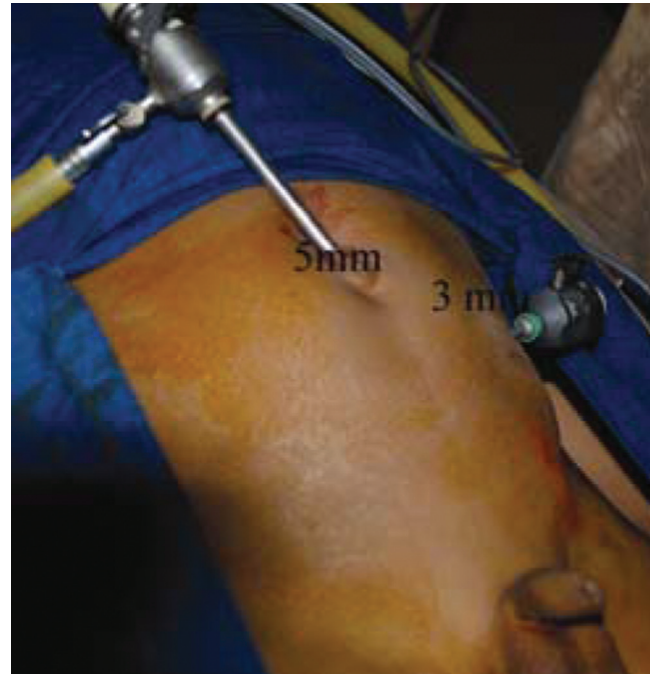

Figure 1: Ports placement

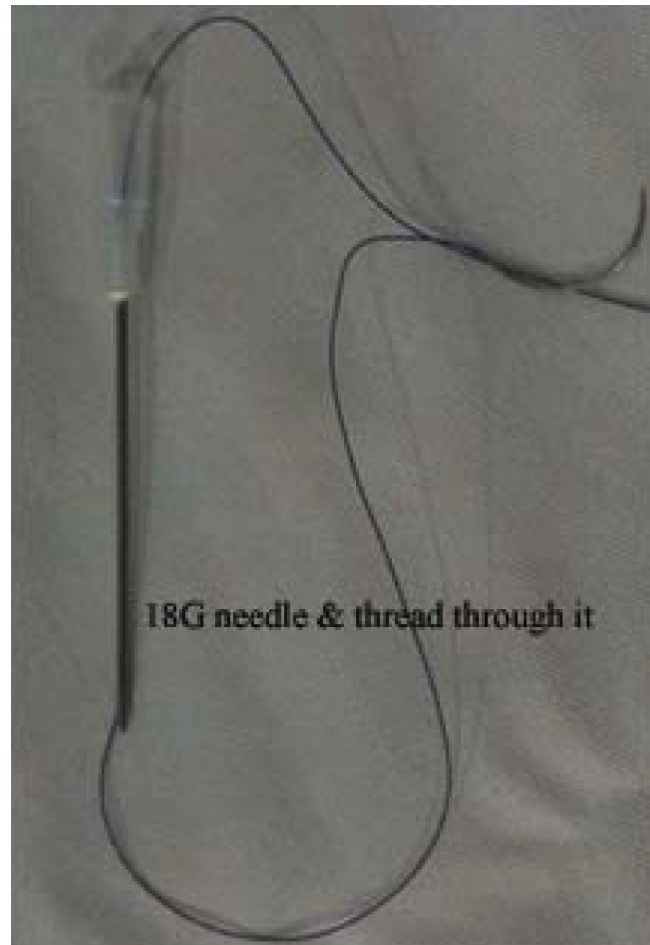

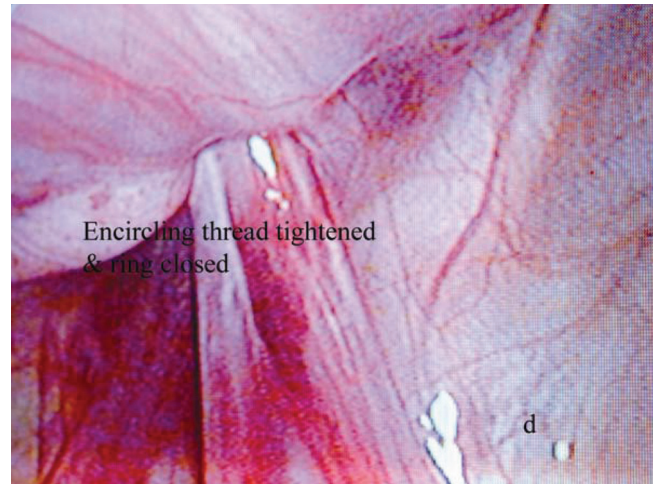


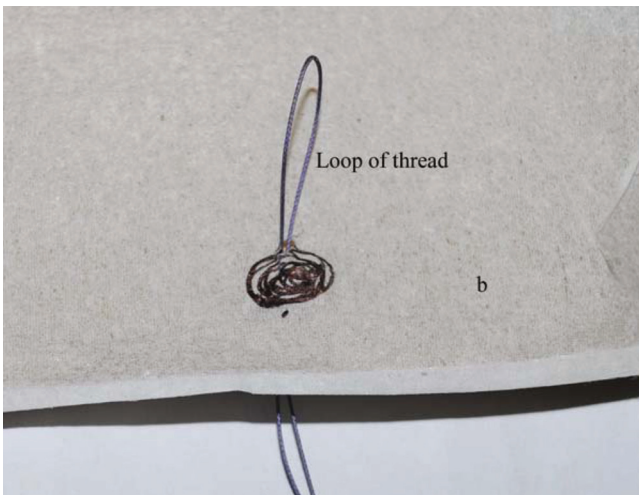
Figure 2: Needle and thread




**Figure 3a:** Needle with thread around half circle of internal ring



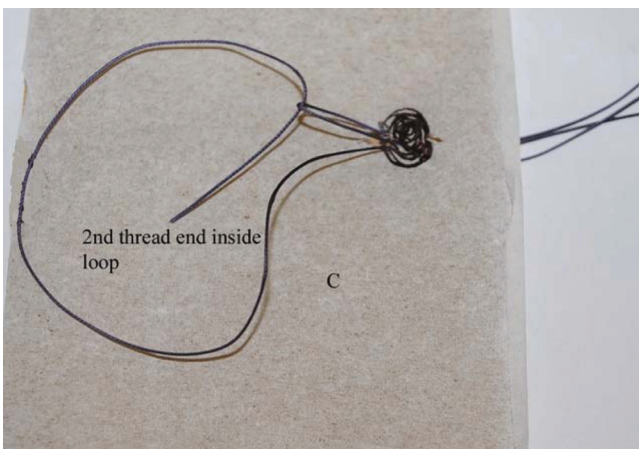
**Figure 3d:** Thread tightened around internal ring



**Figure 3b:** A loop with the thread created



**Figure 3e:** Both the ends of second thread came out through same puncture wound



**Figure 3c:** Second thread passed into already created loop

tion. So, we had to incorporate laparoscopy in the armamentarium of inguinal hernia treatment. Techniques were incorporated into laparoscopy to overcome this recurrence problem and percutaneous techniques seemed to serve the role.<sup>9-11, 15,16</sup>

Various percutaneous techniques described for laparoscopic inguinal hernia repair required special instruments.<sup>6-11</sup> The needle that we have used is easily available in the operation theatre and the procedure is very simple to learn by the residents who may not have expertise in intracorporeal knotting. Operating time was also shorter in this technique than 3 port technique in our experience ( $30.54 \pm 5.84$  vs  $38.31 \pm 5.50$  min). In this technique the internal ring is tightened completely without leaving any space in boys at the level of vas and vessels. Two surgeons were performing the operations in this series. The case that recurred was probably due to the technical fault on the part of one of the surgeons.



## CONCLUSIONS

Needle-assisted laparoscopic inguinal hernia repair in children is a simple and effective technique that can be performed routinely in resource poor countries.

### Disclosure Statement

No competing financial interests exist.

### References

- Schier F: Laparoscopic herniorrhaphy in girls. *J Pediatr Surg* 1998;33:1495-7.
- Montupet P, Esposito C: Laparoscopic treatment of congenital inguinal hernia in children. *J Pediatr Surg* 1999;34:420-3.
- Schier F: Laparoscopic surgery of inguinal hernias in children: initial experience. *J Pediatr Surg* 2000;35: 1331-5.
- Gorsler CM, Schier F: Laparoscopic herniorrhaphy in children. *Surg Endosc* 2003;17:571-4.
- Schier F, Montupet P, Esposito C: Laparoscopic inguinal herniorrhaphy in children: a three-center experience with 933 repairs. *J Pediatr Surg* 2002;37: 395-7.
- Baniaghbal B, Al-Hindi S and Davies MRQ: Laparoscopic-Assisted Percutaneous Inguinal Hernia Closure in Children. *Pediatr Endosurg Innov Techn* 2004;8(2):113-8.
- Hamad MA, Osman MA, Abdelhamed M: Laparoscopic-assisted percutaneous internal ring ligation in children. *Ann Pediatr Surg* 2011;7(2): 66-9.
- Endo M, Ukiyama E: Laparoscopic closure of patent processus vaginalis in girls with inguinal hernia using a specially devised suture needle. *Pediatr Endosurg Innov Tech* 2001;5:187-91.
- Becmeur F, Philippe P, Lemandat-Schultz A, Moog R, Grandadam S, Lieber A, Toledano D: A continuous series of 96 laparoscopic inguinal hernia repairs in children by a new technique. *Surg Endosc* 2004;18:1738-41.
- Harrison MR, Lee H, Albanese CT, Farmer DL: Subcutaneous endoscopically assisted ligation (SEAL) of the internal ring for repair of inguinal hernias in children: a novel technique. *J Pediatr Surg* 2005;40:1177-80.
- Patkowski D, Czernik J, Chrzan R, Jaworski W and Apoznanski W: Percutaneous internal ring suturing: a simple minimally invasive technique for inguinal hernia repair in children *J Laparoendosc Adv Surg Tech* 2006;16(5):513-7.
- Endo M, Watanabe T, Nakano M, Yoshida, Ukiyama E: Laparoscopic completely extraperitoneal repair of inguinal hernia in children: a single-institute experience with 1,257 repairs compared with cut-down herniorrhaphy. *Surg Endosc* 2009;23:1706-12.
- Chan KL, Hui WC, Tam PKH: Prospective, randomized, single-center, single-blind comparison of laparoscopic vs. open repair of pediatric inguinal hernia. *Surg Endosc* 2005;19:927-32.
- Prasad R, Lovvorn HN, Wadie GM, et al: Early experience with minimally invasive inguinal herniorrhaphy in children. *J Pediatr Surg* 2003;38:1055-8.
- Dutta S and Albanese C: Transcutaneous laparoscopic hernia repair in children: a prospective review of 275 hernia repairs with minimum 2-year follow-up *Surg Endosc* 2009;23:103-7.
- Yip KF, Tam PKH, Li MKW: Laparoscopic flip-flap hernioplasty: an innovative technique for pediatric hernia surgery *Surg Endosc* 2004;18:1126-9.