

# Confocal Laser Endomicroscopy in Diagnostics of Complications of Gastroesophageal Reflux Disease in Children

Anton Andreevich Shavrov<sup>1\*</sup>  
 Igor Vitalevich Kirgizov<sup>1</sup>  
 Andrey Alexandrovich Shavrov<sup>1</sup>  
 Anastasiya Yurevna Kharitonova<sup>1</sup>  
 Alexander Gavrilovich Talalaev<sup>2</sup>  
 Galina Vasilevna Volynets<sup>3</sup>  
 Sergei Germanovich Khomeriki<sup>4</sup>

<sup>1</sup>Department of Endoscopy, FSBI "Scientific Center of Children's Health," RAMS, (119991, Moscow, Lomonosovsky prospect, 2, build. 1) Moscow, Russia

<sup>2</sup>Pathological Laboratory, FSBI "Scientific Center of Children's Health" Moscow, Russia

<sup>3</sup>Department of Gastroenterology with a hepatological group, FSBI "Scientific Center of Children's Health" Moscow, Russia

<sup>4</sup>Pathological Laboratory, Central Institute of Gastroenterology, Moscow, Russia

Correspondence to:

**Anton Andreevich Shavrov**  
 Department of Endoscopy,  
 FSBI "Scientific Center of Children's  
 Health," RAMS, (119991, Moscow,  
 Lomonosovsky prospect, 2, build. 1)  
 Moscow, Russia  
 E-mail: Shavrovnczd@yandex.ru

## Summary

Twenty-nine children with suspected gastroesophageal reflux disease (GERD) and 17 children as a reference group were enrolled in the study. A conventional white light endoscopy of the oesophagus was supplemented by a probe-based confocal laser endomicroscopy (pCLE) and followed by a biopsy for histological examination. A comparative analysis of endoscopic, endomicroscopic, and histological data were performed. The pCLE allows detecting oesophagitis with the sensitivity and specificity of 93% and 94%, respectively; gastric and intestinal metaplasia typical for Barrett oesophagus with 83% and 100%, respectively; and polyps of the cardioesophageal passage with the sensitivity of 89% in patients with long-term GERD. Thus, this method allows taking an optical biopsy of pathological changes of esophageal mucosa just during the standard endoscopic investigation.

**Key words:** Confocal laser endomicroscopy; Gastroesophageal reflux disease; Polyps of cardioesophageal passage; Pediatrics; Barrett oesophagus; GERD; Children; pCLE.

## INTRODUCTION

Oesophageal diseases are one of the most urgent problems in modern pediatric gastroenterology. Gastroesophageal reflux disease (GERD) and its complications: Barrett oesophagus (BE) and polyps of esophagogastric junction, rate of detection of which has significantly increased in recent years according to literature sources, have the leading place in the structure of oesophageal diseases.<sup>1-3</sup> At the same time, the number of publications devoted to the diagnostics of BE in children is not great, and the true morbidity rate has not been yet known.

An interest in BE and adenomatous polyps among adult patients is caused by a high level of adenocarcinoma diagnosed at an incurable stage of the disease. For this reason, attention shall be focused on the early diagnostics of dysplasia of the esophageal mucosa. The development of new technologies in intra-luminal endoscopy, such as narrow-band imaging and high resolution endoscopy, allows improving the diagnostics of these lesions; however, one does not rule out the necessity of taking biopsy for histological confirmation of the diagnosis, evaluating the efficacy and duration of drug therapy, the need for surgical correction, and the duration of follow-up of patients.<sup>3,4</sup> A method of four-square biopsy performed in every 2 cm in GERD complicated with BE results in additional injuries of the mucosa, psychological stress of a patient, an increase in the required time, and costs associated with histological examination.

Recent engineering achievements have decreased a confocal scanning microscope to a size allowing its insertion through the working channel of a standard flexible endoscope. This technique was called probe-based confocal laser endomicroscopy (pCLE), and it allows endoscopists receiving a real-time histological image of the mucosa or its optical biopsy. However, significance of pCLE in the evaluation of treatment results in paediatric GERD has not been yet defined.

## MATERIALS AND METHODS

Twenty-nine children (19 girls and 10 boys) from 3 to 18 years old (average age:  $11.6 \pm 3.6$  years old) with suspected GERD, treated at the Gastroenterological, Nephrological, and Surgical Department of FSBI "Scientific Center of Children's Health", RAMS, were enrolled in the study. Heartburn, belching, pain syndrome, dysphagia, and hiccup were the leading clinical symptoms of GERD in all children. Reference group include 17 children with normal oesophageal mucosa (EM). All children were examined endoscopically supplemented with target biopsies of the EM.

An endoscopic examination of oesophagus and stomach was performed in all 46 children with video endoscope equipment—Fujinon EVE-500 and a video gastroduodenoscopy Fujinon EG450WR5.

Interpretation of endoscopic semiotics typical for oesophagitis was made according to the classification of G. Tytgat in the modification of Privorotskiy.<sup>5</sup> Polypoid masses in the area of a cardioesophageal passage were assessed using the international endoscopic grading of polyps adopted in Stockholm in 1982; according thereto, polyps with a diameter up to 5 mm and more than 5 mm were additionally identified.<sup>6</sup>

An intraluminal examination of EM in all 46 children was supplemented with pCLE. The method is based on the principle of confocal fluorescence microscopy. A laser of a wavelength of 488 nm located on the workstation generates a laser beam and transmits it by means of a multifilament fiberoptic probe conducted through the working channel of the endoscope to the mucosal surface. A part of light is absorbed and the laser-induced fluorescence effect causes tissue light emission defined by a confocal microscope and processed by a computer, allowing obtaining a dynamic monochrome image in the monitor.

The examination was performed by means of confocal laser scanning system Cellvizio® (Mauna Kea Technologies, France) with Gastroflex probes. The pCLE has a display

area of 30,000 pixels and generates 12 frames per second allowing inspection of the mucosa within the field of view of 600  $\mu\text{m}$  and an image depth of 50  $\mu\text{m}$ . UHD probes with the resolution of 50,000 pixels are used to obtain images with higher resolution in order to visualize a micro blood vessels of the mucosa. All of them may be introduced through the working channel of an endoscope with a minimum size of 2.2 mm, which allows using an overwhelming majority of flexible endoscopes. It is important to adjust the equipment in accordance with the instruction, to calibrate the probe and prepare it for operation. The optimal time for obtaining the image of the highest quality is the first 8–10 min after contrast injection, however, interpretable images can be obtained even after 60 min after contrast injection.<sup>7</sup> In order to minimize such artifacts as vascular leak and minimal tissue damage, the probe shall be carefully contacted with the mucosal surface without excessive pressure or injure of tissue, and the most optimal position of the probe shall be considered the one perpendicular to the surface of the mucosa. Maintaining a stable position of the probe is crucial in getting high-quality picture. Microscopic images can be recorded and replayed for a detailed analysis. It should be noted that confocal images differ from standard histological specimens, as they do not have a longitudinal orientation of sections, more familiar to the morphologists, but a horizontal one.

A disinfection of the probes is performed with solutions used in automatic reprocessors similarly to the high level disinfection of the endoscopes. Taking into account the increase in the duration of the diagnostic procedure within the range of 15 to 30 min and maintaining probe stability for good image acquisition, the procedure should be performed under sedation or general anaesthesia.

It is important to note that intravenous administration of a contrast agent is necessary to obtain high-contrast images in confocal endomicroscopy, e.g., a 10% fluorescein sodium solution commonly used in diagnostic practice in adult patients. Once in the bloodstream, it is rapidly bound to serum albumins, distributed through capillaries, enters tissues and stains surface epithelium cytoplasm, membrane, crypts, cell infiltration, and blood vessels. The nucleus and mucin are not stained and seem to be dark.

Serious side effects of fluorescein such as allergic reactions (including anaphylaxis), cardiac and/or pulmonary insufficiency are extremely rare and have not been registered in confocal endomicroscopy. The most common side effects were short-term icteritiousness of skin and a bright yellow

urine colour, which completely disappeared within 2–6 hours.<sup>7–9</sup>

According to the recommendations on the drug usage, the decision of the Local Ethics Committee of our centre, and approval of the members of the Academic Council of FSBI “Scientific Center of Children’s Health”, RAMS, we used the intravenous administration of a 10% fluorescein sodium solution at the dose of 5 mg/kg of body weight. Children with allergic reactions, as well as those with severe liver and kidney diseases were excluded from this study. Short-term icteritiousness of skin and a bright yellow urine colour, which completely disappeared within 2 hours after the administration of the drug, were observed as side effects.

The interpretation of the obtained pCLE images was carried out according to the Miami classification (2008) for adult patients.<sup>10</sup>

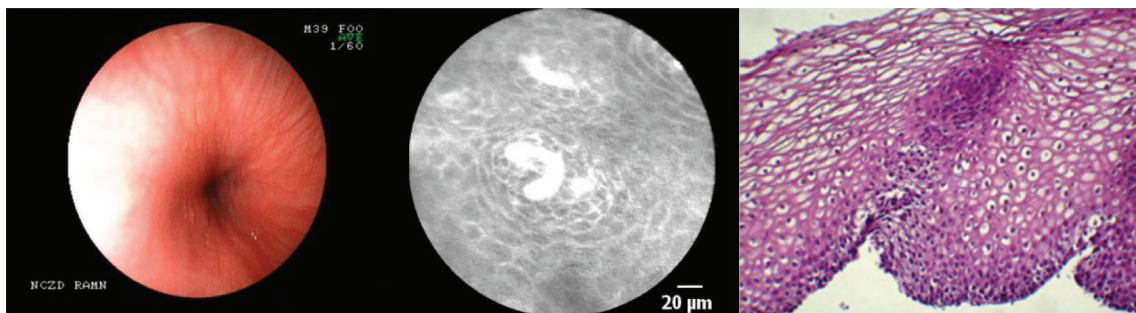
Traditional white light endoscopy with the pCLE was supplemented with biopsy of the EM in all 46 children. Polyps >5 mm size with the endomicroscopic criteria of adenomatous transformation was an indication for endoscopic electroexcision of the polyp with polypectomy loop. A microscopic examination of EM biopsy and removed polyps was performed at the Pathology Laboratory of FSBI “Scientific Center of Children’s Health”, RAMS. Biopsy material was

retained in 10% formalin solution. Standard histological sections were made, and then they were stained with hematoxylin and eosin and the PAS reaction. Detected changes were evaluated according to the conventional histological criteria, highlighting the inflammation activity, gastric or intestinal metaplasia, presence of erosions and ulcers.

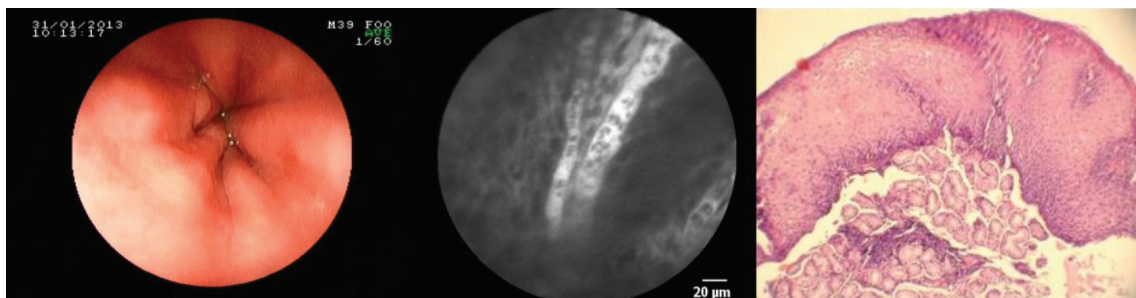
## RESULTS AND DISCUSSION

The endoscopic semiotics of the esophageal mucosa was conducted according to the proposed classification, and inflammatory changes of EM were observed in 20 (43.4%) of the 29 children with suspected GERD. Oesophagitis of Grade I was observed in 7 (35.0%) patients, Grade II - in 4 (20.0%) patients, Grade III - in 1 (5.0%) patient, and Grade IV - in 8 (40.0%) patients. Polypoid masses of the esophagogastric passage were found in 9 children (19.5%), of which polyps <5 mm were detected in 5 children, and >5 mm were observed in 4 patients.

Confocal endomicroscopy of the normal EM showed squamous cells without villi or crypts and bright colored intrapapillary loops (Fig. 1). In case of inflammatory changes a failure of acuity of a squamous epithelial cell structure, an increased vascularity with ecstatic and tortuous vessels and cellular infiltration were observed (Fig. 2). Regular colum-



**Figure 1:** Left to right: Endoscopic, endomicroscopic, and histological (microscopic pictures of Prof. MD, SG Khomeriki) images of the normal esophageal mucosa.



**Figure 2:** Left to right: Endoscopic, endomicroscopic, and histological (microscopic pictures of Prof. MD, SG Khomeriki) images of the inflammatory changes of esophageal mucosa.

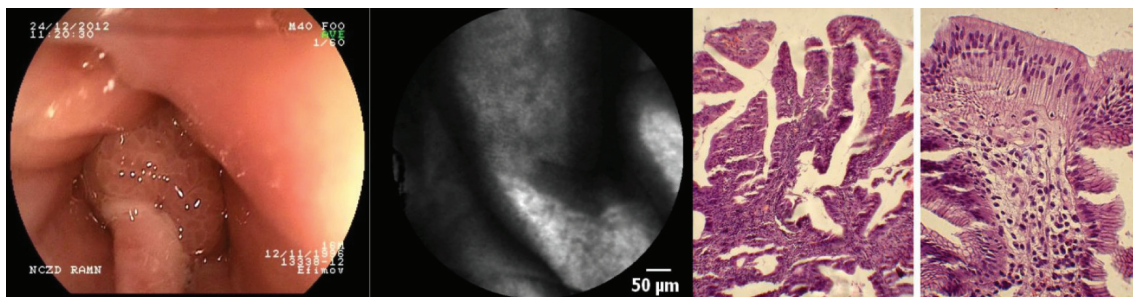


nar-lined epithelium with round and regular gastric glands, and inflamed, ectatic blood vessels corresponds to gastric metaplasia (Fig. 3). BE is represented by villi-like structures with regular columnar-lined epithelium and dark coloured goblet cells (Fig. 4). Hyperplastic polyps were characterized by a typical narrow, slit-like or star-shaped lumen of crypts, regularity of crypts and epithelium, and vessels decreased in diameter (Fig. 5). In case of adenomatous polyps, villi-like structures of irregular shape (even in tubular adenomas), dark irregularly thickened epithelium, and dark colored goblet cells were observed (Fig. 6).

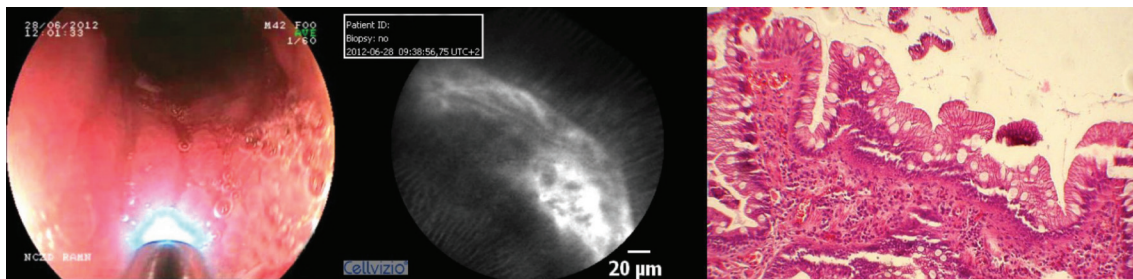
According to the pCLE data, esophagitis was observed in 15 children (32.6%), gastric metaplasia in 2 children (4.3%),

intestinal metaplasia in 5 children (10.8%), hyperplastic polyps in 6 children (13%), and adenomatous polyps in 2 patients (4.3%).

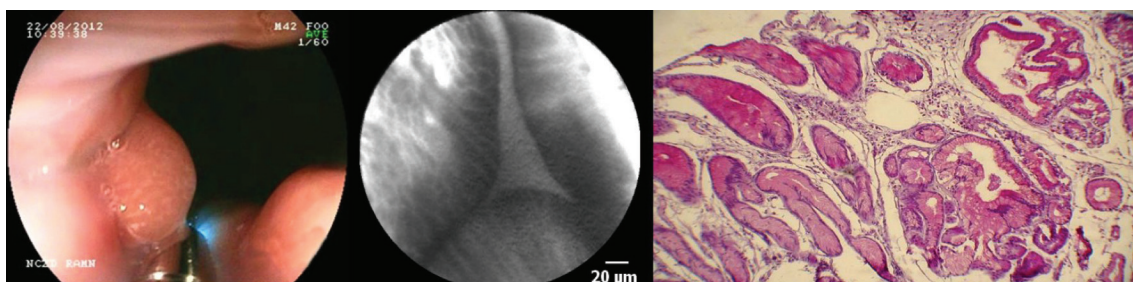
A microscopic examination of biopsy specimens of the normal EM showed a multilayered squamous epithelium of oesophagus with mucous glands (Fig. 1). Inflammatory changes of EM were accompanied by mucosal capillary ectasia (“vascular lakes”), increase of cellular infiltration (neutrophils, lymphocytes, eosinophils > 6/biopsy sample), presence erosions and balloon cells with swollen cytoplasm and pyknotic nuclei (Fig. 2). Gastric metaplasia was characterized by differentiated gastric tissue with chief cells and parietal cells (Fig. 3). BE was represented by the presence of glan-



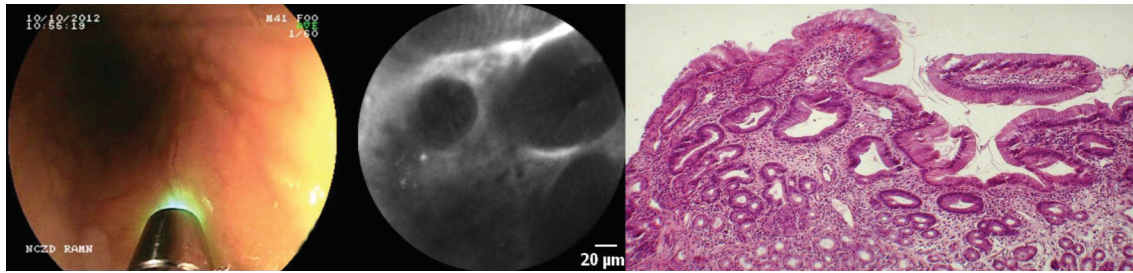
**Figure 3:** Left to right: Endoscopic, endomicroscopic, and histological (microscopic pictures of Prof. MD, SG Khomeriki) images of the gastric metaplasia.



**Figure 4:** Left to right: Endoscopic, endomicroscopic, and histological (microscopic pictures of Prof. MD, SG Khomeriki) images of the Barrett's oesophagus.



**Figure 5:** Left to right: Endoscopic, endomicroscopic, and histological (microscopic pictures of Prof. MD, SG Khomeriki) images of the hyperplastic polyp.



**Figure 6:** Left to right: Endoscopic, endomicroscopic, and histological (microscopic pictures of Prof. MD, SG Khomeriki) images of the villous adenoma.

dular epithelium with goblet cells (Fig. 4). Hyperplastic polyps were characterized by edematous lamina propria with mixed inflammatory infiltrate, evident crypt elongation, branching and cystic dilatation of foveolae (Fig. 5). Fragments of glandular tissue and villous structures with columnar epithelium and mild lymphoplasmacytic infiltration in lamina propria were observed in adenomatous polyps (Fig. 6). Dysplasia or neoplasia were not found during research.

Histologically oesophagitis was confirmed in 14 children (23.9%), gastric metaplasia in 2 children (4.3%), intestinal metaplasia in 4 children (8.7%), hyperplastic polyps in 7 children (15.2%), and adenomatous polyps were found in 2 children (4.3%).

Only the microscopic examination of biopsy specimens is considered to be “the gold standard” in evaluation of the EM structure in gastric metaplasia, BE, hyperplastic, and adenomatous polyps. For determination of the pCLE sensitivity and specificity, we compared the results of histological and endomicroscopic methods (Table 1).

This study showed that pCLE is able to detect oesophagitis with sensitivity of 93% and specificity of 94%, gastric metaplasia and BE with 83% and 100%, respectively.

A confocal endomicroscopy showed sensitivity of 89% in diagnostics of polyps of an oesophagogastric junction. Until

**Table 1:** Structure of EM changes detected by pCLE and histological examination

Esophageal changes	pCLE	%	Histology	%
Normal EM	16	34.7	17	36.9
Oesophagitis	15	32.6	14	23.9
Gastric metaplasia	2	4.3	2	4.3
Intestinal metaplasia	5	10.8	4	8.7
Hyperplastic polyps	6	13.0	7	5.2
Adenomatous polyps	2	4.3	2	4.3

recently, the only reliable method of differentiate diagnosis between adenomatous and hyperplastic polyps has been performing a histological examination after their removal. Detection of confocal criteria of the adenomatous polyp was an indication for an endoscopic electroexcision of the polyp. This method allows differentiating adenomatous and hyperplastic polyps and using an approach of a single-step diagnostics and removal without histological confirmation.

Confocal endomicroscopy may become one of the leading methods in gastroenterology, as it allows endoscopists examining the mucosa at the cellular level during the procedure and may help to determine the diagnosis. In contrast to the histological examination of EM, where biopsy samples are limited by sizes of the specimens, pCLE not only provides *in vivo* data on its inflammatory activity, but also gives the opportunity to inspect its surface on longer sections, as well as perform an unlimited number of optical biopsy without injury of the EM. The ability of the pCLE to differentiate normal, metaplastic and dysplastic EM during the standard white light endoscopy helps in determining the histological diagnosis and making a decision on the necessity of submucosal dissection, an evaluation of the drug therapy efficacy and the duration of follow-ups for patients. This shall allow avoiding unnecessary biopsies eliminating the risks of complications, which is very important in paediatric practice, reducing the time to make a decision for further treatment of the patient and reducing the burden on histologist.

## References

1. Baranov AA, Klimanskaya EV, Rimarchuk GV. Pediatric gastroenterology (selected chapters). Moscow; 2002. 592 p. (in Russian).
2. Erdes SI, Sergeeva TN, Mukhametova EM. Daily pH monitoring in children and teenagers with polyps of cardioesophageal passage. *Pediatriya* 2008;6:42–6. (in Russian).
3. Kharitonova A Yu, Smirnov IE, Shavrov AA et al. Modern technologies of endoscopic diagnosis of erosive and ulcerative

- lesions of the upper gastrointestinal tract in children. *Rossiiskij Pediatricheskij Zhurnal*. 2010;5:14–17 (in Russian).
4. Kharitonova A Yu, Shavrov AA, Smirnov IE et al. Narrow band imaging endoscopy in diagnosis of gastric and duodenal mucosa destructive changes in children. *Rossiiskij Pediatricheskij Zhurnal*. 2012;6:29–32 (in Russian).
  5. Privorotskiy VF, Lupnova NE. GERD in children (draft standards for diagnosis and treatment). *Matrialy XIV kongressa detskih gastroenterologov Rossii. Aktualnie problemi abdominalnoi patologii u detei*. Moscow; 2007. pp. 75–90.
  6. Lazebnik LB, Scherbakov PL. *Gastroenterology*. Moscow: *Izdaniye Meditsinskih Knig*; 2011. 357 p (in Russian).
  7. Becker V, Von Delius S, Bajbouj M, Karagianni A, Schmid RM, Meining A. Intravenous application of fluorescein for confocal laser scanning microscopy: evaluation of contrast dynamics and image quality with increasing injection-to-imaging time. *Gastrointest Endosc*. 2008;68(2):319–23.
  8. Wallace MB, Meining A, Canto MI, Fockens P, Miehke S, Roesch T et al. The safety of intravenous fluorescein for confocal laser endomicroscopy in the gastrointestinal tract. *Aliment Pharmacol Ther*. 2010;31(5):548–52.
  9. Venedictova MM, Shavrov AA. Confocal laser endomicroscopy in diagnostics of inflammatory bowel diseases in children. *Voprosy diagnostiki v pediatrii*. 2012;4:17–21. (in Russian).
  10. Wallace MB, Lauwers GY, Chen Y, Dekker E, Fockens P, Sharma P, Meining A. Miami classification for probe-based confocal laser endomicroscopy. *Endoscopy*. 2011;43(10):882–91.