

Laparoscopic Pericardectomy for Post-cardiac Surgery Recurrent Pericardial Effusion

Prakash Agarwal^{1*}
R.K. Bagdi¹
Neville Solomon²

¹Department of Pediatric Surgery
Apollo Children's Hospital,
Chennai, India

²Department of
Cardiothoracic Surgery,
Apollo Children's Hospital
Chennai, India

*Correspondence to:

Professor Prakash Agarwal
F 31, H block, Jains Avantika Apartments,
Manapakkam, Chennai – 600116 (INDIA)
Phone: +91-9840114749
E mail: agarwal_prakash@hotmail.com

Abstract

We present a unique case of a 10-year-old girl who was a known case of congenital heart disease. She underwent Rastelli procedure twice for the same problem, but developed pericardial effusion in the postoperative period following which pericardiocentesis was done. She developed recurrent pericardial and pleural effusion, was not responding to drainage and pleurodesis. The pericardial effusion was endangering the surgical outcome of the previous surgery. Since she had multiple entry site scars and repeated pericardiocentesis with pleurodesis, thoracotomy with pericardectomy seemed to be a less viable option. We subjected the patient to a minimally invasive method of treatment by doing a laparoscopic trans-diaphragmatic pericardectomy. The details of the procedure and our experience with management of the case are highlighted. In cases of repeated pericardial effusion failing conservative management, laparoscopic pericardectomy seems to be a less invasive and more viable option.

INTRODUCTION

Surgical management of massive pericardial effusion is usually performed by a left anterior thoracotomy, median sternotomy, subxiphoid approach,¹ or more recently by video-assisted approach.²

The recent evolution in minimally invasive treatment of pericardial effusion and cardiac tamponade has led to the development of different methods of accessing the pericardium. Although several successful techniques in conventional surgery exists, laparoscopy offers definite advantage over these techniques, especially in the treatment of recurrent and malignant effusion.³

CASE REPORT

A 10-year-old girl was referred by the paediatric cardiothoracic surgery team for recurrent pericardial and pleural effusion not responding to repeated pericardiocentesis and pleurodesis. She had congenital heart disease and underwent Rastelli procedure 1 year back and redo Rastelli procedure 1 month back.

On examination she had mild pallor and clubbing. She was not cyanotic and her vital parameters were normal. On examining her cardiovascular system, it was found that she had normal 1st and 2nd heart sound, she had a holosystolic murmur (4/6) over the left sternal border, and increased jugular venous pressure. On examining her respiratory system, her air entry and vocal resonance were decreased on both side bases. Except for low haemoglobin her other blood investigations were

normal. An echocardiography done was suggestive of pericardial effusion with septations and pleural effusion on the right side.

The pericardial effusion was endangering the surgical outcome of the previous surgery. Since she had multiple entry site scars and repeated pericardiocentesis and pleurodesis, thoracotomy with pericardectomy seemed to be a less viable option. We subjected the patient to a minimally invasive method of treatment by doing a laparoscopic transdiaphragmatic pericardectomy.

The patient was placed in a modified Lloyd-Davis position with the surgeon standing between the patient's leg, assistant to the left, and scrub nurse to the right of the surgeon. Monitor was placed at the head end of the patient. Central venous pressure was measured through a Jugular venous catheter which allows monitoring of the right cardiac filling pressure, before, during, and after creation of the pericardial window. A 10-mm supraumbilical Hasson's trocar was introduced and pneumoperitoneum was created. A 0° 10-mm scope was used and the patient was put in a further 10–20° anti-Tredelenburg tilt. Two 5-mm ports at the left hypochondrium and epigastrium were introduced for the working ports and a 5-mm port was introduced in the left flank to retract the left lobe of liver (Figure 1).

Meticulous dissection of the tendinous portion of the diaphragm was started to the left of the hepatic falciform ligament, with a grasper from the right trocar and a unipolar hook electrode from the left trocar. Care was taken to dissect the various anatomical layers i.e., the peritoneum, the tendinous portion of the diaphragm, and the pericardium was opened with sharp dissection under constant endo-esophageal sonography by the anaesthetist guiding us regarding the area with maximal fluid collection. As the patient was in the supine position most of the fluid was collected in the space between the posterior aspect of the heart and paravertebral space. At the opening of the pericardium, brownish coloured fluid gushed out (Figure 2), which was collected and sent for biochemical analysis and microbiological culture. The pericardial cavity was sucked out of all the fluid and the cavity entered with the telescope. All intervening strands and septae were broken with the suction canulae. A 3 × 3 cm pericardial-peritoneal window was created (Figure 3). The excised margin was sent for histopathology. Port site wounds were closed. A right intercostal drain was inserted to drain about 500 ml of serous fluid.

Patient was started on orals within 12 hours and discharged on the fourth postoperative day after removing

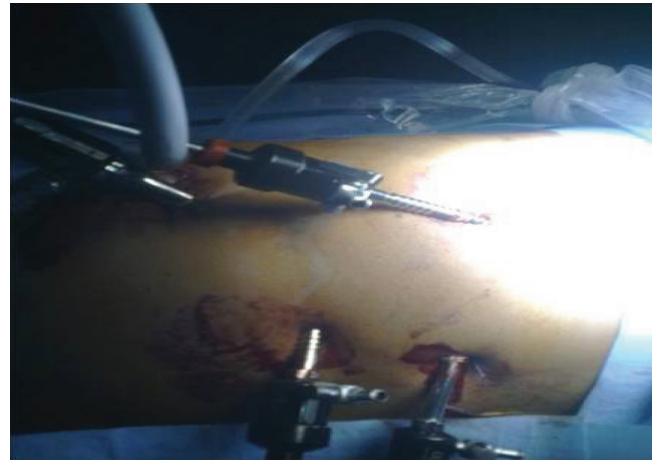

Figure 1: Port placement for pericardectomy

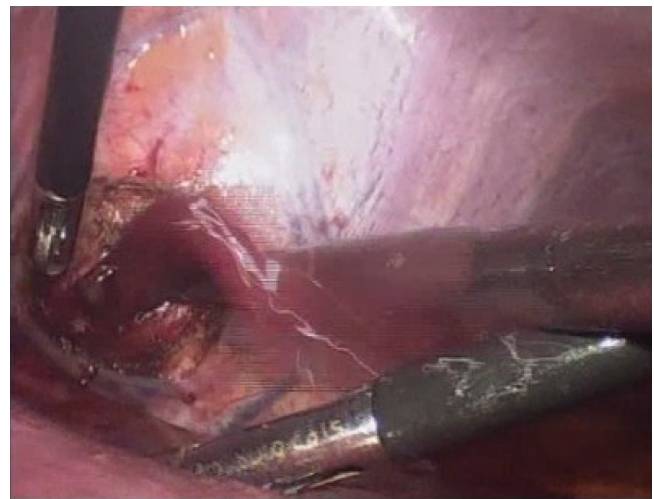


Figure 2: Pericardial fluid gushing out of the pericardial cavity after incision

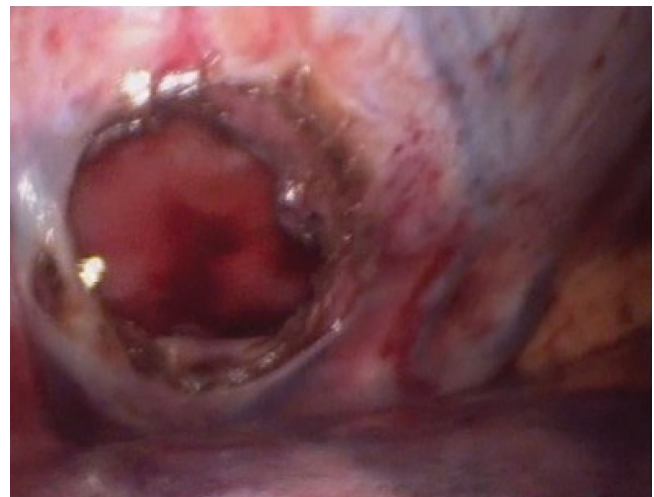


Figure 3: Operative view of pericardectomy window done through diaphragm

the intercostal tube drain. The fluids did not grow any organism and biochemical analysis was suggestive of a transudate.

On follow-up all her cardiac and respiratory signs had normalized and biopsy of the pericardiectomy specimen showed features of chronic inflammation and fibrosis. Repeat echocardiography showed total resolution of the fluid collection in the pericardial space. She became totally symptom free on 6 months follow-up.

DISCUSSION

The surgical indication and techniques for treatment of recurrent pericardial effusion with impending life threatening cardiac tamponade are still debated.⁴ The effusion may be drained either extrasomatic or into the intrapleural space. Extrasomatic drainage includes minimally invasive subxiphoid pericardial drainage. Surgical drainage into the intrapleural space involves an invasive thoracotomy, median sternotomy, a minimally invasive video-assisted thoracoscopic surgery (VATS) procedure, or more recently transdiaphragmatic pericardial decompression.

The classical subxiphoidal pericardial fenestration can be regarded as the first real minimally invasive technique. When this technique is performed under local anaesthesia, a good decompression and pericardial biopsy can be obtained. In our case a tube pericardiostomy was done subxiphoid which recurred after removing the tube.

VATS met initial enthusiasm for combined exploration of the thoracic cavity and the creation of pericardial fenestration. This may be still considered as the major advantage offered by this technique in the treatment and diagnosis of extended lung or pleural malignancies. In our patient, the option of VATS was not feasible as she had pleurodesis for recurrent pleural effusion.

Laparoscopic approach to the pericardium for relief of pericardial tamponade was described initially by Ready et al.⁵ for the treatment and diagnosis of pericardial effusions in

patients with malignant disease. Creation of a pericardial window provides a clear advantage over VATS because the resorptive capacity of the diseased pleura is not large enough for rapid clearance of the drained pericardial effusion.⁵ In contrast, the resorptive capacity of the peritoneal cavity offers fast and continuous resorption of the effused pericardial fluid. Resting fluid accumulations are small and the risk of formation of localized collection is small.⁵

By using the transabdominal pericardial window, a new algorithm and policy has been introduced in the treatment of recurrent pericardial effusion. When drainage aspiration proves insufficient, creation of such a transabdominal transdiaphragmatic pericardio-peritoneal fistula offers both the best result and benefits of a safe and simple surgical technique.

ACKNOWLEDGEMENTS

The authors sincerely acknowledge Dr. Swapna, Cardiac Anaesthetist and Dr. Muthukumar, Paediatric cardiologist in managing the patient excellently during the intra-operative and postoperative periods.

References

1. Mack MJ, Landreneau RJ, Hazelrigg SR, Acuff TE. Video thoracoscopic management of benign and malignant pericardial effusion. *Chest* 1993;103:390S–93S.
2. So T, Nakanishi R, Kohno H, Oe M, Yasumoto K. Video assisted thoracoscopic pericardiectomy for severe pericardial effusion. *J Cardiovasc Surg.* 1999;40:311–2.
3. Totte E, Hee van R, Brabant van P, Wollaert B, Gheuens E, Declerck S, Leys J, et al. Laparoscopic transabdominal pericardial window. New standard in the management of recurrent pericardial effusion complicated by cardiac tamponade. *Surg Endosc.* 2002;16: 859–63.
4. Helms SR, Carlson MD. Cardiovascular emergencies. *Semin Oncol.* 1989;16:463–7.
5. Ready A, Black J, Lewis R, Roscoe B. Laparoscopic pericardial fenestration for malignant pericardial effusion. *Lancet* 1992;339:1609 (letter).