



Tubercular Lesions in Brain Parenchyma

Forhad Hossain Chowdhury¹, Nur Mohammad², Mohammad Raziul Haque³, Zahed Hossain⁴,
Md. Abdus Salam⁵, Mainul Haque Sarker⁶

¹Assistant Professor, Department of Neurosurgery, National Institute of Neurosciences and Hospital, Dhaka, Bangladesh; ²Senior Consultant, Department of Radiology & Imaging, Comilla Medical College & Hospital, Comilla, Bangladesh; ³Associate Professor, Department of Neurosurgery, Dhaka Medical College, Dhaka, Bangladesh; ⁴Associate Professor, Department of Neurosurgery, National Institute of Neurosciences and Hospital, Dhaka, Bangladesh; ⁵Associate Professor, Department of Neurotrauma, National Institute of Neurosciences and Hospital, Dhaka, Bangladesh; ⁶Ex-Professor, Neurosurgery, Dhaka Medical College and Hospital, Dhaka, Bangladesh

[Received: 7 March 2018; Accepted: 20 May 2018; Published: 1 December 2018]

Abstract

Background: Preoperative neuro-radiological features of tuberculosis involving brain lesions may mimic neoplastic lesions of brain & skull base and post operative histopathological study or response to empirical anti-tubercular therapy brings the ultimate diagnosis. **Objective:** Here we present our experience of 76 cases of cerebral and cerebellar tuberculosis that was managed surgically with anti-tubercular drugs or medical treatment alone without histopathological confirmation. **Methodology:** All cases of brain parenchymal tuberculosis confirmed histopathologically after surgery or confirmed by successful conservative treatment with anti-TB from January 2008 to June 2015 were included for study. Tubercular meningitis was excluded from the study. Patients underwent some form of surgery that confirmed the tuberculosis by histopathologically. Patients with suspected tubercular lesion in brain were treated empirically with antiTB. Post operative imaging was done with CT scan of brain or MRI of brain in immediate post operative period, six months after operation and 18 months after operation. **Results:** 34 patients underwent surgery to confirm the tuberculosis and 44 patients with suspected tubercular lesion in brain were treated empirically with antiTB of which 40 patients responded successfully and rest 4 patients did not respond and underwent surgical excisional biopsy. Common clinical features include features of raised ICP with focal signs and symptoms. Concurrent other systemic tuberculosis was found in three cases. One patient had history of full course anti-tubercular therapy for pulmonary tuberculosis 20 years back. **Conclusion:** In suspected TB lesions, conservative treatment without histopathological diagnosis may be adopted with ultimate same result. [*Bangladesh Journal of Infectious Diseases, December 2018;5(2):45-60*]

Keywords: Brain Parenchyma; tubercular lesion; cerebral tuberculoma; tubercular abscess

Correspondence: Dr Forhad Hossain Chowdhury, Assistant Professor, Department of Neurosurgery, National Institute of Neurosciences & Hospital, Agargaon, Sher-E-Bangla Nagar, Dhaka-1207, Bangladesh; Cell no.: +8801711949570; Email: forhadchowdhury74@yahoo.com

Conflict of interest: There is no conflict of interest to any of the authors of this article.

Funding agency: The study was not funded by any authority.

Contribution to authors: Khan N, Rahman F conceived and designed the work, sample collection and Jahan N, Hafez F, Akter S prepared the manuscript. Mohammad N, Khatun R have revised the manuscript.

How to cite this article: Chowdhury FH, Mohammad N, Haque MR, Hossain Z, Salam MA, Sarker MH. Tubercular Lesions in Brain Parenchyma. Bangladesh J Infect Dis 2018;5(2):45-60

Copyright: ©2018. Chowdhury et al. Published by Bangladesh Journal of Infectious Diseases. This article is published under the Creative Commons CC BY-NC License (<https://creativecommons.org/licenses/by-nc/4.0/>). This license permits use, distribution and reproduction in any medium, provided the original work is properly cited, and is not used for commercial purposes.

Introduction

Number of tuberculosis (TB) patients are increasing throughout the world, so central nervous system (CNS) TB is also increasing¹. Prevalence of TB is 8 cases per 100,000 annually, in the United States of America. According to the World Health Organization report, there is 8–10 million new cases of TB are diagnosed in the world annually. The prevalence of tuberculosis varies in different geographical areas, age groups and socio-economical groups². HIV infection³, intravenous drug use, immunosuppression from increasing age, alcoholism, malnutrition, poverty, transplantation, aggressive chemotherapy, immigration⁴, homelessness and crowding are the predisposing factors for tuberculosis. The CNS involvement occurs approximately 10.0 to 15.0% of all tuberculous infections in the body⁵ and is commonly seen in the third world countries.

Tubercular lesions can occur at any site in the brain². In the late 80s, the rate of TB increased mostly due to HIV infection in countries where TB is common and endemic especially in Africa and Asia with high mortality and morbidity⁶. In endemic areas CNS TB is considered to follow the ten percent rule⁶. There are an estimated 10 million new cases of TB worldwide, nearly 10.0% of all patients' with TB tend to have CNS involvement either as tuberculous meningitis (TBM) or as intracranial tuberculomas and till date the reported literature suggested that the two conditions may co-exist in up to 10.0% of patients. In endemic areas, 10.0% of all intracranial space occupying lesions are tuberculomas and the mortality of intracranial tuberculomas has also been reported at around 10.0%. Almost 70.0% of patients have multiple tuberculomas⁷.

Methodology

All cases of brain parenchymal tuberculosis confirmed histopathologically after surgery or confirmed by successful conservative treatment with anti-TB from January 2008 to June 2015 were included for study. Tubercular meningitis [TBM] was excluded from the study. Follow up period is 9 months to 84 months (average 18.5 months) after completion of drugs therapy. 34 patients underwent some form of surgery that confirmed the tuberculosis by histopathologically. 44 patients with suspected tubercular lesion in brain were treated empirically with anti-TB and 40 patients responded successfully and rest 4 did not respond and underwent surgical excisional biopsy (2 were tuberculosis but MDRT and remaining two were

aspergiloma & were excluded from the study). In all cases complete blood count and x-ray chest were done. CSF study, acid fast bacilli identification in CSF, culture of CSF or biopsy material for *Mycobacterium* or PCR for *Mycobacterium* were not done in any case after having histopathology report. In three cases where there were concurrent clinical meningitis, we did surgical excision of big lesions in brain without doing CSF study. PCR was done in all initial conservatively treated cases (42 cases). PCR was positive in 39(92.8%) cases and negative in 03 cases; in PCR negative cases trial anti TB were given due to strong suspicion of TB on radio-images and these 03 patients responded well with anti TB. Among the 39 patients with PCR positive 37 responded with anti TB and rest of the two cases were proved to be MDR TB after excisional biopsy. All patients received standard anti-tubercular therapy for a period of 18 months with a screening for HIV infection and followed up clinically at three months interval. Post operative imaging was done with CT scan of brain or MRI of brain in immediate post operative period, six months after operation and 18 months after operation. In the conservatively treated patients, follow up images done on 1.5 month, on six months and on eighteen months. All recorded data in the way of management of these patients were studied retrogradely.

Result

A total numbers of 76 cases were recruited for this study. Total number of surgically treated was 36 cases (34 plus 2 anti-TB nonresponsive patient) and conservatively treated were 40 cases (2 initial conservatively treated nonresponsive patient needed surgery). Thirty five were female and 41 were male; age range 1.5 to 68 years. Clinical features, Lobar distribution of tubercular lesions, site distribution, Overall results, indications of surgery in surgically treated cases, complications related to surgery and extent of surgical resection are shown in Table 1 to 7 subsequently [Figure I to Xe].

Table 1: Clinical Features of the Patients

Clinical features	Frequency	Percent
Headache	73	96.0
Vomiting	41	54.0
Visual disturbances	21	27.6
Ataxia	17	22.3
Hemiplegia/hemiparesis	31	40.8
Seizure	11	14.5
Aphasia/Dysphasia	08	10.5

Incontinence	06	7.9
Frontal lobe syndrome	05	6.6
Associated meningitis	03	4.0
Ptosis and ophthalmoplegia (Figure V)	01	1.3
Abducent nerve palsy	02	2.6
Movement disorder	00	0.0
Cerebellar signs	05	6.6

Table 2: Distribution according to Location (n=76 cases)

Location	Frequency	Percent
Frontal	08	10.5
Parietal	07	9.2
Temporal	02	2.6
Occipital	03	3.9
Fronto-parietal	16	21.0
Parieto-occipital	11	14.5
Parieto-temporal	09	11.8
All lobes	03	3.9
Posterior fossa	08	10.5
Cerebral plus cerebellar	05	6.6
Brain stem	04	5.2

Table 3: Site (compartmental) distribution (n=76) [Figure I to X]

Site	Percent
Supratentorial	
Telencephalic	32.9
Diencephalic	9.2
Cisternal	7.9
Cisterno-ventricular	5.2
Uni-hemispheric	15.8
Bi-hemispheric	22.3
Cerebro-mesencephalic	2.6
Infratentorial	
Cerebellar uni-hemispheric	3.9
Cerebellar bi-hemispheric	1.3
Cerebello-pontine angle	2.6
Middle cerebellar peduncular	1.3
Cerebello-peduncular	1.3
Supra & infratentorial (Figure II)	
Cerebro-cerebellar(whole brain)	6.6

Table 4: Findings of Different Parameters (n=76)

Variables	Frequency	Percent
Healing of tuberculus lesion after treatment	74	97.3
Recurrence after healing of tubercular lesion	1	1.3

Persistent neurodeficit (Hemiparesis-03, Complete blindness-05)	major	8	10.5
Death		2	2.6
MDR-TB		2	2.6
Multisystem tuberculosis		11	14.5
Immunocompromised (renal transplant)		1	1.3
HIV patient		0	0.0

Table 5: Indications for Surgery (n=36) [Figure IV,V,VII to IX]

Indications	Frequency	Percent
Tuberculoma producing neuro-deficit (weakness, dysphasia, visual impairment)	7	19.4
Tuberculoma in posterior fossa causing triventriculomegaly	7	19.4
Tuberculoma size 3.5 cm or more	10	27.8
Tubercular abscess producing mass affect.	3	8.3
Not responding to anti-TB therapy for 8 weeks or earlier with increasing size of tuberculoma inspite of anti TB therapy	2	5.6
Biopsy for diagnostic purpose without trial antiTB (used only in early part of our experience)	7	19.5

Table 6: Complications related to surgery (n=36)

Complication	Frequency	Percent
Supratentorial		
Seizure	5	13.9
Hematoma(operation site)	1	2.8
Transient new hemiplegia	2	5.6
Transient new dysphasia	1	2.8
Recent memory disturbances	1	2.8
Acute subdural hematoma	1	2.8
Infratentorial		
Unilateral hearing loss	1	2.8
Pseudomeningocele	1	2.8
Chronic discharging	1	2.8

sinus		
Mortality	1	2.8

Table 7: Extent of Excision of Targeted Lesion (n=36)

Extent of Resection	Frequency	Percent
Gross Total Resection	25	69.4
Subtotal Resection	7	19.5
Partial Resection	0	0.0
Only Biopsy	4	11.1
Total	36	100.0

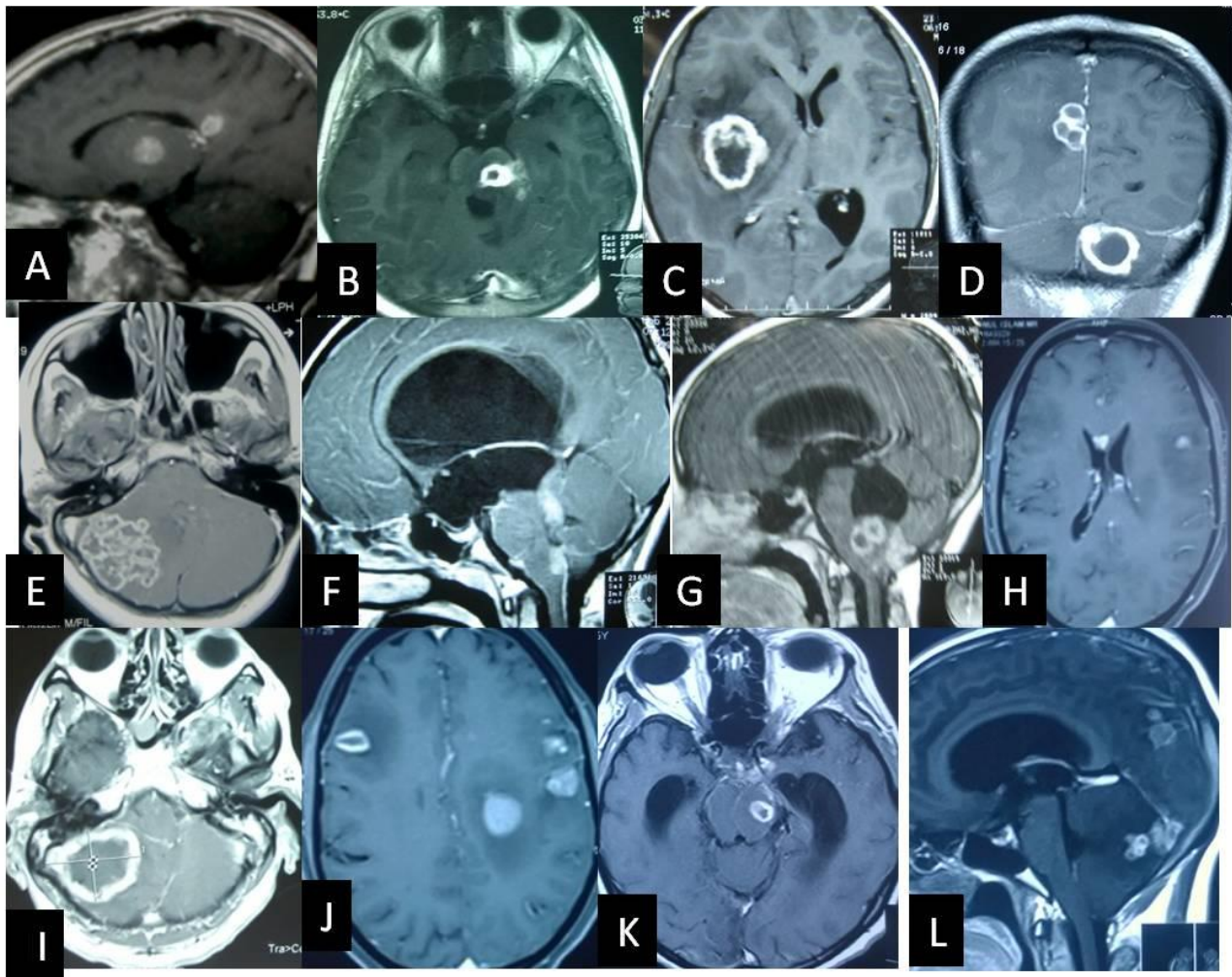


Figure 1: Contrast MRI images in different sections showing tuberculomas in different location. A-Thalamic and splenic tuberculomas. B-brainstem tuberculoma. C-putamino-external capsular tuberculoma, D-Tuberculomas in both supra and infratentorial tuberculomas. E-lateral cerebellar hemispheric tuberculomas. F-tuberculomas in cerebral aqueduct and 4th ventricular outflow with triventriculomegaly. G- tuberculomas at lower 4th ventricle and 4th ventricular outflow causing hydrocephalus. H-small multiple tuberculomas and “Rich foci” in supra tentorial brain parenchyma. I-Lateral cerebellar hemispheric large tuberculoma. J-. Multiple medium size tuberculomas involving both hemisphere. K-tuberculoma of midbrain. L-multiple tuberculomas involving cerebellar vermis and occipital lobe

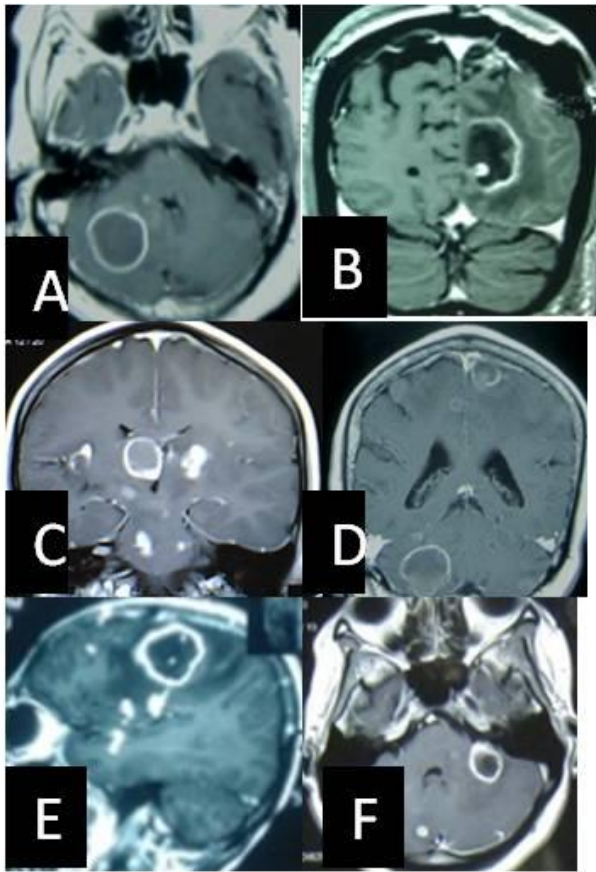


Figure II: Contrast MRI images in different sections showing tubercular abscess in different location. A-Right cerebellar hemispheric tubercular abscess. B-parieto-occipital recurrent tubercular abscess. C-Thalamic tubercular abscess with multiple tuberculomas. D-Multiple tubercular abscess involving both supra and infra tentorial compartment. E-Tubercular abscess in posterior frontal region with multiple small tuberculomas.F- small tubercular abscess in left cerebello-pontine angle and left cerebellar hemisphere.

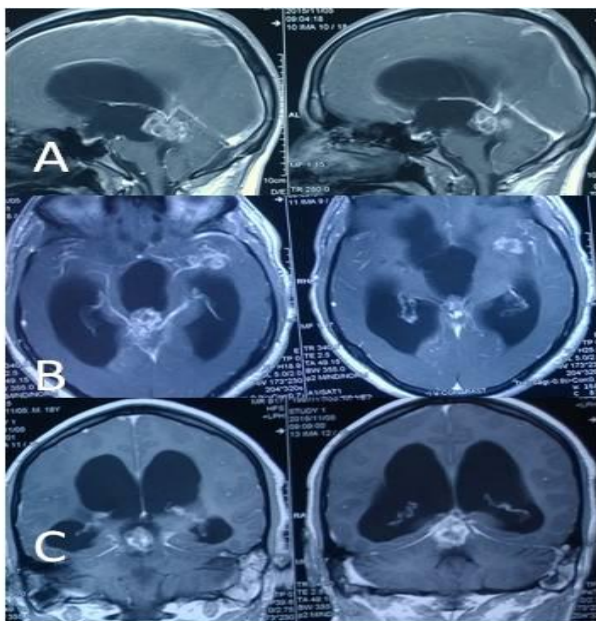


Figure III: Contrast MRI of head, A,B&C-sagittal,axial and coronal images respectively showing pineal and left temporal tuberculoma with triventriculomegaly

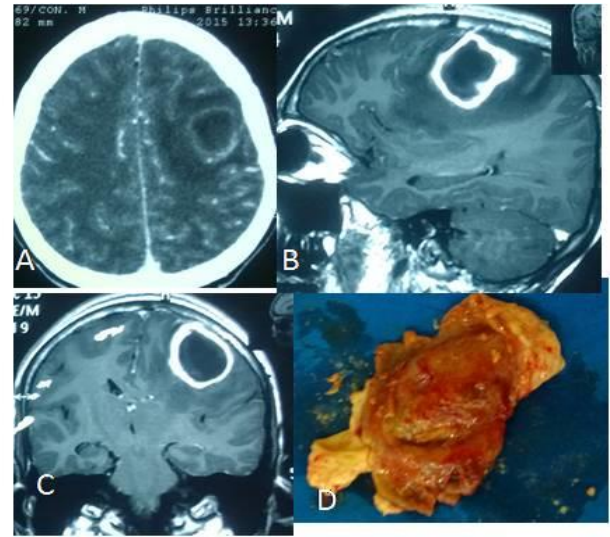


Figure IV: A-Contrast axial CT scan of brain showing left frontal tubercular abscess. B&C-Contrast MRI of brain in sagittal and coronal section respectively showing left posterior frontal tubercular abscess. D-per operative picture of abscess wall after excision of of abscess.

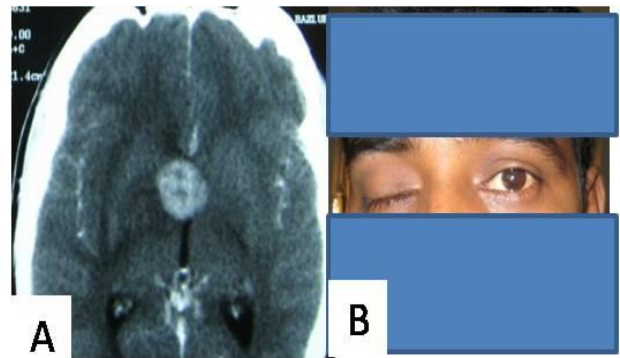


Figure V: Contrast CT of brain axial images A showing tuberculoma in basal cistern and hypothalamus. B-Ptosis on the right side of the patient due to involvement of oculomotor.

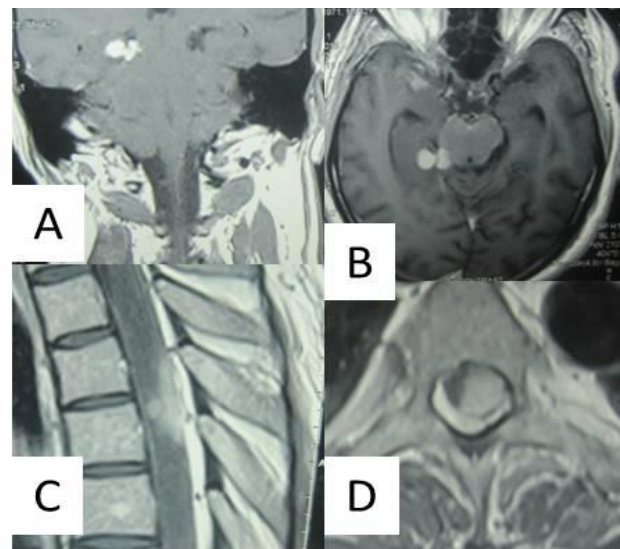


Figure VI: Contrast MRI of brain A-coronal image and B-axial image, showing tuberculoma in right temporal pole,

hippocampus and postero-lateral surfaces of pons. C&D-contrast MRI of dorsal spine showing simultaneous intradural

dorsal spinal tuberculoma causing spinal cord compression

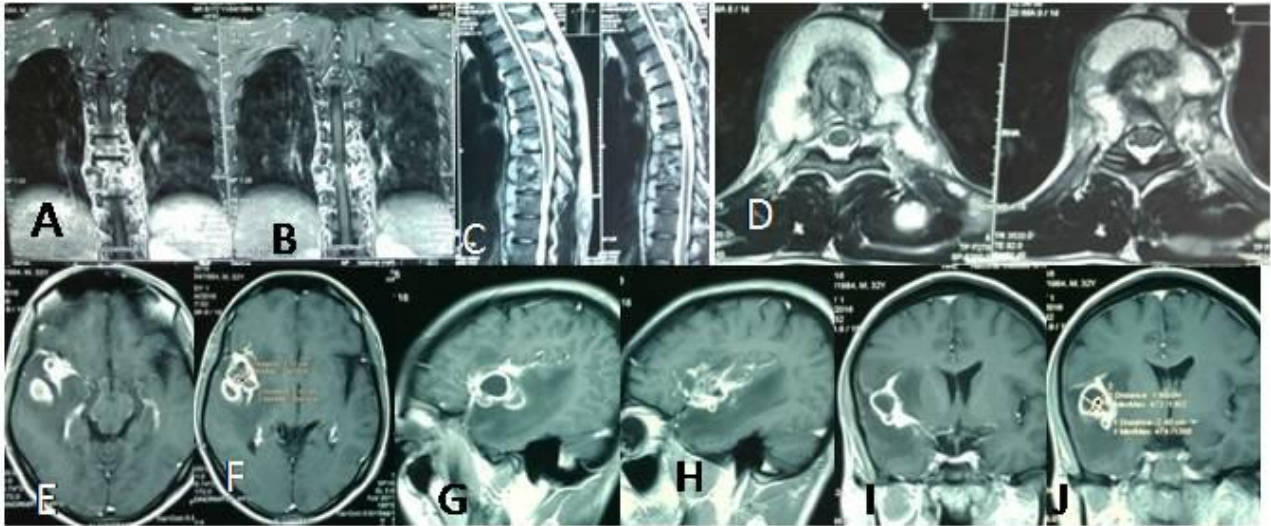


Figure VII(a): MRI images of simultaneous cerebral and spinal tuberculosis. A&B-Contrast MRI of dorsal spine and chest extensive dorsal spinal tuberculosis with abscess(paravertebral). C&D- T2W sagittal and axial images of dorsal spine respectively, showing multi-level extensive dorsal tuberculosis with abscess. Contrast MRI of brain, E&F-axial sections, G&H-sagittal images and I&J- coronal images, showing right sided perisylvian-insulo-putaminal tubercular lesions.

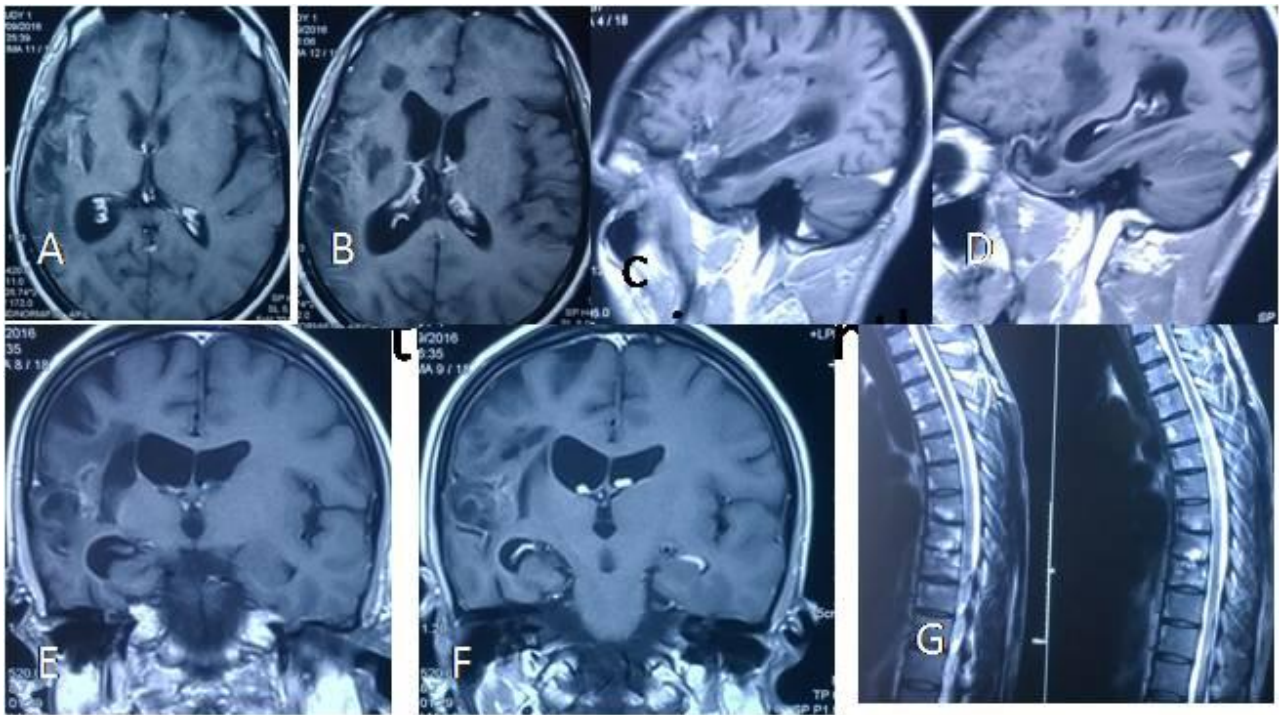


Figure VII(b): Post operative [06 month after operation(right sided craniotomy and removal of perisylvian tubercular lesion and trans thoracic drainage of tubercular abscess plus anti TB therapy)] MRI images of Figure66 patient. Contrast MRI of brain, A&B-axial, C&D-sagittal and E&F-coronal images showed almost healed tubercular lesion. G-MRI T2W images of dorsal spine six months after abscess drainage and anti TB therapy, showing nearly healed spinal tuberculosis

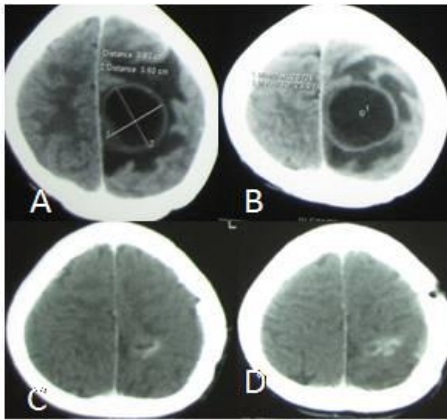


Figure VIII: Contrast CT scan of brain axial images. A&B- Pre operative CT showing left sided posterior frontal tubercular abscess with surrounding edema. C&D- Post operative(18 month after operation and anti TB therapy) Ct images showing healed lesion with calcification

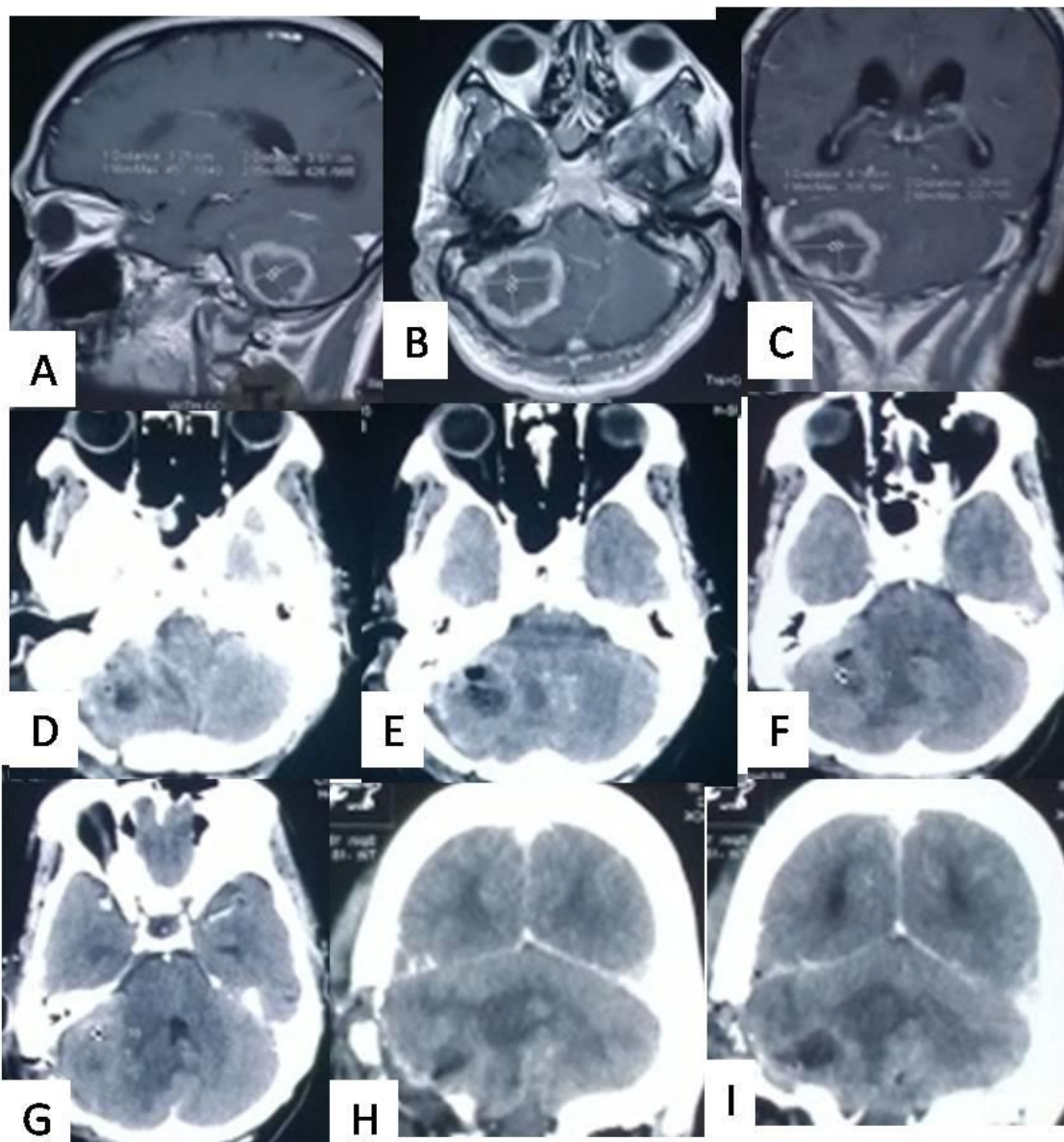


Figure IX: A,B&C-pre operative contrast MRI of brain sagittal, axial and coronal images respectively showing right sided lateral cerebellar large tuberculoma extending into cerebello-pontine angle. Early post operative contrast CT scan of head ; D,E,F&G- serial axial images and H&I-coronal images showing right lateral suboccipital craniotomy and removal of tuberculoma.

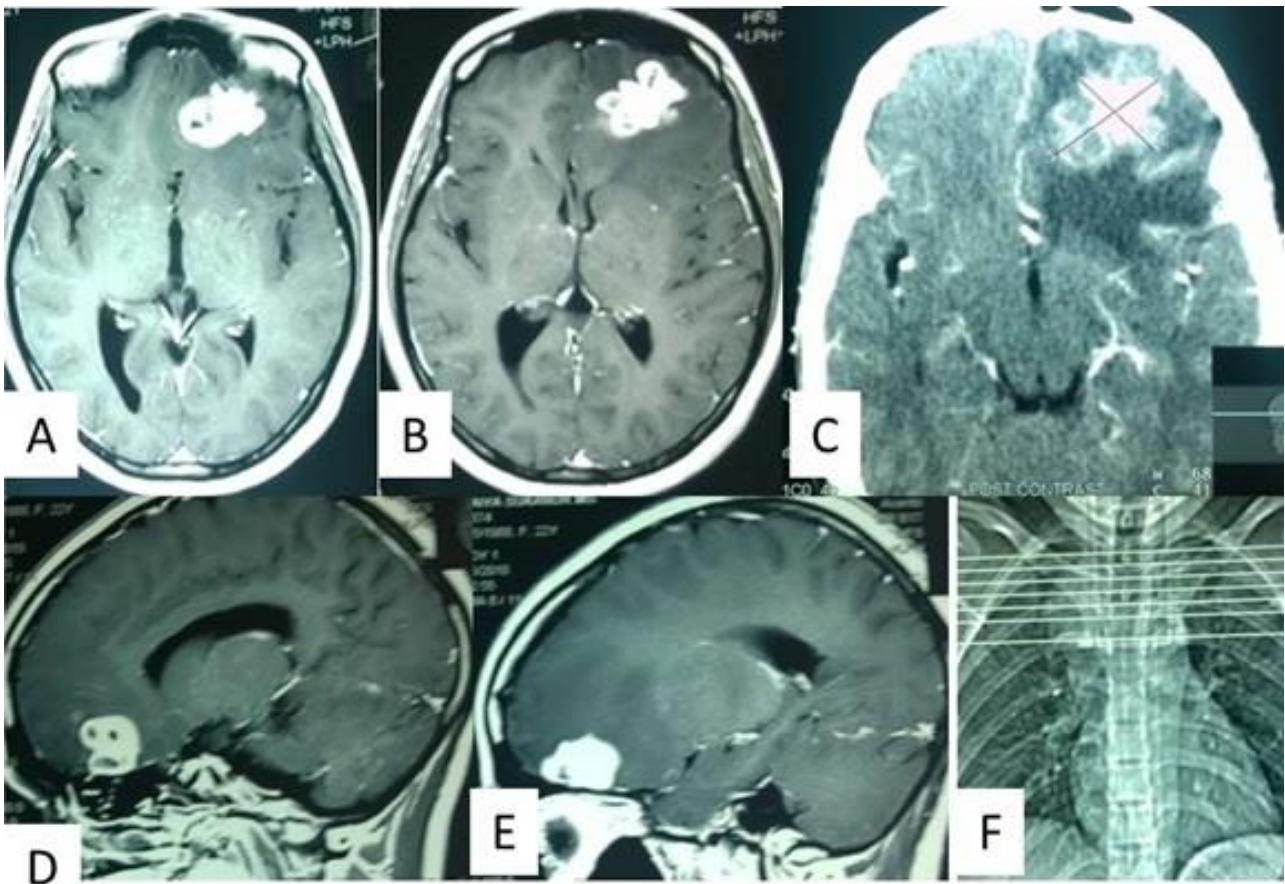


Figure X (a): Contrast MRI of brain, A&B axial images, D&E sagittal images and contrast CT scan of brain, C axial image showing large right frontal tuberculoma with mass affects and edema. F-CT scan of chest pilot film showing right sided superior mediastinal mass (tuberculoma) in the same patient

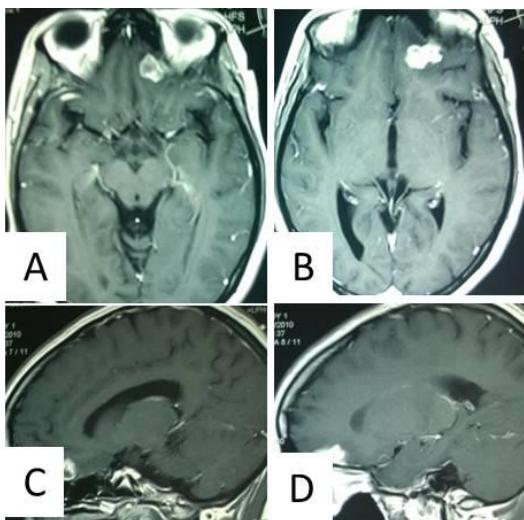


Figure X(b): Images are the same patient of Figure 22(1). CT scan of chest, A-pilot image,B-axial image and C coronal image showing superior mediastinal mass(mediastinal tubercular lymphadenitis). D- x-ray chest P/A view in the early post-operative period after right upper thoracotomy with right sided chest drain in situ and development of left sided pleural effusion. E & F- x ray chest, 3 and 6 months after thoracotomy respectively showing resolution of all lesions

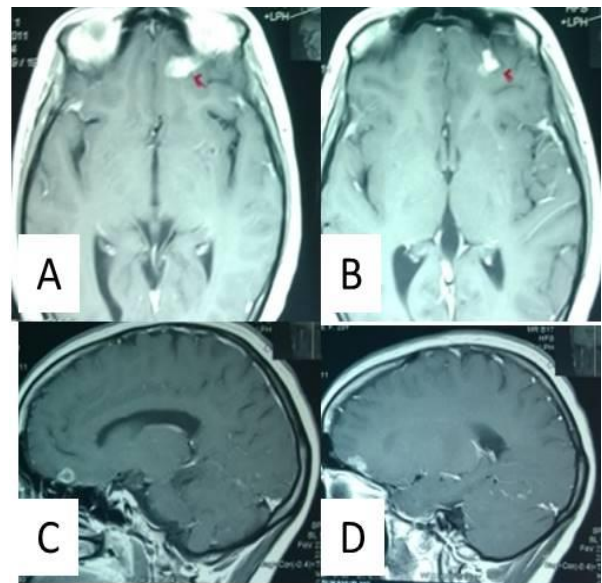


Figure X(c): Contrast MRI of brain A&B- axial images and C&D-sagittal images showing shrinkage of tubercular lesion in left frontal region 6 month after anti TB therapy

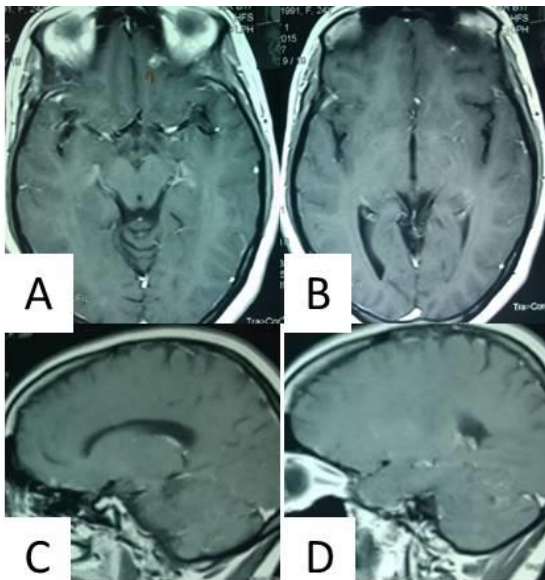


Figure X(d): Contrast MRI of brain A&B- axial images and C&D-sagittal images showing further shrinkage of tubercular lesion in left frontal region 12 month after anti TB therapy

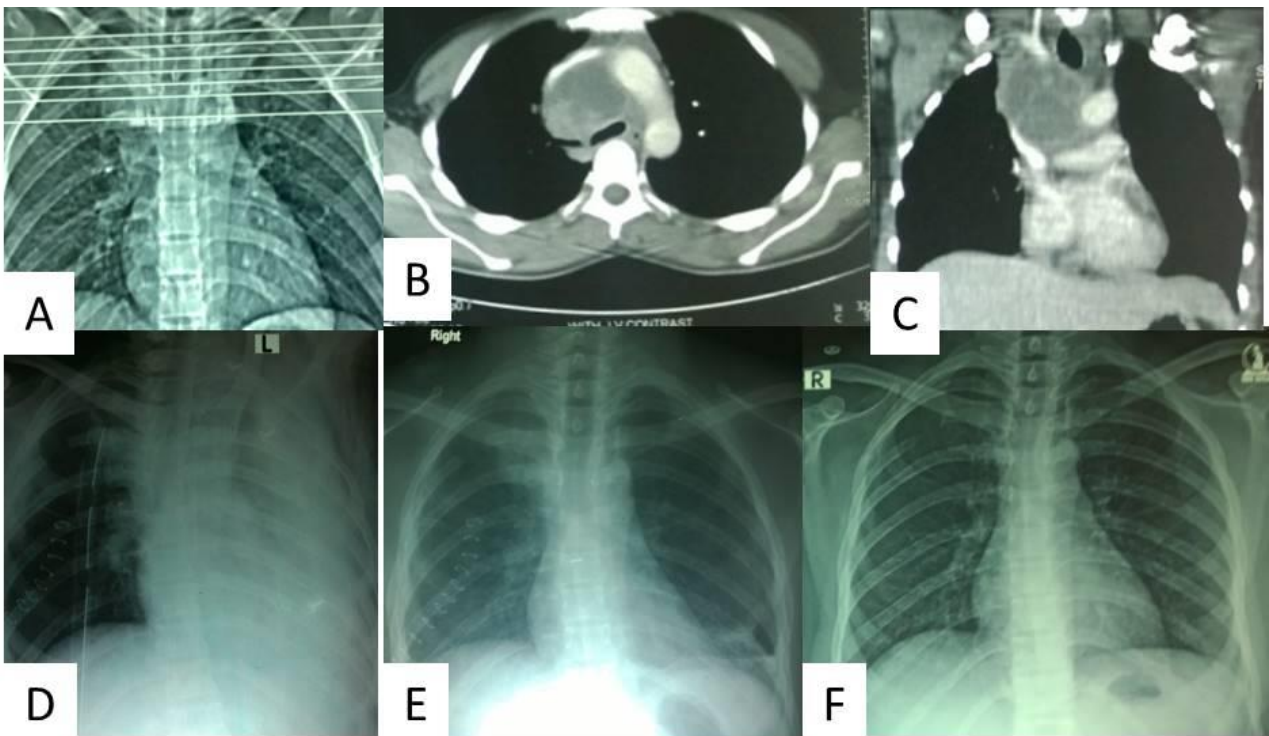


Figure X(e): Contrast MRI of brain A&B- axial images and C&D-sagittal images showing near resolution of tubercular lesion in left frontal region 18 month after anti TB therapy

General features of TB (Low grade fever, weight loss, anorexia, generalized weakness) were present in 11(14.4%) cases only absent in all cases. Raised ESR and abnormal blood pictures were very inconsistent in cerebral and cerebellar tuberculosis. Common ESR findings were in between 35 to 55 mm in first hour. Very high ESR (above 70 mm in first hour) was found in 09(11.8%) cases only. Hydrocephalus was found in 15(19.7%) cases (12 were triventriculomegaly) of cerebral and cerebellar tuberculosis. In 07(9.2%) patients, triventriculomegaly was due to posterior fossa

tuberculoma where surgical removal of lesion/s resulted resolution of hydrocephalus. In the rest 08 cases of hydrocephalus was treated with ETV plus attempt for endoscopic biopsy. But ETV with safe endoscopic biopsy was possible only in two cases. In six cases where endoscopic biopsy attempt failed, trans cranial excisional biopsy of another parenchymal lesion were done. Concurrent spinal intradural tuberculoma causing cord compression was found in 4(5.2%) cases Concurrent other systemic tuberculosis was found in 08(10.5%) cases (Figure X) (05 pulmonary tuberculosis, 01 intestinal

TB, 01 mediastinal lymphadenitis and the rest one was testicular tubercular epididymo-orchitis). One patient had history of full course anti-tubercular therapy for pulmonary tuberculosis 20 years back. No one was suffering from HIV infection. Socio-economically, 07(9.2%) patients were from higher middle class, 31(40.8%) were from middle class, 21(76.6%) were from lower middle class and 17(22.4%) were from lower class. Nutritional status was poor in 14(18.4%) cases and rests of the patients were in good nutritional status. Only 12 (15.8%) patients had definitive H/O of contact with tubercular patient. One patient who was obtunded preoperatively developed aspiration pneumonia post operatively and expired after four weeks. Another patient with renal transplant died during the course of treatment. All other patients responded well with standard anti-tubercular (TB) drugs regimen & dose and cured with complete neurological recovery or with some persistent neuro-deficit (in milder form but in three cases where patient had pretreatment hemiplegia did not improved even after apparent cure of the lesion and in five cases patient were completely blind at the end of the treatment.

In the earlier part of our experience, we went for surgery in brain parenchymal TB for having histological diagnosis after excision of tubercular lesion in all cases. But in later part, we adopt a more conservative approach. In suspected TB we went for PCR; in positive cases, we put the patient on antitubercular therapy for six weeks. By this time if patient showed clinical and radiological improvement, we came in conclusion of TB; if not we went for surgical excisional biopsy. In later part, we did surgery only in suspected TB with hydrocephalus, big lesion with mass effects or where probability of other lesion was very high than TB. In our patients, four drugs anti-tubercular chemotherapy was initiated composed of INH (isoniazide), rifampicine, ethambutol, pyrazinamide for initial three months and the patients were maintained on isoniazide and rifampicine over a period of next 15 months. In one patient who had H/O treatment for pulmonary tuberculosis 20 years back we used inj. streptomycin instead of ethambutol in initial three months. A large proportion of clinical symptoms were improved after 03 months following surgery and the initiation of therapy. We faced no drug related complication. There is a tendency to increase number of Multi Drug Resistant TB (MDRTB) but we faced only two cases of MDRTB. MDRTB cases were specially cared by 'MDRTB' team and chemotherapy in the 'special form (standard antiTB+inj streptomycin 1 gm daily for three months + Tab ciprofloxacin 1000mg daily for

whole duration of treatment)' was given for a period of 31 months. Radiologically, disappearance of the lesions and/or calcified healed lesions were observed after surgery (complete or partial excision) plus/ successful complete course chemotherapy in our cases except in one child where tuberculoma recurred 03 years after successful complete of anti TB therapy.

Discussion

Mycobacterium tuberculosis is an aerobic, acid/alcohol-fast bacillus (AFB) that infects primarily humans⁸. *Mycobacterium bovis* and atypical *mycobacterium spp* can also involve in cerebral TB. *M. tuberculosis* infection occurs through the inhalation of droplet nuclei, eventually leading to deposition in the lung alveoli. The activation of a type 1 T-helper cell-mediated immune response occurs, and, ultimately, a granuloma is formed. In the early part of pathological process there is bacillus bacteremia. This hematogenous seeding occurs most frequently in regions of the body that are highly oxygenated such as the brain and in the brain cerebral and cerebellar hemispheres and basal ganglia that are highly oxygenated parts of brain⁹. A complex interplay of host immune factors and *M. tuberculosis* virulence factors in the end determines whether or not the infection is contained and whether, or to what extent, the dissemination of the bacilli leads to clinical disease¹⁰. Microglia are the key cells the pathogenesis of neuro-TB⁸. For cerebral or other CNS TB; the disease begins with the development of small tuberculous foci (Rich foci) in the brain, spinal cord, or meninges. The location of these foci and the capacity to control them ultimately determine which form of CNS TB to occur¹¹. Brain parenchymal tubercular lesions can be in the form of tuberculoma including hard or soft granulomas, tubercular abscess including tuberculous cerebritis¹²⁻¹³. These forms of TB can occur with or without tubercular meningitis (TBM). Though solitary tuberculoma is seen occasionally but multiple grapes like tuberculoma are rare which develop as a result of coalescence of multiple small immature tuberculoma and resemble a cluster of neurocysticercus cyst¹⁴.

The age range of neuro-TB is between 25 and 45 years¹⁵ but it can occur at any age¹⁶. Tuberculomas and tubercular abscess are main brain parenchymal lesion. Tuberculoma is encountered in only 15% to 30% cases of CNS-TB¹⁷. Tuberculus lesions can involve any part of cerebral or cerebellar hemisphere. These are usually located at corticomedullary junction and periventricular

region, as expected for hematogenous dissemination. They are mostly supratentorial like hemispheric in adults and in children cerebral hemisphere is less commonly involved than cerebellum¹⁸⁻¹⁹. Turgut et al²⁰ reported distribution of brain tuberculomas was as follows cerebral hemisphere-41%, cerebellum-35%, brain stem-6%, intraspinal 6% and multiple-12%. Tubercular lesion in cerebellum can occur in cerebellar hemispheres, vermis, subependymal zone near fourth ventricle and cerebellar peduncle. They can occur in cerebello-pontine (CP) angle or part of cerebellum near to CP angle mimicking CP angle tumor³.

Clinical manifestations of brain parenchymal tuberculoma or abscess depend largely on their site of involvement. The sufferer often presents with headache, seizures, papilledema, or other signs of raised intracranial pressure. The symptoms usually develop in weeks to months with cerebral tuberculosis. The presentation of brain abscess is more acute (1 week to 3 months) than tuberculoma but slower in onset than pyogenic brain abscesses. Tubercular abscess is often associated with fever, headaches, and focal neurological deficits like visual disturbances, limb weakness, dysphasia, memory disturbances²¹. The presentation of cerebral tubercular lesions can be delayed months to years after the infection²². When there is associated with TBM, clinical pictures of TBM like classic meningitis symptoms of fever, headache, vomiting and stiff neck along with focal neurological deficits, behavioral changes, seizure and alterations in consciousness may co-exist²³. Abnormal movement disorders may occur in the form of chorea or hemiballismus, athetosis, tremors and myoclonic jerks²⁴. Low grade fever and night sweat may present specially in children. Differential diagnosis of brain parenchymal tubercular lesions are glial, meningeal and ependymal tumors, neuroectodermal tumor, metastases, lymphoma, cordoma, brain abscess, fungal infection, neurocystocercosis, hydatidosis, sarcoidosis²⁵⁻²⁶.

Definitive diagnosis is only done on detection of tuberculous bacilli in CSF either by smear examination or bacterial culture²⁷. Histopathological identification of tubercular granuloma is the hallmark of tuberculous and is considered as confirmatory for TB, but this can only be done after procurement of pathological tissue from brain lesion by any form of surgical intervention. CSF Cytological study, microbiological study, Molecular and Biochemical Analysis techniques include commercially available nucleic acid amplification (NAA) methods and other PCR (polymerase chain reaction)-based

methods, antibody detection, antigen detection, or chemical assays such as adenosine deaminase (ADA) and tuberculo-stearic acid measurements of CSF sometimes can help significantly but can not confirm TB⁸.

Neuroradiological findings can only be suggestive of neuro-TB but not confirmatory⁸. The MR features of individual tuberculoma will depend on whether the lesion is noncaseating, caseating with a solid center or caseating with a liquid center²⁸⁻²⁹. The non-caseating granuloma is usually hypointense on T1-weighted images (T1WI), hyperintense on T2-weighted images (T2WI) and shows homogenous nodular enhancement on post gadolinium images. The caseating granuloma(s) with solid center appears hypointense to isointense on T1WI may have a slight hyperintense rim and strikingly hypointense on T2W images. On contrast administration the lesion shows peripheral rim enhancement³⁰⁻³². On imaging, a TB abscess may be indistinguishable from a caseous tuberculoma with central liquefaction or a pyogenic abscess. However, a TB abscess is usually solitary and larger than tuberculoma. Perilesional edema and mass effect is more as compared to tuberculoma. Tuberculomas are normally defined as single or multiple, low- or high-density, round or lobulated masses with irregular walls and show homogenous or ring enhancement after administering contrast on CT scan^{17,33}. On CT and MRI, it is often multinucleated and shows thin, smooth peripheral wall enhancement on post contrast images³⁴.

Isolated lentiform nucleus TB or caudate nucleus TB are probably very rare and usually involved with other parts of CNS. Lesion in caudate nucleus usually causes chorea. Various types of movement disorders parkinsonism, extrapyramidal syndrome, tremor, chorea, dystonia, myoclonus, hemiballismus can occur in cerebral TB due to involvement of lentiform nucleus, caudate nucleus, thalamus, subthalamus, red nucleus³⁵⁻³⁶. Tremor is the most common movement disorder, chorea is more frequently found in young children and deep vascular lesions are more common among patients with movement disorders in brain tuberculosis³⁶.

Isolated hypothalamic tuberculoma or tuberculous abscess is very rare. Hypothalamus can be affected by the tubercular lesion in hypothalamus proper, third ventricle of suprasellar region. Clinical features include, general features of TB, headache, vomiting, visual disturbances, altered level of consciousness, behavioural changes, cachexia, memory disturbances, pituitary hypofunctions,

precocious puberty in children, diabetes incipidus, seizure and so on^{5,37}.

Thalamus is usually involved with other parts of CNS in TB. Isolated thalamic TB is very rare³⁸. Tuberculoma and tubercular abscess are the two form of thalamic TB. Clinical features are like that of thalamic tumor i.e features of rised ICP, motor deficit, seizure, behavioural changes, memory disturbances, visual disturbances³⁸. Tubercular lesion affecting only the subthalamus is very rare, usually affected with other part of hemisphere and can present with hemibalismus³⁹.

Brainstem tuberculomas are even more unusual, accounting for 2.5 to 8.0% of all intracranial tuberculomas⁴⁰⁻⁴¹. It carries a high mortality and a distressing level of neurological morbidity⁴². Brainstem tuberculoma or abscess present with features of IICP and focal signs for involvement of long tracts like hemiplegia or hemisensory deficit, involvement of cranial nerve nuclei leading to cranial nerve palsy like diplopia, gaze palsy, facial palsy, dysphagia, etc. Due to involvement or pressure over the reticular activating system patient may present with depressed level of consciousness. Tuberculoma of upper brainstem mostly midbrain causing obstruction to the CSF flow leading to hydrocephalus and present with headache, nausea and vomiting, visual impairment, papilledema and impaired consciousness. Midbrain lesion may also present with different syndromes: Weber's syndrome⁴³ presenting with 3rd cranial nerve palsy with contralateral hemiparesis. Benedict's syndrome presenting with 3rd cranial nerve palsy with contralateral hemiparesis except arm which has hyperkinesias, ataxia and coarse intention tremor when lesion involves the midbrain tegmentum with red nucleus⁴⁴. Sharma et al⁴⁵ presented one case of tuberculoma of pons with numbness on entire left half of face, scalp, tongue, part of auricle, features suggesting trigeminal neuropathy. Vinod et al⁴⁶ presented a case of brainstem tuberculoma with slurring of speech, difficulty in swallowing and weakness of all 4 limbs of sudden onset, features suggestive of stroke.

Clinically, presentation of brainstem tuberculoma can be variable. Different types of presentations have been reported in literature including one and a half syndrome, mimicking glaucoma or glioma. It has also been reported to present as unilateral paralysis of saccades, Millard Gubler syndrome, isolated bilateral ptosis, horizontal gaze palsy, myokemia and facial contracture or as Foville's syndrome⁴⁶.

Brainstem tuberculomas are usually focal lesions causing focal neurological symptoms related to the involvement of a cranial nerve nuclei and long tracts. TBM is commonly associated in a tuberculous rhombencephalitis. Hydrocephalus could be present when it causes obstruction to CSF flow (Figure VI). Hydrocephalus can present with headache, vomiting, visual blurring, gait disturbance, up gaze palsy, abducent nerve palsy⁴⁴.

TB (tuberculoma and tubercular abscess) in cerebellar peduncle is usually occurs from cerebellum or from brain stem by direct extension. Middle cerebellar peduncle is commonly affected. Rarely middle cerebellar peduncle can solely have affected by TB⁴⁷⁻⁴⁸. Clinical manifestation of cerebral peduncle TB are like that of signs and symptoms of cerebellar lesion such as slurred speech, incoordination, progressive difficulty in walking developed, dysarthria with scanning speech, gait ataxia, horizontal nystagmus, dysmetria and so on⁴⁸.

The approach to brain TB, endorsed by Infectious Diseases Society of America, Centers for Disease Control and Prevention, and American Thoracic Society guidelines⁴⁹ includes an initial 2-month induction therapy regimen including isoniazid, rifampin, pyrazinamide, and ethambutol, followed by 7 to 10 additional months of isoniazid and rifampin as maintenance therapy for an isolate that is sensitive to these agents. Isoniazid, rifampin, and the second-line agents aminoglycosides, capreomycin, and fluoroquinolones are available in parenteral form if an altered mental status precludes oral intake. The recommended use of this regimen and the duration of therapy are extrapolated from the standard regimen for pulmonary TB, since no randomized control trial has established an optimal treatment course for CNS TB. Recommended duration of anti tuberculous therapy is at least 9 to 18 months, depending upon the patient's clinical and radiological response, but may have to be continued for longer or changed to second line medications^{25,50-51}. The treatment of multi drug resistance (MDR) and extensive drug resistance (XDR) TB is difficult and it needs long drugs therapy in special combination with first and second line drugs. Even in the expert hands outcome is not good^{49,52-55}. The use of corticosteroids in the treatment of cerebral TB is a controversial issue. It reduces inflammation within the subarachnoid space⁵⁶. Anti convulsant should be routinely used in cerebral TB. Commonly used drus are phenytoin, carbamazepine, oxcarbamazepin and sodium valproate. Phenytoin and isoniazide can produce toxicity due to interaction⁵⁷.

Initial literature is filled with reports of successful treatments with surgical excision of tuberculomas, but with the introduction of better medications and with reports of equal or even better results with antituberculous therapy alone, so the paradigm shifted towards conservative management⁵⁸. Patients in endemic areas were managed on the basis of clinical suspicion alone without the need for histological diagnosis. Neurosurgical intervention was restricted to stereotactic or CT guided biopsies of suspect lesions or lesions not responding to medications⁵⁹. However recent reports suggest that only drugs therapy may be insufficient for complete cure of these lesions, with 20.0 to 46.0% of the lesions failing to resolve on prolonged (18 months) of anti-tuberculous therapy alone^{27,51}. It has been recommended that medical management should be initiated for most tuberculomas which can be diagnosed with reasonable confidence based only on their clinical and radiological features⁶⁰⁻⁶¹. Whenever the diagnosis is suspect, the choice is between an empirical courses of antituberculous therapy followed by repeat imaging or a biopsy of the most superficial lesion in the least eloquent area is recommended⁶²⁻⁶³. For biopsy, excision of the entire tuberculoma is always preferable if it can be done safely⁶³. If lesions near eloquent areas need to be biopsied, stereotactic, neuronavigation or ultrasound guided aspirations are useful. For giant tuberculomas, or tuberculomas not responding to therapy, or tuberculomas causing significant mass effect, surgical excision should be considered. When more than one lesion is present, giant tuberculomas are excised²⁷. An aggressive attitude towards these giant tuberculomas is due to the fact that these hardly ever resolve with medical therapy alone, require long duration of therapy, have a high risk of reactivation and may show the paradoxical effect. Debulking of these lesions not only reduces bulk but also improves antibiotic penetration and lowers steroid requirements²⁷. Partial excision of tuberculomas carries a higher risk of post-operative hemorrhage. The postoperative course is usually unremarkable. As a policy, biopsy is recommended for all suspected intracranial tuberculomas prior to initiation of chemotherapy⁶⁴. Sometimes despite adequate antimicrobial coverage, the tuberculoma may increase in size, a phenomena referred to as the paradoxical response. This generally occurs over a period of 1 to 3 months after the commencement of chemotherapy⁶⁵. Under such circumstances, serious thought should be given to reconfirmation of diagnosis and/or excision of tuberculomas. Sequela of disease includes re-activation TB, drug resistance, hydrocephalus, seizures and paradoxical response to anti tuberculous therapy⁵⁸. Serial brain

imaging is essential to determine the length of therapy. Surgery is indicated for both diagnosis and therapy of tuberculomas⁵⁷ or tubercular abscess. A tuberculoma/tubercular abscess that severely elevates intra cranial pressure (ICP) and threatens life or vision merits emergent surgical excision. In addition, surgical intervention comes into consideration in 1) patients who do not respond clinically or radiologically to anti TB therapy, 2) patients whose diagnosis in doubt, such as those with atypical CT or MRI images [66] and 3) patients with obstructive hydrocephalus⁵⁷. Appropriate surgical treatment options for tubercular abscesses include simple puncture, continuous drainage, fractional drainage, repeated aspiration through a burr hole, stereotactic aspiration, and total excision of the abscess²¹ along with antiTB therapy. From our experiences, when suspected tubercular abscess, excision of the abscess gives best outcome. Hydrocephalus is an extremely common complication of CNS TB and can be treated with excision of mass lesion (i.e. tuberculomas or abscess), diuretics, osmotic agents, serial lumbar punctures, external ventricular drainage, ventriculoperitoneal shunts (VPS) and ETV⁶⁷. More recently, there are encouraging data on the safety and efficacy of neuroendoscopy in relieving hydrocephalus in both adults⁶⁸ and infants⁵⁴ which may negate the need for VPS. In the earlier part of our experiences, we frequently did surgery for cerebral (and cerebellar) tuberculomas, as experiences increased rate of surgery went down as we learned more conservative way to treat the parenchymal TB lesions by empirical/trial antiTB therapy. But when surgery is needed we did radical excision biopsy even in eloquent areas. In this era of microsurgery and modern neurosurgical skill post excision neuro-deterioration is unlikely. We did the complete excision of the targeted lesion in almost all cases where surgery was needed or done without any neuro-deterioration.

Tuberculoma in brain parenchyma is relatively less epileptogenic but patient with CNS TB can present with seizure. Epilepsy the only presenting feature in CNS tuberculoma is rare⁶⁹⁻⁷⁰. Tuberculoma causing seizure can usually manage by ant epileptic drugs. Tuberculoma with only intractable epilepsy is further rare. Tuberculoma in medial temporal lobe can rarely cause intractable seizure which can respond surgery followed by antiTB therapy⁶⁹.

Advanced stage (coma, millitary tuberculosis) of the disease at presentation, age, and the presence of any infarction other than a purely hemispheric infarction, HIV coinfection, and the combination of isoniazid and rifampin resistance are poor outcome

predictors^{55,71-72}. Brain tuberculomas usually carry a favorable prognosis⁷¹. Majority of patients make complete recovery although some may have neurological deficits⁷. Initial reports of mortality ranged from 10.0 to 27.0%. But the results have dramatically improved in recent years⁵⁷. Early diagnosis and appropriate treatment usually prevent complications such as hydrocephalus, infarct, paradoxical affect. But the development of sequelae and complications may be delayed, so close monitoring following the initiation of antiTB therapy is essential. Follow-up CT scans/MRI at 1 week and 1 month after the initial CT scan have been shown to be particularly important in picking up important diagnostic findings and adverse sequelae in children with CNS TB⁷³.

For prevention, BCG vaccination covers 85.0% of newborn infants, and it has been estimated that nearly 100 million children are vaccinated with BCG vaccine every year. Several studies have shown that BCG protects against TBM and that its efficacy is around 75.0 to 85.0%⁸. The efficacy of BCG appears to persist through 10 years after infant vaccination⁷⁴.

Conclusion

Brain TB is a very serious form of TB that can occur in different forms and can cause mortality and morbidity in endemic developing countries and also in developed countries due to emergences of immunocompromized conditions. When dealing with a intra cranial space occupying lesion, possibility of tubercular lesion should not be forgotten. Even in this ultra modern era of medical sciences, sometime diagnosis is very challenging. Trial empirical antiTB therapy has very important management role in endemic areas of TB. Though surgery has definitive indications and role, paradigm shifted toward the conservative drugs treatment, in brain tuberculosis management. Management of XDR and MDR TB of brain are extremely difficult, need special attention and special team.

References

- Sathyanarayana S, Baskaya MK, Fowler M, Roberts R, Nanda A. Solitary tuberculoma of the cerebellopontine angle: a rare presentation. *J Clin Neurosci* 2003;10:120-122
- Arvind C, Korath MP, Raveendranadhan K, Jagadeesan K. A retrospective study of 1247 cases of intracranial tuberculomata diagnosed by computerized tomography. *J Assoc Physicians India* 1993;41:559-561
- Bishburg E, Sunderam G, Beichman LB, Kapila R. Central nervous system TB with the aquired immunodeficiency syndrome and its related complex. *Ann Med Interne* 1986;105:201-213
- Prabhakar S, Thussu A (1997) Central nervous system TB. *Neurol India* 45:132-40
- Dutta P, Bhansali A, Singh P. Pituitary Suprasellar tubercular abscess presenting as panhypopituitarism: A common lesion in an uncommon site, a brief review of literature. *Pituitary* 2006;9:73-77
- Zuger A. Tuberculosis. In: Scheld WM, Whitley RJ, Mara CM, editors. *Infections of central nervous system*. 3. New York: Lippincott-Raven Publishers, 2004;441-460
- Shamim MS, Enam SA, Ali RP, Ali SF, Wasay M. Overview of surgical management of Infectious non-suppurative brain lesions (part 1). *Pak J Neurol Sci* 2009;4:77-82
- Rock RB, Olin M, Baker CA, Molitor TW and Piterson PK. Central Nervous System TB: Pathogenesis and Clinical Aspects. *Clin Microbiol Rev* 2008;21:243-261
- Chowdhury FH, Haque MR, Alam MSM. Third Ventricular and Interpeduncular Fossa Tubercular Abscess With Triventriculomegaly - Ventriculoscopic Surgical Management. *J Medecine* 2013;14 :72-73
- Ulrichs T, Kaufmann SHE. Cell-mediated immune response. In: Rom WN, Garay SM, eds. *Tuberculosis*. 2nd ed. Lippincott Williams & Wilkins, Philadelphia, 2004;251-262
- Rich AR, McCordock HA. The pathogenesis of tuberculous meningitis. *Bull Johns Hopkins Hosp* 1933;52:5-37
- Khoo JLS, Lau KY, Cheung CM, Tsoi TH. Central Nervous System TB. *J HK Coll Radiol* 2003;6:217-228
- Shah, GV. Central nervous system TB. *Neuroimaging Clin North Am* 2000;10:355-374
- Ahmad FU, Gupta A, Mehta VS. In: Arora VK, editor. *Practical Approach to TB management*. 1. Newdelhi: Jaypee brothers, 2006;138-148
- Mazodier K, Bernit E, Faure V, Roverly C, Gayet S, Seux V, et al. Central nervous TB in patients non-HIV: seven case reports. *Rev Med Interne* 2003;24:78-85
- de Castro CC, de Barros NG, Campos ZM, Cerre GG. CT scans of cranial TB. *Radiol Clin North Am* 1995;33:753-769
- Kaojarern S, Supmonchai K, Phuapradit P, Mokkhavea C, Krittiyanunt S. Effect of steroids on cerebrospinal fluid penetration of antituberculous drugs in tuberculous meningitis. *Clin Pharmacol Ther* 1991;49:6-12
- Bhargava, Tandon PN. Intracranial tuberculomas: A CT study. *Br J Radiol* 1980;53:935-945
- Welchman JM. CT of intracranial tuberculomata. *Clin Radiol* 1979;30:567-579
- Turgut M, Özcan OE, Özgen T, Sağlam S, Bertan V, Erbeni A. Tuberculomas of the craniospinal axis. *Turk Neurosurg* 1989;1:34-38
- Kumar R, Pandey CK, Bose N, Sahay S. Tuberculous brain abscess: clinical presentation, pathophysiology and treatment (in children). *Childs Nerv Syst* 2002;18:118-123
- Brooks JB, Daneshvar MI, Haberberger RL, Mikhail IA. Rapid diagnosis of tuberculous meningitis by frequency-pulsed electron-capture gas-liquid chromatography detection of carboxylic acids in cerebrospinal fluid. *J Clin Microbiol* 1990;28:989-997
- Sutlas PN, Unal A, Forta H, Senol S, Kirbas D. Tuberculous meningitis in adults: review of 61 cases. *Infection* 2003;31:387-391
- Chatterjee S. Brain tuberculomas, tubercular meningitis, and post-tubercular hydrocephalus in children. *J Pediatr Neurosci* 2011;6 (Suppl S1):96-100
- Bano S, Chaudhary V, Yadav S. Central Nervous System TB, Neuroimaging - Clinical Applications. In: Bright P, editor. *InTech*, 2012;467-498
- Yanardag H, Uygun S, Yumuk V, Caner M, Canbaz B. Cerebral TB mimicking intracranial tumour. *Singapore Med J* 2005;46:731

27. Poonnoose SI, Rajshekhar V. Rate of resolution of histologically verified intracranial tuberculomas. *Neurosurgery* 2003;53:873-878
28. Gupta RK, Jena A, Sharma DK, Guha DK, Khushru S, Gupta AK. MR imaging of intracranial tuberculomas. *J Comput Assist Tomogr* 1988;12:280-285
29. Jinkins JR, Gupta R, Chang KH, Rodriguez-Carbajal J. MR imaging of central nervous system TB. *Radiol Clin North Am* 1995;33:771-786
30. Bernaerts A, Vanhoenacker FM, Parizel PM, Van Goethem JW, Van Altena R, Laridon A, De Roeck J, Coeman V, De Schepper AM. TB of the central nervous system: overview of neuroradiological findings. *Eur. Radiol* 2003;13:1876-1890
31. Gupta RK, Prakash M, Mishra AM, Husain M, Prasad KN, Husain N. Role of diffusion weighted imaging in differentiation of intracranial tuberculoma and tuberculous abscess from cysticercus granulomas - a report of more than 100 lesions. *Eur J Radiol* 2005;55:384-392
32. Jayasundar R, Raghunathan P, Banerji AK. Proton MRS Similarity between central nervous system non-Hodgkin lymphoma and intracranial tuberculoma. *Magn Reson Imaging* 1995;13:489-493
33. Katti MK. Pathogenesis, diagnosis, treatment, and outcome aspects of cerebral TB. *Med Sci Monit* 2004;10: RA215-RA229
34. Whitener DR. Tuberculous brain abscess. Report of a case and review of the literature. *Arch Neurol* 1978;35:148-155
35. Enani MA, Al-Nakhli DJ, Bakhsh E. Isolated brain stem tuberculoma presenting with "one and a half syndrome" Saudi Med J 2006;27(9):1407-1411
36. American Thoracic Society, Center for Disease Control and Prevention, and Infectious Diseases Society of America. Treatment of tuberculosis. *MMWR Recomm. Rep.* 2003;52:1-77
37. George AD. Brainstem tuberculosis *BMJ Case Reports* 2013;
38. Christie LJ, Loeffler AM, Honarmand S, Flood JM, Baxter R, Jacobson S, et al. Diagnostic Challenges of Central Nervous System Tuberculosis *Emerging Infectious Diseases* 2008;14(9):1473
39. Thwaites GE, Duc Bang N, Huy Dung N, et al. The influence of HIV infection on clinical presentation, response to treatment, and outcome in adults with tuberculous meningitis. *J Infect Dis* 2005;192:2134-41
40. Kumar R, Jain R, Kaur A, Chhabra DK. Brain stem tuberculosis in children. *Br J Neurosurg.* 2000;14(4):356-61
41. Gropper MR, Schulder M, Duran HL, Wolansky L. Cerebral tuberculosis with expansion into brainstem tuberculoma. Report of two cases. *J Neurosurg.* 1994;81(6):927-31
42. Cherian A, Thomas SV. Central nervous system tuberculosis. *Afr Health Sci* 2011;11(1): 116-127
43. Warenbourg H, Niquet G, Lekieffre J, Thoreux M, Coupin J. Onset of meningeal tuberculosis with Weber's syndrome *Lille med.* 1961: 3
44. Greenburg MS. *Handbook of Neurosurgery*, Thieme medical publishers, New York, 5th edn. 2001;p 56-94
45. Sharma C, Kumawat B, Tripathi G, Dixit S (2008). Isolated Sensory Trigeminal Neuropathy- A Rare Clinical Presentation of Brain Stem Tuberculoma. Case Report. *The Internet Journal of Neurology.* 2008;11(1)
46. Gautam VKS, Singh R, Khurana S. Brainstem Tuberculoma Presenting As Stroke *IOSR Journal of Dental and Medical Sciences (IOSR-JDMS).* 2013;4(6):18-19
47. Verdon R, Chevret S, Laissy JP, Wolff M. Tuberculous meningitis in adults: review of 48 cases. *Clin. Infect. Dis* 1996;22:982-988
48. Lau KK, Yeun H. Paradoxical development of brain stem tuberculoma during the treatment for tuberculous meningitis. *HKMJ* 1996;2: 211-212
49. American Thoracic Society, Center for Disease Control and Prevention, and Infectious Diseases Society of America. Treatment of TB. *MMWR Recomm Rep* 2003;52:1-77
50. Gropper MR, Schulder M, Sharan AD, Cho ES. Central nervous system TB: medical management and surgical indications. *Surg Neurol* 1995;44:378-384
51. Rajeswari R, Sivasubramanian S, Balambal R, Parthasarathy R, Ranjani R, Santha T, Somasundaram PR, Ganapathy S, Sudarsana K, Sayeed ZA, Kalyanaraman S, Prabhakar R A controlled clinical trial of short-course chemotherapy for tuberculoma of the brain. *Tuber Lung Dis* 1995;76:311-317
52. Berning SE, Cherry TA, Iseman MD. Novel treatment of meningitis caused by multidrug-resistant Mycobacterium TB with intrathecal levofloxacin and amikacin: case report. *Clin Infect Dis* 2001;32:643-646
53. Caws M, Thwaites GE, Duy PM, Tho DQ, Lan NT, Hoa DV, et al. Molecular analysis of Mycobacterium TB causing multidrug-resistant TB meningitis. *Int J Tuberc Lung Dis* 2007;11:202-208
54. Padayatchi N, Bamber S, Dawood H, Bobat R. Multidrug-resistant tuberculous meningitis in children in Durban, South Africa. *Pediatr Infect Dis J* 2006;25:147-150
55. Thwaites GE, Lan NT, Dung NH, Quy HT, Oanh DT, Tho NT, et al. Effect of antiTB drug resistance on response to treatment and outcome in adults with tuberculous meningitis. *J Infect Dis* 2005;192:79-88
56. Kamoto K, Tokiguchi S, Furusawa T, Ishikawa K, Quardery AF, Shinbo S, Sasai K. MR features of diseases involving bilateral middle cerebellar peduncles. *AJNR Am J Neuroradiol* 2003;24:1946-1954
57. Rosenbulum ML. Chronic granulomatous lesions: TB, leprosy, sarcoidosis. In: Wilkms RH, Rengachary SS, editor. *Neurosurgery.* 3. Mc Graw-Hill Book Compo, pp. 1980-1983, 1985
58. Awada A, Daif AK, Pirani M, Khan MY, Memish Z, Al Rajeh S. Evolution of brain tuberculomas under standard antituberculous treatment. *J Neurol Sci* 1998;56(1):47-52
59. Lee WY, Pang KY, Wong CK. Brain tuberculoma in Hong Kong. *Hong Kong Med J* 2002;8:52-56
60. Tandon PN, Bhargava S. Effect of medical treatment on intracranial tuberculoma--a CT study. *Tubercle* 1985;66:85-97
61. Tandon PN. Brain biopsy in tuberculoma: the risks and benefits. *Neurosurgery* 1992;30:301
62. Bouchama A, al-Kawi MZ, Kanaan I, Coates R, Jallu A, Rahm B, Siqueira EB. Brain biopsy in tuberculoma: the risks and benefits. *Neurosurgery* 1991;28:405-409
63. Selvapandian S, Rajshekhar V, Chandy MJ, Idikula J. Predictive value of computed tomography-based diagnosis of intracranial tuberculomas. *Neurosurgery* 1994;35:845-850
64. Muthukumar N, Sureshkumar V, Ramesh VG. En plaque intradural extramedullary spinal tuberculoma and concurrent intracranial tuberculomas: paradoxical response to antituberculous therapy. *J Neurosurg Spine* 2007;6:169-173
65. Bas NS, Guzey FK, Emel E, Alatas I, Sel B. Paradoxical intracranial tuberculoma requiring surgical treatment. *Pediatr Neurosurg* 2005;41:201-205
66. Vidal JE, Penalva de Oliveira AC, Filho FB, Nogueira SR, Dauar RF, Leite AG, Lins DL, Coelho JF. Tuberculous brain abscess in AIDS patients: report of three cases and literature review. *Int J Infect Dis* 2005;9:201-207
67. Schoeman JF, Laubscher JA, Donald PR. Serial lumbar CSF pressure measurements and cranial computed tomographic findings in childhood tuberculous meningitis. *Childs Nerv Syst* 2006;16:203-208
68. Husain M, Jha DK, Rastogi M, Husain N, Gupta RK. Role of neuroendoscopy in the management of patients with tuberculous meningitis hydrocephalus. *Neurosurg Rev* 2005;28:278-283

69. Chowdhury FH, Haque MR, Haque AFMM. Intractable temporal lobe epilepsy (TLE) from tuberculoma; Microneurosurgical management of by amygdalohippocampectomy with lesionectomy plus standard anterior temporal lobectomy. A case report and short review of literature. *J Surgical Sciences* 2012;16:106-109
70. Greenberg MS. Seizures. In Greenberg MS, MD, editor. *Hand book of Neurosurgery*. Newyork: Thieme, 2001;254-284
71. Wasay M, Moolani MK, Zaheer J, Kheleani BA, Smego RA, Sarwari RA. Prognostic indicators in patients with intracranial tuberculoma: a review of 102 cases. *J Pak Med Assoc* 2004;54:83-87
72. Andronikou S, Wieselthaler N, Smith B, Douis H, Fieggen AG, Vantoorn R, et al. Value of early follow-up CT in paediatric tuberculous meningitis. *Pediatr Radiol* 2005;35:1092-1099
73. Andronikou S, Wilmshurst J, Hatherill M, Vantoorn R. Distribution of brain infarction in children with tuberculous meningitis and correlation with outcome score at 6 months. *Pediatr Radiol* 2006;36:1289-1294
74. Colditz GA, Berkey CS, Mosteller F, Brewer TF, Wilson ME, Burdick E, Fineberg HV. The efficacy of bacillus Calmette-Guerin vaccination of newborns and infants in the prevention of TB: meta-analyses of the published literature. *Pediatrics* 1995;96:29-35