

CLINICAL IMAGE

MEDICAL QUIZ: IMAGE - 2

AMINUR RAHMAN

Received: 08.11.2021

Accepted: 09.11.2021

DOI: <https://doi.org/10.3329/bjm.v33i1.56804>

Citation: Rahman A. *Clinical Image. Bangladesh J Medicine* 2022; 33: 123

70-year-old man with chronic lymphocytic leukemia (CLL), now presenting with several weeks of worsening vision loss, left facial droop, dysarthria, and memory loss. A MRI scan FLAIR, T1WI and T1WI+C was done. Answer the following questions

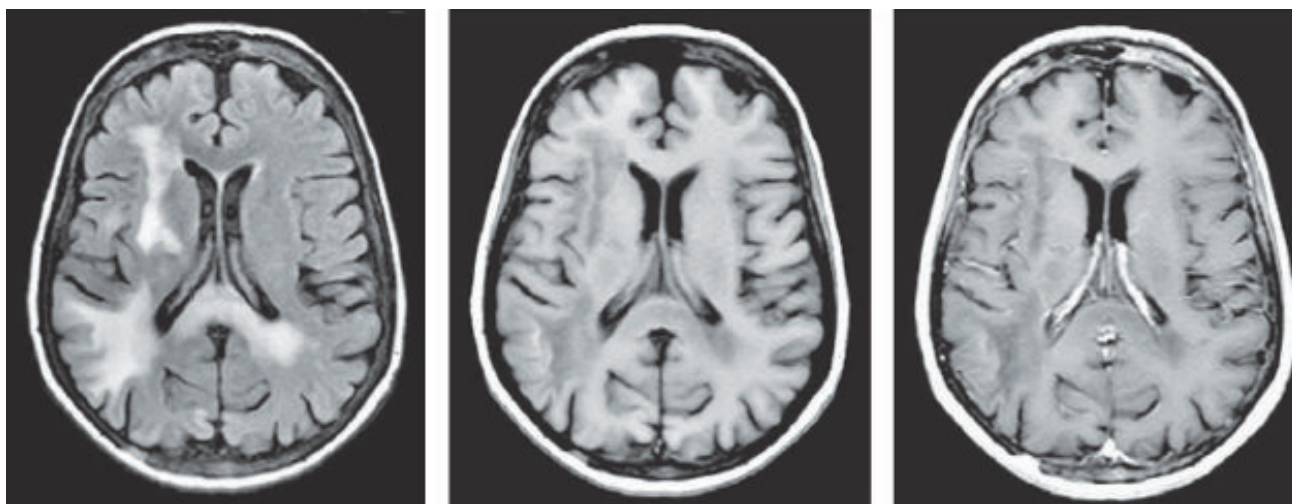


Figure: A MRI scan FLAIR, T1WI and T1WI+C

Question 1: Describe the abnormalities in this MRI scan of brain

Question 2: What is radiological diagnosis?

Question 3: What are the two important differential diagnosis:

Question 4: What is the treatment?

Address of Correspondence: Dr. Aminur Rahman, Assistant Professor, Department of Neurology, Sir Salimullah Medical College, Mitford. Dhaka, Bangladesh. Email: draminur@yahoo.com; Mob: +8801711180902

Copyright: © 2021 Associations of Physicians of Bangladesh