

CLINICAL IMAGE

MEDICAL QUIZ - 2

AMINUR RAHMAN

Received: 05-08-2022

Accepted: 10-08-2022

DOI: <https://doi.org/10.3329/bjm.v33i3.61383>

Citation: Rahman A. Medical quiz: Image-2. Bangladesh J Medicine 2022; 33: 319.

24yr old female university student with no significant personal past or family history presented with backache for past 3 months which was aggravated during exertion relieved with analgesics. Since 1month she had shooting type of sensation across the back of thigh while bending forwards. These complaints were continuing till two week back, when she had felt

weakness of left lower limb including proximal and distal muscles associated with urinary incontinence and paraesthesia. But she was able to appreciate all the normal sensations. She also felt band like sensation over the level of umbilicus. A MRI has done (Figure 2 - A, B, C & D). Answers the following question.

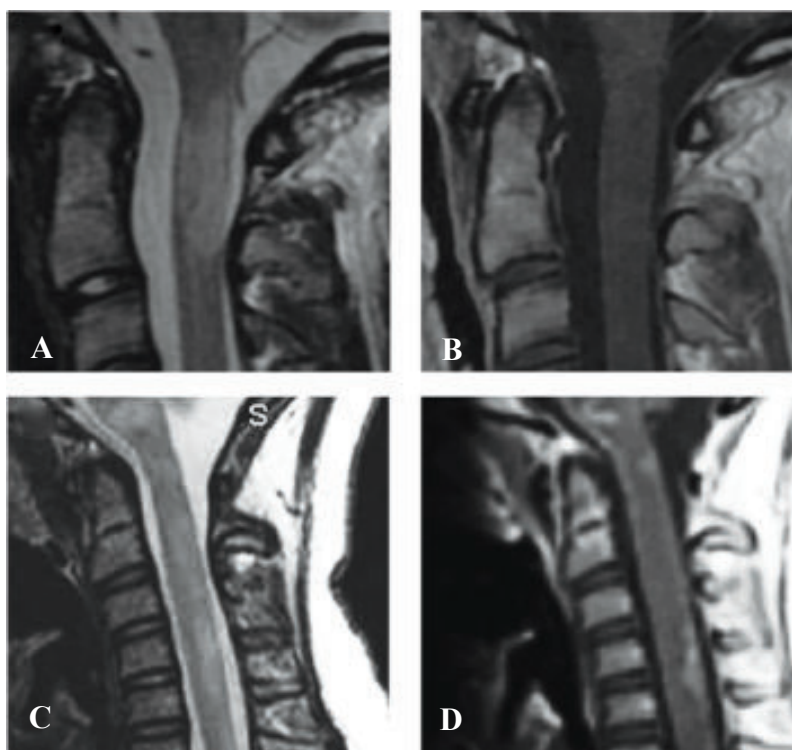


Figure-2 (A, B, C, D)

Answer the following questions.

- What are the findings of the MRI
- What is the diagnosis?
- What is the treatment?

Address of Correspondence: Dr. Aminur Rahman, Assistant Professor, Department of Neurology, Sir Salimullah Medical College, Mitford, Dhaka, Bangladesh, email: draminur@yahoo.com; Cell no: +08801711189092; [Orcid.org/0000-0001-9261-7734](https://orcid.org/0000-0001-9261-7734)

Copyright: @ 2021 Associations of Physicians of Bangladesh