

CASE REPORT

A FIRST CASE REPORT OF *TALAROMYCES MARNEFFEI* INFECTION PRESENTING AS A NON-RESOLVING PNEUMONIA IN A NON-HIV DIABETIC PATIENT FROM BANGLADESH

HASNA FAHMIMA HAQUE¹, AKM SHAHEEN AHMED², TARIFUL HOQUE³, REPON CHANDRA SAHA⁴, FARHANA AFROZ⁵

Abstract:

Talaromyces marneffi is a systemic fungal infection caused by dimorphic fungus *Talaromyces marneffi*. It is endemic in Southeast Asia and generally complicates immunocompromised individuals, especially those infected by human immunodeficiency virus (HIV). Here, we report an autochthonous case of talaromyces occurring in a non-HIV-infected Bangladeshi type 2 diabetic patient who presented with non-resolving pneumonia. To the best of our knowledge, this is the first talaromyces case being reported from Bangladesh.

Key words: *Talaromyces marneffi*, nonresolving pneumonia.

Received: 03.12.2022

Accepted: 12.12.2022

DOI: <https://doi.org/10.3329/bjm.v34i1.63430>

Citation: Haque HF, Ahmed AKMS, Hoque T, Saha RC, Afroz F. A first case report of *Talaromyces marneffi* infection presenting as a non-resolving pneumonia in a non-HIV diabetic patient from Bangladesh. *Bangladesh J Medicine* 2023; 34: 62-64.

Introduction:

Talaromyces marneffi, previously known as *Penicillium marneffi*, is a dimorphic fungus and can cause disseminated mycosis mainly in immuno-compromised individuals.¹ Geographically it is limited in Southeast Asia and it commonly occurs in patients with human immunodeficiency virus (HIV) infection and rarely occurs in patients with normal immunity.^{2,3} However, the incidence of talaromyces is gradually increasing in non-HIV patients. Here we report a case of talaromyces who presented with non-resolving pneumonia.

Case Report:

A 58-year-old farmer, diagnosed case of diabetes with poor glycaemic control, presented with 1-month history

of fever and cough. He did not have any history of traveling outside Bangladesh. Before presenting to our center, he required repeated admissions at different hospitals and was treated with broad-spectrum antibiotics without much benefit. Later on, empiric anti-tuberculosis drugs were added.

He was febrile with features of left sided consolidation. He had neutrophilic leukocytosis (17400/cmm) and chest imaging revealed consolidation (Figure:1a) with multiple cavitory lesions (Figure 1b). Bronchoscopy showed a tongue like projection in left upper bronchus (Figure:1c) and bronchoalveolar lavage was sent for bacterial and fungal

1. Assistant Professor of Medicine, BIRDEM General Hospital, Dhaka, Bangladesh.
2. Professor of Medicine, BIRDEM General Hospital, Dhaka, Bangladesh.
3. Senior Medical Officer of Dermatology, BIRDEM General Hospital, Dhaka, Bangladesh.
4. Registrar of Emergency Medicine, BIRDEM General Hospital, Dhaka, Bangladesh.
5. Assistant Professor of Respiratory Medicine, BIRDEM General Hospital, Dhaka, Bangladesh.

Address of Correspondence: Dr. Hasna Fahmima Haque, Assistant Professor of Medicine, , BIRDEM General Hospital, Dhaka, Bangladesh. E-mail: drfahmimahaque@gmail.com

Copyright: © 2023 Associations of Physicians of Bangladesh

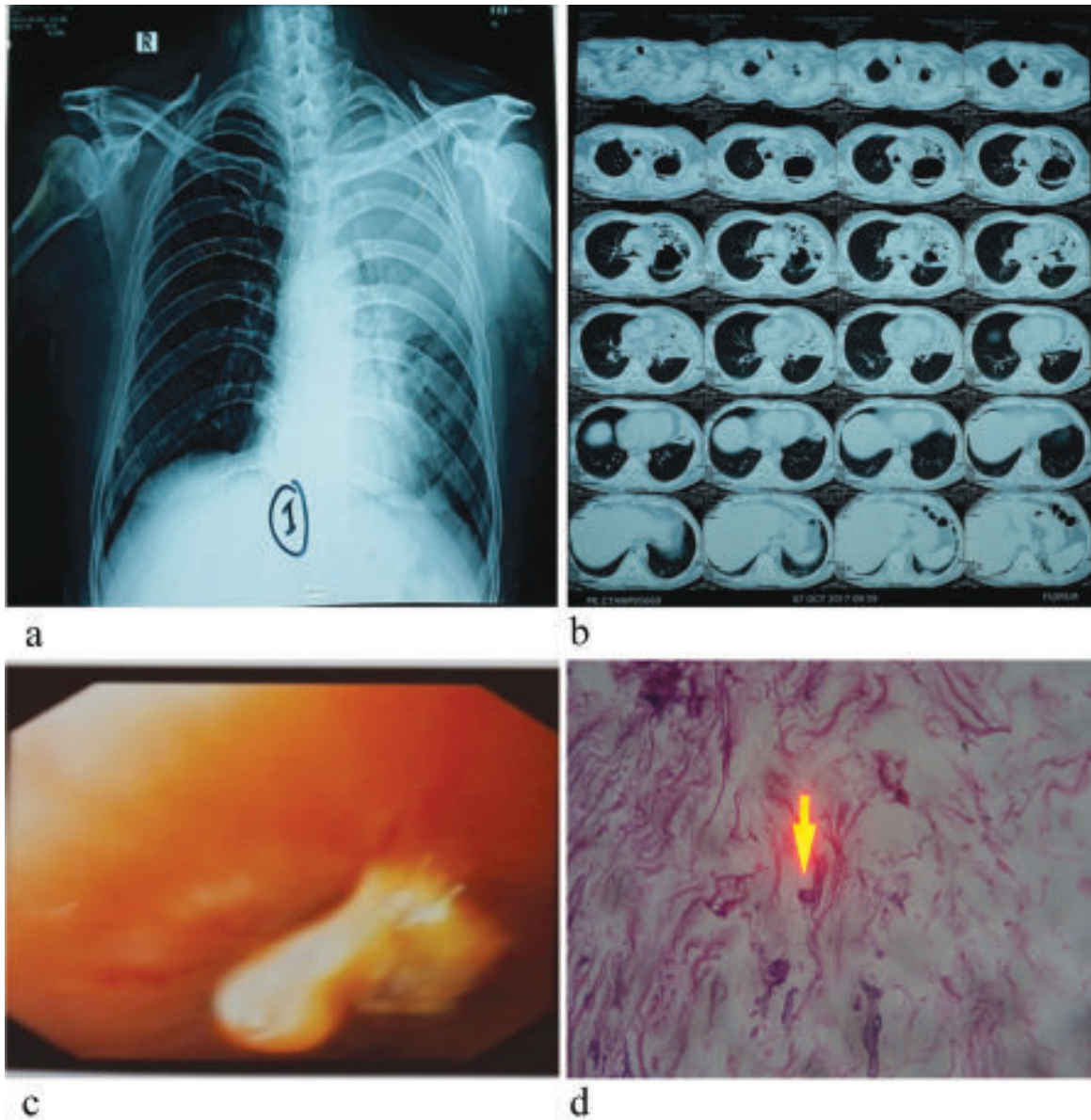


Fig.-1: a) Chest radiograph shows consolidation in the upper and mid zone of left lung b) Multiple cavitary lesions in left side on computed tomography of chest c) Bronchoscopy showed a tongue like projection in left upper bronchus d) Yeast-like cells were identified in histopathology.

culture, which revealed growth of *Pseudomonas* and *Talaromyces* respectively. Histopathological findings of bronchoscopic lung specimen (Figure: 1d) were consistent with the diagnosis of talaromycosis. Antibody against HIV appeared negative.

He was treated with injection colistin (according to sensitivity) and oral itraconazole. Other medications included insulin and paracetamol. Patient was discharged after two weeks with markedly improved clinical and radiological status. Antifungal treatment was continued up to 12 weeks.

Discussion:

The first reported human case of talaromycosis was in an American missionary with Hodgkin disease who lived in Southeast Asia.⁴ Almost 80% of the patients are immunocompromised like HIV infection and others are acquired cellular immune deficits such as transplant recipients, individuals with hematologic malignancies, those treated with steroids or cytotoxic agents, diabetes mellitus.^{5,6} *T. marneffeii* can infect various organs like lung, liver and skin.⁷

The clinical manifestations of talaromycosis vary from isolated skin lesions to respiratory failure and

circulatory collapse.⁸ Diagnosis can be made by demonstrating the characteristic morphologic findings of this fungus in biopsy material or in blood smears of patients with fungemia.⁹ The antifungal therapy causes clinical and microbiologic resolution of infection in up to 95 percent of patients.¹⁰ Our case was non-resolving pneumonia. Fungal culture, microscopic examination and histopathological study were done to establish the diagnosis and a long-term antifungal therapy was required for successful treatment outcome.

Conclusion:

We emphasize, careful history taking, physical examination and relevant investigations are required to reveal double pathology and to treat simultaneously for alleviating complications and mortality.

Consent: Informed consent was taken from the patient regarding publication of this case and accompanying images.

Acknowledgments:

We express our acknowledgements to the Department of Immunology and Histopathology, BIRDEM General Hospital, Dhaka, Bangladesh for support in laboratory evaluation of the patients.

Conflict of interest: Nothing to declare.

References:

1. Yilmaz N, Visagie CM, Houbraeken J, Frisvad JC, Samson RA,2014. Polyphasic taxonomy of the genus *Talaromyces*. *StudMycol* 78: 175-341. <https://doi.org/10.1016/j.simyco.2014.08.001>. PMID: 25492983 PMCID:PMC4255554
2. Hu Y, Zhang J, Li X, et al. *Penicillium marneffei* infection: an emerging disease in mainland China. *Mycopathologia* 2013;175:57-67. <https://doi.org/10.1007/s11046-012-9577-0>. PMID:22983901
3. Deng Z, Ribas JL, Gibson DW, et al. Infections caused by *Penicillium marneffei* in China and Southeast Asia: review of eighteen published cases and report of four more Chinese cases. *Rev Infect Dis* 1988;10:640-52. <https://doi.org/10.1093/clinids/10.3.640>. PMID:3293165

4. DiSalvo AF, Fickling AM, Ajello L. Infection caused by *Penicillium marneffei*: description of first natural infection in man. *Am J Clin Pathol.* 1973 Aug;60(2):259-63. doi:10.1093/ajcp/60.2.259. PMID: 4720403. <https://doi.org/10.1093/ajcp/60.2.259>. PMID:4720403
5. Wong SS, Wong KH, Hui WT, Lee SS, Lo JY, Cao L,Yuen KY. Differences in clinical and laboratory diagnostic characteristics of penicilliosis marneffei in human immunodeficiency virus (HIV)- and non-HIV-infected patients. *J Clin Microbiol.* 2001;39(12):4535. <https://doi.org/10.1128/JCM.39.12.4535-4540.2001>. PMID:11724878 PMCID:PMC88582
6. Li X, Hu W, Wan Q, Lei Q, Sun C, Hou Z, Shrestha N. Non-HIV talaromycosis: Radiological and clinical analysis. *Medicine* 2020;99:10 (e19185). <https://doi.org/10.1097/MD.00000000000019185>. PMID:32150056 PMCID:PMC7478776
7. Duong TA. Infection due to *Penicillium marneffei*, an emerging pathogen: a review of 155 reported cases. *Clin Infect Dis* 1996; 23:125. <https://doi.org/10.1093/clinids/23.1.125>. PMID:8816141
8. Sirisanthana V, Sirisanthana T. Disseminated *Penicillium marneffei* infection in human immunodeficiency virus-infected children. *Pediatr Infect Dis J* 1995; 14:935. <https://doi.org/10.1097/00006454-199511000-00003>. PMID: 8584358
9. Supparatpinyo K, Khamwan C, Baosoung V, Nelson KE, Sirisanthana T. Disseminated *Penicillium marneffei* infection in southeast Asia. *Lancet.*1994 Jul 9;344(8915):110-3. doi: 10.1016/s0140-6736(94)911287-4. PMID: 7912350. [https://doi.org/10.1016/S0140-6736\(94\)911287-4](https://doi.org/10.1016/S0140-6736(94)911287-4). PMID:7912350
10. Sirisanthana T, Supparatpinyo K, Perriens J, Nelson KE. Amphotericin B and itraconazole for treatment of disseminated *Penicillium marneffei* infection in human immunodeficiency virus-infected patients. *Clin Infect Dis.* 1998 May;26 (5):1107-10. doi: 10.1086/520280. PMID: 9597237. <https://doi.org/10.1086/520280>. PMID:9597237.