

CLINICAL IMAGE

MEDICAL QUIZ: IMAGE – 1

MUHAMMAD ABDUR RAHIM

Received: 05.12.2022

DOI: <https://doi.org/10.3329/bjm.v34i1.63434>

Accepted: 12.12.2022

Citation: *Clinical Image Bangladesh J Medicine 2023; 34: 65.*

A 60-year-old lady, diagnosed case of type 2 diabetes mellitus, systemic hypertension, stage 4 chronic kidney disease and dyslipidaemia, presented with a 3-day history of fever, vomiting and bilateral loin pain. She was febrile with a temperature of 102° F, tachycardic (pulse 112/min) and there was bilateral renal angle tenderness. She had neutrophilic leucocytosis (total white cells 23,100/cmm of blood with 93.3% neutrophils) and urine routine and microscopic examination revealed plenty of pus cells/ high power field. Urine and blood cultures were sent. Non-contrast abdominal computed tomography (CT) scan was performed and a coronal section is shown (Fig.-1). Study the film and answer following questions.

Questions

- Q 1. Mention abnormal CT finding.
- Q 2. What is the radiological diagnosis?
- Q 3. Mention one risk factor that might have contributed to the condition in this case.
- Q 4. Mention principles of management.

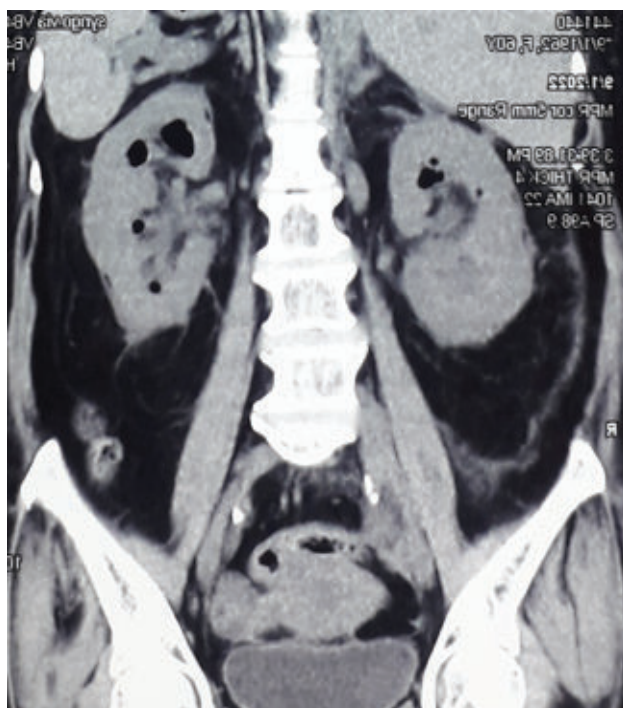


Fig.-1: CT scan of abdomen

Address of Correspondence: Dr. Muhammad Abdur Rahim, Associate Professor, Department of Nephrology, BIRDEM General Hospital, Dhaka-1000, Bangladesah. Email: muradrahim23@yahoo.com

Copyright: © 2023 Associations of Physicians of Bangladesh