

CLINICAL IMAGE

MEDICAL QUIZ: IMAGE – 2

AMINUR RAHMAN

Received: 05.12.2022

DOI: <https://doi.org/10.3329/bjm.v34i1.63435>

Accepted: 12.12.2022

Citation: *Clinical Image Bangladesh J Medicine 2023; 34: 66.*

A 49-year-old woman presented with low back and left leg pain of 4 years duration and a history of medication use for treatment of hypertension and diabetes mellitus for over 20 years. Neurological

examination revealed hypoesthesia of the left leg and no motor deficit, with normal deep tendon reflexes. Magnetic resonance imaging (MRI) of spine had done (Figure-1). Give the answer of the following questions:

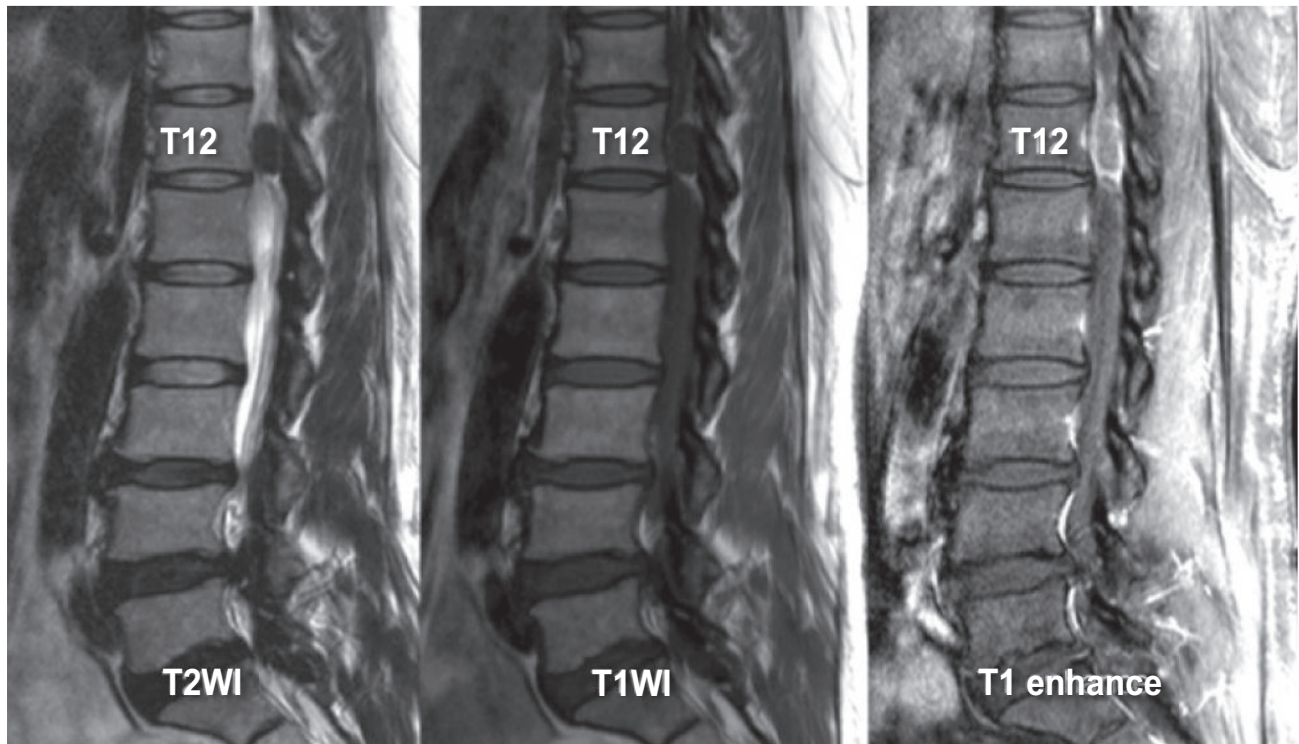


Fig.-1: MRI of spine

Questions

- Q1. What are the findings of the MRI ?
- Q2. What is the diagnosis?
- Q3. Enumerate 3 differential diagnosis?
- Q4. What is the treatment?

Address of Correspondence: Dr. Aminur Rahman, Assistant Professor, Dept of Neurology, Sir Salimullah Medical College, Mitford, Dhaka, Bangladesh. Email: draminur@yahoo.com, <https://orcid.org/0000-0001-9261-7734>

Copyright: © 2023 Associations of Physicians of Bangladesh