

## CLINICAL IMAGE

### MEDICAL QUIZ: IMAGE-2

REFAYA TASNIM<sup>1</sup>, QUAZI TARIKUL ISLAM<sup>2</sup>

Received: 14.12.2023

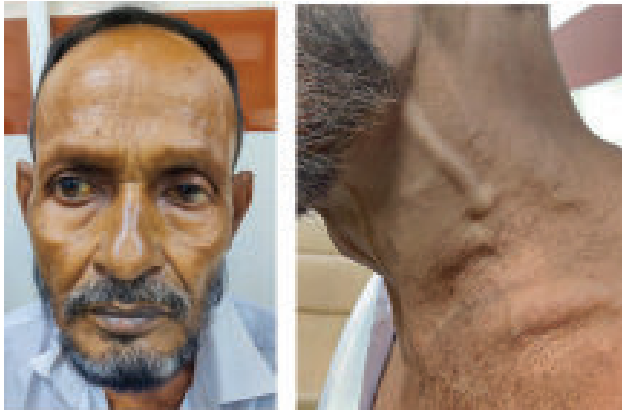DOI: <https://doi.org/10.3329/bjm.v35i1.70740>

Accepted: 19.12.2023

**Citation:** Tasnim R, Islam QT. Medical Quiz: Image-2. Bangladesh J Medicine 2024; 35: 49

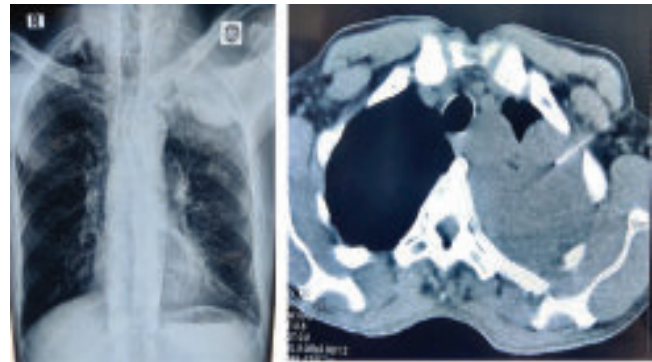
A 57-year-old hypertensive, non-diabetic ex-smoker male presented with a history of productive cough and left sided upper back pain with radiation of the pain to the front of the chest and left shoulder and arm for last 3 months. The pain was gradual on onset and now persistent, moderate in intensity and unremitting in nature. He also lost a significant amount of weight over this period.

On examination, he was generally emaciated, mildly anemic and his vitals were within normal limit. He had left sided incomplete ptosis of recent onset; pupils were equally reactive to light and normal in diameter



His full blood count showed, neutrophilic leucocytosis with markedly elevated ESR (100 mm in 1<sup>st</sup> hour), severe hyponatremia (117 mmol/L).

in both eyes. He also had left sided non-pulsatile engorged neck vein, there were no palpable peripheral lymphadenopathy. There was coarse crepitations involving whole lung field but most prominent over left apex with rhonchi. Neurological examination of upper limbs revealed intact sensory and motor functions.



**Question 01:** Write the radiological abnormalities in the chest x-ray and the CT chest.

**Question 02:** Mention 4 clinico-radiological differentials for this case.

**Question 03:** What are the best diagnostic modalities?

**Question 04:** Mention 3 possibilities if this patient presents with seizure.

1. Post graduate trainee of Internal Medicine, Bangabandhu Sheikh Mujib Medical University, Dhaka, Bangladesh

2. Professor, Department of Medicine, Popular Medical College, Dhaka-1205, Bangladesh

**Address of Correspondence:** Prof. Quazi Tarikul Islam, Professor, Department of Medicine, Popular Medical College, Dhaka-1205, Bangladesh. Email: [prof.tarik@gmail.com](mailto:prof.tarik@gmail.com)