

# THYMIC CARCINOMA : A RARE CAUSE OF SVC OBSTRUCTION

MOHAMMAD ABUL KALAM AZAD<sup>1</sup>, SHOHAEL MAHMUD ARAFAT<sup>2</sup>, MD. ARIFUL ISLAM<sup>3</sup>, MD. SHIRAJUL ISLAM<sup>4</sup>, MONZOOR QUADER<sup>5</sup>, ABM ABDULLAH<sup>6</sup>.

## Abstract

*Superior vena caval obstruction in majority of cases is caused by bronchial carcinoma. Thymic carcinoma which by itself is a rare malignancy is a very rare cause of superior vena caval obstruction. Here by we are reporting a young male of 26 year of age who presented to us with feature of superior vena caval obstruction caused by thymic carcinoma. Initially he was misdiagnosed as a case of tubercular mediastinal lymphadenopathy as a cause of superior vena caval obstruction but after proper evaluation and investigation he was confirmed as a case of thymic carcinoma. Considering the rare cause of SVO and unusual age of presentation, here we are reporting a case of thymic carcinoma.*

**Key word:** Thymic Carcinoma. Superior vena caval obstruction.

## Introduction

Superior vena cava (SVC) syndrome results from pathologic processes involving the right lung, lymph nodes, and other mediastinal structures, or by thrombosis of blood within the SVC<sup>1</sup>.

In the preantibiotic era, syphilitic thoracic aortic aneurysms and untreated infection were frequent causes of the SVC syndrome<sup>2,3</sup>. Subsequently, malignancy (90%) became the most common cause<sup>4,5</sup>. More recently, the incidence of SVC syndrome due to thrombosis has risen<sup>5,6</sup>. Benign causes now account for 20 to 40 percent of cases of SVC syndrome.

Thymic carcinoma is a rare tumour of the anterior mediastinum, which often invades adjacent organs such as the lungs, heart and great vessels. It is often asymptomatic and detected whilst investigating other problems, but may present

Thymic carcinoma is a rare tumour of the anterior mediastinum, which often invades adjacent organs such as the lungs, heart and great vessels. It is often asymptomatic and detected whilst investigating other problems, but may present with local cardiovascular or paraneoplastic symptoms. There is a well-known association between thymic tumours and myasthenia gravis. Surgery is the only curative modality,<sup>7</sup> but many patients are elderly with locally advanced disease. Palliative radiotherapy is often advocated.

## Case Report:

26 yr old male admitted with sudden onset of swelling of the face, neck and upper part of the chest and upper limbs. He also complained of sudden difficulty in breathing along with alteration of voice. There was

no associated pyrexia, cough or chest pain and he did not complain of any fatigue, muscular weakness, weight loss, or loss of appetite. He was otherwise systematically well in himself. He is a smoker with a 10 pack year history.

General examination revealed a plethoric face with congested conjunctiva and non-pulsatile prominent neck veins. There was no evidence of clubbing and no evidence of cervical or generalized lymphadenopathy.

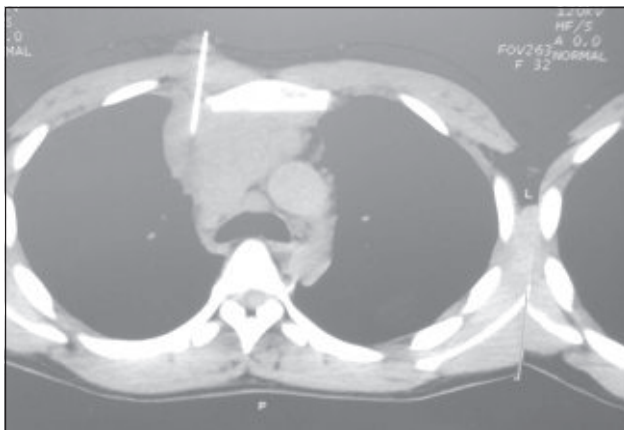
Respiratory examination revealed a respiratory rate 30resps per minute, trachea central, bilateral expansion on both side. Percussion note was resonant with good air entry. Other systemic examination revealed no abnormalities.

His chest x-ray revealed bilateral lobulated soft tissue shadow in superior mediastinal region and lateral view showed the retrosternal space to be full.

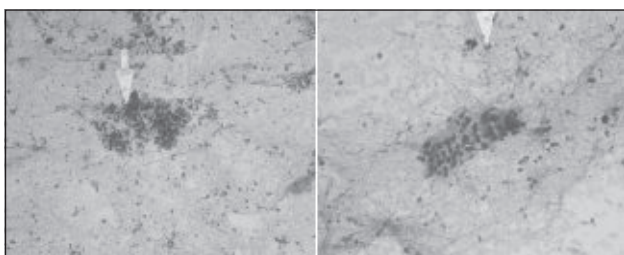
The patient's full blood count, liver and renal function tests were normal, however the lactate dehydrogenase enzyme (LDH) raised 921U/L. Montoux test was also negative. Ultrasound whole abdomen was normal but it did reveal a mild right-sided pleural effusion which not visible on chest X-ray. CT scan of the chest performed showed superior mediastinal mass (Fig.1)

CT guided FNAC showed a good number of epitheloid like round cells, some spindle-shaped cells which are compatible with features of thymic carcinoma. (Fig.-2). After confirming the thymic carcinoma he was referred to Cancer Hospital for definitive mangement.

1. Medical officer, Department of Medicine, BSMMU, Dhaka.
2. Associate Professor, Department of Medicine, BSMMU, Dhaka.
3. Medical officer, Department of Medicine, BSMMU, Dhaka.
4. Medical officer, Department of Cardiology, BSMMU, Dhaka.
5. Medical officer, Department of Medicine, BSMMU, Dhaka.
6. Professor and Dean, Faculty of Medicine, BSMMU, Dhaka.



**Fig.-1:** Mediastinal mass



**Fig.-2:** Showed epithelioid like round cells, some spindle-shaped cells which are compatible with features of thymic carcinoma.

### Discussion

Superior vena cava (SVC) syndrome results from pathologic processes involving the right lung, lymph nodes, and other mediastinal structures, or by thrombosis of blood within the SVC <sup>1</sup>.

In the preantibiotic era, syphilitic thoracic aortic aneurysms and untreated infection were frequent causes of the SVC syndrome <sup>2,3</sup>. Subsequently, malignancy (90%) became the most common cause <sup>4,5</sup>. More recently, the incidence of SVC syndrome due to thrombosis has risen <sup>5,6</sup>. Benign causes now account for 20 to 40 percent of cases of SVC syndrome.

Thymomas account for about 20 percent of mediastinal neoplasms. Most thymoma patients are between 40 and 60 years of age, and there is slight male predominance. There are no known risk factors. Thymic carcinomas account for less than 1 cent of thymic malignancies <sup>8</sup>

Symptoms from a thymoma or thymic carcinoma may be due to the presence of a tumor in the mediastinum or may be a manifestation of a paraneoplastic syndrome. Up to one-half of thymomas are diagnosed incidentally, based upon a radiographic abnormality in an asymptomatic patient.

Clinical signs and symptoms are related to the size of the tumor and its effects on adjacent organs (eg, chest pain, shortness of breath, cough, phrenic nerve palsy, superior vena cava obstruction). Less commonly, systemic ("B") symptoms including fever, weight loss, and/or night sweats may be present.

Pleural or pericardial effusions are the most common manifestation of metastatic involvement. Extrathoracic metastases occur in less than 7 percent of patients, most commonly to the kidney, extrathoracic lymph nodes, liver, brain, adrenals, thyroid and bone <sup>9</sup>. Metastases to the ipsilateral lung are unusual.

Thymomas are associated with a wide variety of paraneoplastic disorders, the most common of which is myasthenia gravis. These syndromes are seen in 50 to 60 percent of patients, and more than one syndrome may be present.

Thymomas account for about 20 percent of mediastinal neoplasms.

Thymic carcinoma is defined as a thymic epithelial tumor with a high degree of histological anaplasia, obvious cell atypia and increased proliferative activity, which closely resembles carcinoma seen in other organs and is unassociated with immature T cells <sup>10</sup>. Although thymic carcinomas are distinct neoplasms that differ from thymoma, the classification of thymic carcinoma is controversial. A variety of histopathological subtypes of thymic carcinoma have been reported in literature such as squamous cell, spindle cell, lymphoepithelioma like, sarcomatoid, basaloid, small cell, mucoepidermoid, clear cell, mixed and undifferentiated carcinomas <sup>11-16</sup>. Further, Suster and Rosai <sup>17</sup> reported 60 patients with thymic carcinoma and classified them into two prognostic groups based on pathological criteria (low-grade versus high-grade histological type). Thymic carcinoma occurs over a broad age range, with an average of 46 years. Localization of thymoma resembles that of the thymus itself with 75% of thymomas originating in the anterior mediastinum, 15% originating in both the anterior and superior mediastinum, and 6% originating in the superior mediastinum <sup>18</sup>. The other 4% occur ectopically. Diagnosis of thymic carcinoma is suspected by presence of areas of necrosis, hemorrhage, calcification within the mass, or cyst formation; gross invasion of contiguous mediastinal structures and wide spread to involve distant intrathoracic sites and high incidence of extrathoracic metastases. Although paraneoplastic syndromes such as myasthenia gravis, pure red cell aplasia and autoimmune diseases are frequently seen in patients with thymoma but they are extremely rare in cases with thymic carcinoma <sup>14, 19, 20</sup> as seen in our case.

The prognosis is often very guarded owing to the propensity of thymic carcinoma to invade adjacent organs: the median survival from diagnosis is around 2 years.<sup>21</sup> Surgery remains the only curative modality, although complete resection is rarely possible, most patients presenting with advanced disease.

### Conclusions

Thymic carcinoma is very rare cause of superior vena caval obstruction. It is hoped that this case report will highlight the need occasionally to consider unusual causes for symptoms and signs related superior vena caval obstruction.

### References

1. Garcia Monaco, R, Bertoni H, Pallota G, et al. Use of self-expanding vascular endoprostheses in superior vena cava syndrome. *Eur J Cardiothorac Surg* 2003; 24:208.
2. Wilson LD, Detterbeck FC, Yahalom J. Clinical practice. Superior vena cava syndrome with malignant causes. *N Engl J Med* 2007; 356:1862.
3. Schechter MM. The superior vena cava syndrome. *Am J Med Sci* 1954; 227:46.
4. Yellin A, Rosen A, Reichert N, Lieberman Y. Superior vena cava syndrome. The myth—the facts. *Am Rev Respir Dis* 1990; 141:1114.
5. Rice TW, Rodriguez RM, Light RW. The superior vena cava syndrome: clinical characteristics and evolving etiology. *Medicine (Baltimore)* 2006; 85:37.
6. Chee, CE, Bjarnason, H, Prasad, A. Superior vena cava syndrome: an increasingly frequent complication of cardiac procedures. *Nat Clin Pract Cardiovasc Med* 2007; 4:226.
7. Loehrer PJ, Wick MR. Thymic Malignancies. *Cancer Treat Res* 2001; 105: 277—302.
8. Tumours of the thymus, in Travis, WD, Brambilla, E, Muller-Hermelink, HK, Harris, CC. *Pathology & genetics: Tumours of the lung, pleura, thymus and heart*. In: World Health Organization Classification of tumours. IARC Press, Lyon, 2004.
9. Lewis, JE, Wick, MR, Scheithauer, BW, et al. Thymoma. A clinicopathologic review. *Cancer* 1987; 60:2727.
10. Shimosato Y, Mukai K. Tumors of the mediastinum. In: *Atlas of Tumor Pathology*, 3rd series, fascicle 21. Washington, DC: Armed Forces Institute of Pathology, 1997; 120-121.
11. Levine GD, Rosai J. Thymic hyperplasia and neoplasia: a review of current concepts. *Hum Pathol* 1978; 9: 494-515.
12. Snover DC, Levine GD, Rosai J. Thymic carcinoma: five distinctive histological variants. *Am J Surg Pathol* 1982; 6:451-470.
13. Marino M, Muller-Hermelink HK. Thymoma and thymic carcinoma. Relation of thymoma epithelial cells to the cortical and medullary differentiation of thymus. *Virchows Arch A* 1985; 407:119-149.
14. Truong LD, Mody DR, Cagle PT, Jackson-York GL, Schwartz MR, Wheeler TM. Thymic carcinoma. A clinicopathologic study of 13 cases. *Am J Surg Pathol* 1990; 14: 151-166.
15. Hsu CP, Chen CY, Chen CL, Lin CT, Hsu NY, Wang JH, et al. Thymic carcinoma. Ten years experience in twenty patients. *J Thorac Cardiovasc Surg* 1994; 107: 615-620.
16. Chang HK, Wang CH, Liaw CC, Ng KT, Chang JP, Chen MS, et al. Prognosis of thymic carcinoma. Analysis of 16 cases. *J Formos Med Assoc* 1992; 91:764-769.
17. Suster S, Rosai J. Thymic carcinoma. A clinicopathologic study of 60 cases. *Cancer* 1991; 67: 1025-1032.
18. Rosai J, Levine GD. Tumors of the Thymus. Armed Forces Institute of Pathology, Washington, DC, 1975.
19. Shimosato Y, Kameya T, Nagai K, Suemasu K. Squamous cell carcinoma of the thymus. An analysis of eight cases. *Am J Surg Pathol* 1977; 1:109- 121.
20. Wick MR, Weiland LH, Scheithauer BW, Bernatz PE. Primary thymic carcinomas. *Am J Surg Pathol* 1982; 6: 613-630.
21. Detterbeck F, Parsons A. Thymic tumors. *Ann Thorac Surg* 2004; 77: 1860-9.