

CASE REPORTS

ADULT TYPE CHRONIC MYELOID LEUKAEMIA IN AN 11 YEAR OLD GIRL- A VERY UNUSUAL CASE REPORT

HOMAYRA TAHSEEN HOSSAIN¹, QUAZI TARIKUL ISLAM², MUNSHI M B MD. SHOAIB ADNAN³, MD. ABUL KASHEM KHANDAKER⁴

Abstract:

Chronic Myeloid Leukaemia is very uncommon in children. It accounts for 2 to 5% of all the childhood leukaemias. The incidence is < 1 case per 1,00,000 population in younger than 20 years of age per year. Two distinct forms have been described- namely the Juvenile and Adult type. Absence of Philadelphia chromosome is the hallmark of Juvenile type CML (JCML). Adult type CML is extremely rare in childhood. Here, we report one such a case of adult type of CML in an 11 year old girl who presented to us with pallor, fever and hepato-splenomegaly. At presentation, it seems to be a case of Visceral Leishmaniasis. But, peripheral blood film and bone marrow features were consistent with CML. Philadelphia chromosome was positive. Though biological behavior and prognosis are identical to that of adult CML, we are reporting this case because of its extremely uncommon incidence.

Key words: Chronic Myeloid Leukaemia, Juvenile and Adult type CML, Philadelphia chromosome

Received: 12 January 2014

Accepted: 19 June 2014

Introduction:

Chronic Myeloid Leukaemia (CML) is a myelo-proliferative stem-cell disorder and is almost exclusively a disease of adults with the peak of presentation being between 40 and 60 years.¹ This clonal stem cell disorder is characterized by a proliferation of myeloid cells at all stages of differentiation and the t (9:22) (q34: q:11) leading to formation of BCR-ABL fusion gene. CML is uncommon in childhood, accounting for only 2 to 5% of all leukaemias.² It has incidence of < 1 case per 1, 00,000 population younger than 20 years of age per year^{3,4}.

About 50 years ago, two forms of CML were recognized in children. One had the typical features of CML of adulthood and usually appeared in children older than 4 years; the other affected younger children (median age 1-4 years) and presented as a myelomonocytic proliferation associated with hemorrhage, infection, lymphadenopathy, and skin rash. The prognosis of the latter group of patients was invariably poor⁵⁻⁷. Reisman and Trujillo found the absence of the Philadelphia (Ph) chromosome to be a hallmark of the juvenile-type entity (JCML)⁸. Philadelphia (Ph)

chromosome is rarely seen in children⁹. Maurer and others concluded that JCML is accompanied by a reversion to fetal-like erythropoiesis¹⁰⁻¹² that is low level HbA2 and marked increase of HbF¹³ and glucose-6-phosphate dehydrogenase activity¹⁴.

Case Report:

An 11 years old school going girl, hailing from Faridpur was admitted in Popular Medical College Hospital on February 2014 with the complaints of gradually increasing left sided abdominal lump for 2 months, mild abdominal dragging pain at left side of abdomen for 7 days which has no relation with food intake and history of high grade fever for 3-4 days 15 days back. On query, she gave history of drenching night sweat for last 3 weeks. She also had generalized weakness. Her appetite, bowel and bladder habit were normal. There was no weight loss, no history of blood loss from any site, no skin rash.

Her mother gave history of recurrent attacks of cough and cold since childhood for which she needed frequent courses of antibiotics. Her milestone of development was normal. There was no history of consanguinity

1. Assistant Professor, Medicine, Popular Medical College Hospital, Dhaka
2. Professor of Medicine, Popular Medical College Hospital, Dhaka
3. Registrar, Medicine, Popular Medical College Hospital, Dhaka
4. Professor and Head, Popular Medical College Hospital, Dhaka

Address of Correspondence: Dr. Homayra Tahseen Hossain, Assistant Professor, Medicine, Popular Medical College Hospital, Dhaka email: prof.tarik@gmail.com

of marriage between her parents. Her 3 sisters and 2 brothers were in good health. The patient was immunized as per EPI schedule.

General examination revealed, the patient was pale, having average body built according to her age, moderately anaemic, not icteric, cervical lymphadenopathy present involving both sided anterior chain, 0.5- 1.0 cm size, non tender, firm, mobile. Her vital parameters were within normal limit. Bony tenderness was absent. Skin condition normal.

Examination of abdomen revealed hepatosplenomegaly. Liver was enlarged, 4 cm from right costal margin in mid clavicular line, firm, non tender, smooth surface, no hepatic bruit or rub present. There was huge splenomegaly 12.5 cm from left costal

margin along its long axis crossing midline, firm to hard in consistency, non tender, notch present at superior border. [Fig.-1]

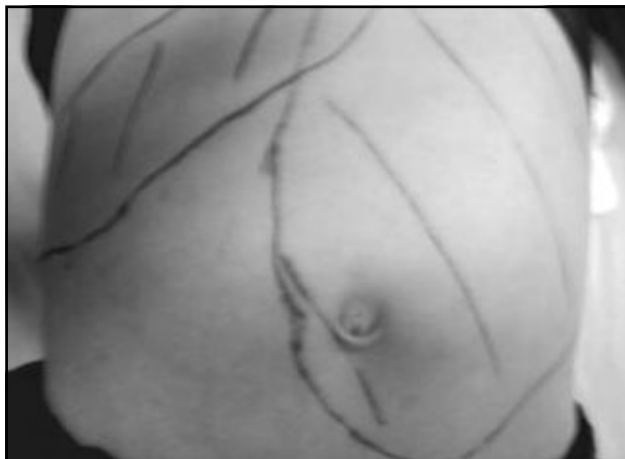


Fig-1: Hepatosplenomegaly

A young girl presented with fever, anaemia and hepatosplenomegaly- our initial suspicion was Visceral Leishmaniasis.

Investigations on admission: a. CBC- TC 221.38 K/ μ L, DC revealed Neutrophil 54%, Lymphocyte 4%, Monocyte 2%, Eosinophil 0%, Basophil 1%, Myeloblasts 1%, Promyelocytes 1%, Myelocytes 17%, Metamyelocytes 20%. Haemoglobin 7.42 g/dL, Platelets 915.00 K/ μ L, ESR 20 mm in 1st hour. PBF-RBC shows anisochromia with anisocytosis. WBC show gross leucocytosis & moderate shift to the left with distribution shown above. Platelets are increased in number. Comment: Features are consistent with CML [Fig 3]

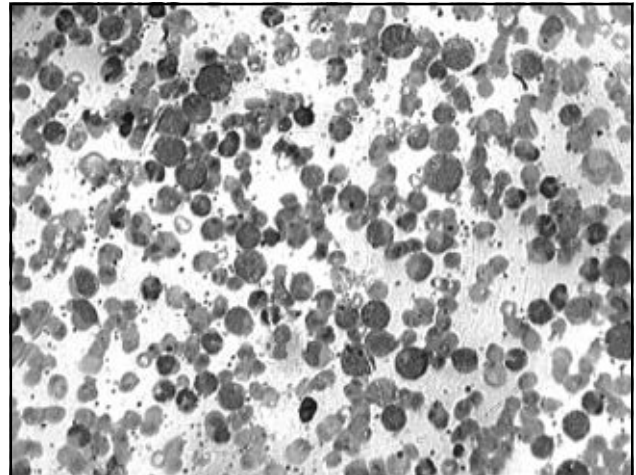


Fig-2: Photomicrograph of blood smear of patient showing marked leucocytosis with shift of myeloid series

b. Haemoglobin electrophoresis-

HbA	97.2%
HbA2	2.8%
Comment	Normal study

c. USG of whole abdomen-

1. Mild hepatomegaly
2. Huge enlargement of spleen

d. Bone marrow study- Hypercellular marrow with increased M/E ratio. Erythropoiesis is depressed & normoblastic. Granulopoiesis is hyperactive, shift to left & significant number of myelocytes, basophils & eosinophils present. Megakaryocytes are increased & dysplastic. [Fig 4]

Comment: Bone marrow findings are consistent with chronic myeloid leukaemia.

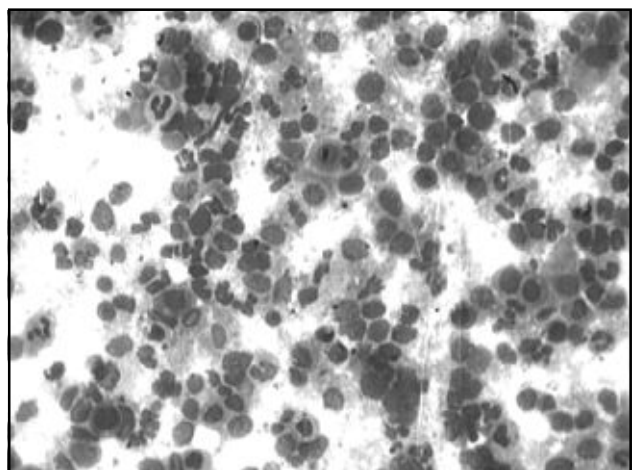


Fig-3: A bone marrow aspirate smear shows hypercellular marrow with myeloid predominance

f. BCR-ABL gene rearrangement study (Real time PCR) - To confirm the type of CML, we have done this test, which revealed Positive result that means the patient is Philadelphia chromosome positive.

On the basis of clinical features and laboratory findings, we diagnosed her as a case of adult type CML : a very rare condition. As per advice of haemato-oncologist, definitive treatment with Imatinib was started on 23rd February'14.

After starting chemotherapy, there was gradual reduction of the size of spleen & consistency also became softer.8 weeks after starting treatment, size of spleen became 6.5 cm (initial size- 12.5 cm).

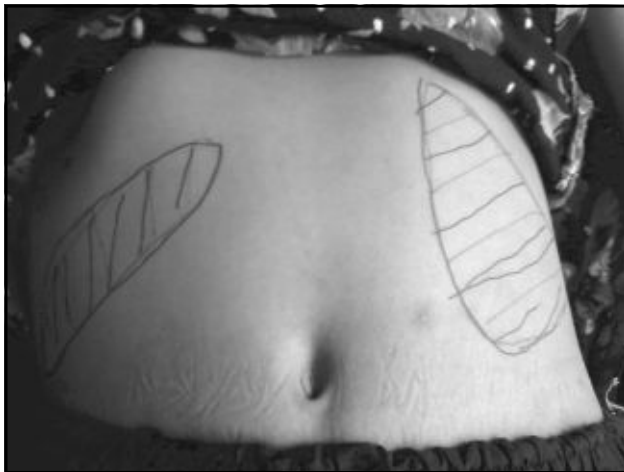

Fig.-4: Hepatosplenomegaly : 8 weeks after treatment

There was marked improvement of her blood picture with gradual disappearance of immature WBC.

	18.02.14 (on admission)	01.03.14 (1 wk after treatment)	10.04.14 (8 wk after treatment)
Total count of WBC	221.38 K/ μ L	160.0 K/ μ L	21.10 K/ μ L
Neutrophil	54%	80%	76%
Lymphocyte	4%,	2 %	17%
Monocyte	2%,	3 %	3%
Eosinophil	00%	4 %	4%
Basophil	1%,	1 %	00%
Myeloblasts	1%	00 %	00%
Promyelocytes	1%	00 %	00%
Myelocytes-	17%	5 %	00%
Metamyelocytes	20%	5 %	00%
Haemoglobin	7.42 g/dL	11.20g/dL	11.40 g/dL
Platelets	915.00 K/ μ L	650.00K/ μ L	620.00 K/ μ L
ESR	20 mm in 1 st hour	3 mm in 1 st hour	03 mm in 1 st hour

The patient was advised to come for follow up after 1 month.

Discussion:

Amongst childhood leukemias, chronic myeloid leukemia (CML) is a rare entity with an annual incidence of one case per million children¹⁵. Adult type of CML in children is even rarer and is characterized by Philadelphia chromosome [t (9:22)] positivity ^{16,17}. BCR -ABL fusion gene is better prognostic variant in children.

CML in childhood presents as one of the two clinically distinct syndromes i.e. adult type CML (ACML) which is Philadelphia positive, and juvenile CML (JCML), which is currently known as Juvenile Myelomonocytic Leukemia (JMML)¹⁶. JCML is Philadelphia negative.

We report one such a case of adult type CML in an 11 year old girl on the basis of clinical features and investigations. Presence of Philadelphia (Ph) chromosome and normal Haemoglobin electrophoresis differentiate this case from JCML.

Clinical features of adult type CML in children are similar to that seen in CML occurring in adults. Hepatomegaly, splenomegaly, generalized lymphadenopathy, anemia and

hyperleukocytosis has been observed in all patients^{9,18}. The mean spleen size has been 13 cm and ranged from 8-22 cm as per Sinniah et al⁹. Our patient also had abdominal distension with huge splenomegaly (12.5 cm) and hepatomegaly. Her peripheral blood film showed anaemia with gross leucocytosis with full range of granulocyte precursors. In about one- third of patients of CML, there is a very high platelet count ¹⁹ as also in our patient (915.00 K/ μ L).

Routine haemogram, Peripheral smear, Bone marrow and Ph chromosome (BCR -

ABL) confirms the diagnosis of adult type CML. This needs to be differentiated from the other form of myeloproliferative disorder like Juvenile Myelomonocytic Leukemia (JMML).

The term JMML is presently used to include Juvenile CML, Chronic Myelomonocytic Leukemia and infantile Monosomy 7 syndrome²⁰. The disease mimics morphologically and clinically most closely to CML, but has unique biological characteristics. According to WHO classification, JMML is one of the bridging MDS/MPD category of myeloid neoplasms²¹. JMML represents 18-36% of MDS in children and about 2% of hematologic malignant neoplasms. It occurs predominantly in infants and young children less than 2 years². Hepatomegaly, lymphadenopathy, recurrent infections and bleeding are the hallmarks of JMML [2] with Leukocytosis with monocytosis [$> 5000 / ml$

i.e. ($> 5 \times 10^9 / L$]). Eosinophilia and basophilia are observed in minority of the patients^{2, 21}. JMML is Ph chromosome negative with aggressive clinical course. These features have been absent in our case.

In the past, antimetabolites (e.g., cytarabine, hydroxyurea), alkylating agents, interferon alfa 2b, and steroids were used as treatments of CML in the chronic phase, but since 2000s have been replaced by BCR-ABL tyrosine-kinase inhibitors drugs, the first of this new class of drugs was imatinib mesylate approved by the U.S. FDA in 2001. Imatinib specifically inhibits BCR ABL tyrosine kinase activity and reduces the uncontrolled proliferation of white cells. It is recommended as first line therapy in chronic phase CML, producing complete cytogenetic response (disappearance of Ph chromosome) in 76% at 18 months of therapy¹⁹. Since the advent of imatinib, CML has become the first cancer in which a standard medical treatment may give to the patient a normal life expectancy²²

In our patient, after confirmation of diagnosis, we have started treatment with Imatinib 200 mg once daily which gave a very good response both clinically and by investigations. We are eagerly waiting to see the long term outcome of this young girl with adult type CML- a very rare disease.

References:

1. Parveen Kumar, Michael Clark (edi). Kumar & Clark's Clinical Medicine. 8th edition. 2012: 455-458.
2. Emanuel PD. Myelodysplasia and Myeloproliferative disorders in childhood: An update. Br J Hematol 1999; 105: 852-863.
3. Hernandez JA, Land KJ, McKenna RW. Leukemias, myeloma, and other lymphoreticular neoplasm. Cancer. 1995; 75: 381-94.
4. Castro - Malaspina H, Schaison G, Briere J, et al. Philadelphia chromosome -Positive chronic myeloid leukemia in children: Survival and prognostic factors. Cancer. 1983; 52: 721-27.
5. Eisenberg AA, Wallerstein H. Chronic myelosis in children. J Lab Clin Med 1934; 19: 713.
6. Cooke JV: Chronic myelogenous leukemia in children. J Pediatr 1953; 42: 537.
7. Bernard J, Mathe G, Delorme JC, Barnoud O: La leucemiemyeloide chronique de l'enfant. Arch Fr Pediatr 1962; 19: 881.
8. Reisman LE, Trujillo JM: Chronic granulocytic leukemia of childhood. Clinical and cytogenetic studies. J Pediatr 1963; 62: 710.
9. Sinniah D, Ariffin WA, Shiong HW, Lin HP. Chronic myeloid leukemia in Malaysian children. Singapore Medical Journal. 1981; 22 (6): 350-353.
10. Maurer HS, Vida LN, Honig GR: Similarities of the erythrocytes in Juvenile Chronic Myelogenous Leukemia to fetal erythropoiesis. Blood 39:778, 1972
11. Wheatherall DJ, Clegg JB, Wood WG: Foetal erythropoiesis in human leukemia. Nature 1975; 257:710.
12. Weinberg RS, Leibowitz D, Weinblatt ME, Kochen J, Alter BP: Juvenile Chronic Myelogenous Leukemia: The only example of truly fetal (not fetal-like) erythropoiesis. Br J Haematol 1990; 76: 307.
13. Hardisty RM, Speed DE, Till M: Granulocytic leukemia in childhood. Br J Haematol 1964; 10: 551.
14. Cao A: Juvenile chronic myeloid leukemia. Lancet 1970; 1:1002.
15. Millot F, Traore P, Guihot J, Welken B, Leblanc T, et al. Clinical and biological features at diagnosis in 40 children with chronic myeloid leukemia. Pediatrics. 2005; 116: 140-43.
16. Hess JL. Juvenile Chronic Myelogenous Leukemia (JMML). Atlas Genet Cytogenet Oncol Haematol. December 2000.
17. Malhotra KP, Sharma CB, Jain J, Grover RK. Is b3a2 a better prognostic variant in childhood chronic myeloid leukemia. Journal of postgraduate medicine. 2010; 56(3): 212-222.
18. Mishra A, Tripathi K, Mohanty L and Pujari S. Philadelphia Chromosome positive chronic myeloid leukemia in a child: A case report. Indian Jr Hemat Blood Transfusion 2010; 26 (3): 109-110.
19. Nicki R Colledge, Brian R. Walker, Stuart H. Ralston (edi). Davidson's Principles & Practice of Medicine. 21st edition. 2010: 1034-35.
20. Rabinowitz I, Larson RS. Chronic myeloid leukemia. In: Greer JP, Foerster J, Lukens JN, Rodgers GM (edi). Wintrob's clinical hematology. Lippincott Williams and Williams. 11th edition. Volume 2. 2004: 2235-44.
21. Vardiman JW, Pierre R, Imbert M, et al. Juvenile myelomonocytic leukemia. In: Jaffe ES, Harris NL, Stein H, et al. Pathology and Genetics of Haematopoietic and Lymphoid Tissues. World Health Organization Classification of Tumors. Lyon, France: IARC Press; 2001:55-57.
22. Gambacorti-Passerini, C.; Antolini, L.; Mahon, F. - X.; Guilhot, F.; Deininger, M.; Fava, C.; Nagler, A.; Della Casa, C. M.; Morra, E.; Abruzzese, E.; d'Emilio, A.; Stagno, F.; Le Coutre, P.; Hurtado-Monroy, R.; Santini, V.; Martino, B.; Pane, F.; Piccin, A.; Giraldo, P.; Assouline, S.; Durosini, M. A.; Leeksa, O.; Pogliani, E. M.; Puttini, M.; Jang, E.; Reiffers, J.; Valsecchi, M. G.; Kim, D. -W. (2011). "Multicenter Independent Assessment of Outcomes in Chronic Myeloid Leukemia Patients Treated with Imatinib". JNCI Journal of the National Cancer Institute 103 (7): 553-561.