

THROMBOTIC THROMBOCYTOPENIC PURPURA: A CASE REPORT

SABRINA SHAHRIN¹, RAKESH PANDAY², MD. NIAZ MOSTOFA³, MOUSUMI SANYAL⁴, MD. MOTLABUR RAHMAN⁵, AKM AMINUL HAQUE⁶

Abstract:

Thrombotic thrombocytopenic purpura is a multisystemic microvascular disorder that may be caused by an imbalance between unusually large vWF multimers and the cleaving protease ADAM TS 13¹ (A disintegrin and metalloproteinase with a thrombospondin type 13). This disease was first described by Moshocowitz in 1924.² It is clinically characterized by five typical syndromes: thrombocytopenia, microangiopathic hemolytic anaemia, renal impairment, fluctuating neurological abnormalities and fever. It is a rare disease and fatal in 50 to 80 per cent of cases⁵. TTP can be idiopathic or secondary. Here we are describing a case who developed fever, purpuric spot, jaundice, renal impairment and fluctuating neurological features. Initially it seems to us as a case of DIC, but later hematological evaluation reveals it as a case of TTP, as the patient fulfills the pentad criteria. Unfortunately we could not do the serum ADAM TS 13 level because of lack of facility in our country and in abroad it is costly.

Received: 04 May 2014

Accepted: 19 December 2014

Case Presentation: We are reporting a case of a 14 year old boy hailing from Gauranadi, Barishal who presented to us with 2 months history of fever. Initially fever was treated as enteric fever for 10 days. After that fever subsided but later he again developed high grade continued fever. At that time he also developed jaundice, which was static in nature. During the course of his admission he developed blood mixed vomiting, which was fresh initially, but became coffee ground later. Simultaneously he developed passage of black stool 4-5 times per day which was soft in consistency with foul smell, sticky. He also developed convulsion, rigidity, tremor.

There was also visual and gustatory hallucination. Patient also noticed development of rashes which were purpuric & distributed over face and abdomen, the rash were palpable & associated with central desquamation, there was no itching. These rashes were subsided after giving steroid. Subsequently he became anuric. But became improved after fluid and diuretics therapy.

On physical examination we found the patient was severely anaemic, moderately icteric. There was ulceration in oral cavity involving palate. His abdomen

was distended, flanks were full, liver was enlarged about 5 cm from the right costal margin along the right mid clavicular line, firm in consistency, smooth, non tender with a sharp border, upper border of liver dullness was at right 5th intercostal space. There was no other organomegaly and shifting dullness was positive. On nervous system examination we observed that his higher psychic function was intact initially but later he developed a fluctuating level of consciousness. His muscle tone was increased all over the body, so his jerks were not properly evaluated. There was pill rolling movement of both hands and generalized convulsion was seen for several episodes.

Before admission, investigation shows Hb- 6.0 gm/dl, S.bilirubin-9.3 mg/dl, PT-23.6 S & after admission Hb- 3.3 gm/dl, ESR- 05 mm, TC-4130/cmm, Platelets-19000/cmm. After giving four bags of transfusion, Hb-9.4 gm/dl, ESR-20 mm, TC-3200/cmm, Platelet-37700/cmm. On 5th day reticulocyte-2.99%. S.bilirubin decreased gradually. USG suggested acute hepatitis. S.ferritin was high. FDP & D-dimer were increased. Others important investigations are shown in tables.

1. MO (Med. Unit-VII, DMCH)
2. HMO (Med. Unit-VII, DMCH)
3. HMO (Med. Unit-VII, DMCH)
4. HMO (Med. Unit-VII, DMCH)
5. Assistant Professor (Med. Unit-VII, DMCH)
6. Associate Professor (Med. Unit-VII, DMCH)

Address of Correspondence: Dr. Sabrina shahrin, MO (Med. Unit-VII, DMCH)

INV	1 ST DAY	2 ND DAY	5 TH DAY	34 TH DAY	41 ST DAY	44 th DAY
CBC	Hb-3.3 gm/dl	Hb-9.4 gm/dl	Hb-9.1 gm/dl	Hb-7 gm/dl	Hb-6 gm/dl	Hb-10 gm/dl
	ESR-05 mm	ESR-20 mm		ESR-130 mm	HCT-18.7%	
	MCV-75 fl	MCV-82 fl				
	MCH-25 pg	MCH-41.9 Pg	RET-2.6%	RET-2.99%	RET-2.32%	
	MCHC-33.3 gm/dl	MCHC-51 gm/dl				
	TC-4130/cmm	TC-3200 /cmm	TC-5640 /cmm	TC-10000/cmm	TC-11510/cmm	TC-11000/cmm
	N-62.5%. L-32.9%	N-62.9% L-32.6%			N-75% L-18.3%	
	Plat-19000/cmm	Plat-37700/cmm	Plat-22000/cmm	Plat-3.5 lac/cmm	Plat-4.23lac/cmm	Plat-4.48 lac/cmm
PBF	Microangiopathic hemolytic anaemia			Dimorphic anaemia	Normochromic normocytic anaemia	

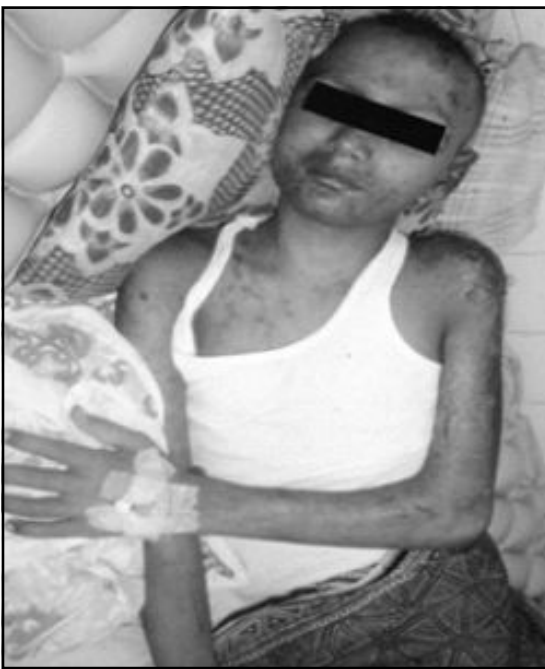

Fig.-1: PBF of MAHA

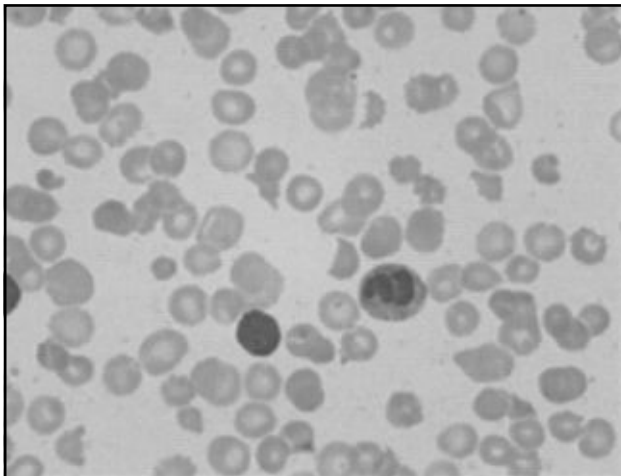


Fig.-2: PBF of MAHA

INV	4 TM DAY	14 TM DAY	45 TM DAY
S.Bilirubin	8.85 mg/dl	3.21 mg/dl	0.6 mg/dl
INV	4 TM DAY		
HBsAg	Negative		
Anti HBc Ab	"		
Anti HCV	"		
Anti HAV	"		
Anti HEV	"		
Anti Dengu IgM	"		
ICT for Malaria	"		
ICT for Kala-azar	"		
INV	5 th DAY		
PT	125		
INR	1.01		

Coomb's test (direct & indirect)Negative

INV	6 TH DAY	14 TH DAY
S.Creatinine	1 mg/dl	0.45 mg/dl
S.Urea	53 mg/dl	51mg/dl
FDP	15 mcg/dl	
D-dimer	11.3 ng/dl	
SGPT	110 U/l	

USG of W/A Suggestive of acute hepatitis Mild to moderate ascities Bilateral renal parenchymal disease

INV	14 TH DAY	20 TH DAY	28 TH DAY	45 TH DAY
S. Electrolytes	Na-143 mmol/l	Na-122 mmol/l	Na-129 mmol/l	Na-134 mmol/l
	K-2.7 mmol/l	4.5 mmol/l	K-3.8 mmol/l	K-4.4 mmol/l
	Cl-107 mmol/l	Cl-93 mmol/l	Cl-98 mol/l	Cl-102.26 mmol/l
S.Ceruloplasmin		268.60 ng/dl		
24hrs urine Cu		85 mcg/l		
Endoscopy of Upper GIT			Gastropathy	

INV	23 TH DAY	29 TH DAY	40 TH DAY
ANA	Negative		
p-ANCA	“		
c-ANCA	“		
S.Ferritin		1075 ng/ml	
S.LDH			275 U/L
CSF study	Sugar-72 mg/dl Protein-20 mg/dl Total cell- 04/cmm No AFB/ Organism		
MRI	Normal		
Blood for C/S	No growth		

Discussion:

Our patient initially presented with bloody diarrhea, jaundice, fever and bleeding from oral mucosa. Typical childhood HUS (hemolytic uremic syndrome) presents with an episode of abdominal pain and bloody diarrhoea that is most often due to shiga toxin producing enterohemorrhagic E. Coli, while TTP usually affect adults. It is acute syndrome associated with thrombi composed of platelets in multiple organ system⁴. The precipitating or causative factors implicated include pregnancy, surgery, antibiotics, OCP, abortions⁵.

Following the discovery that TTP is associated with a severe deficiency of ADAM TS 13 activity, it was

suggested that ADAM TS 13 deficiency may become the definitive and diagnostic criterion for TTP³. But many patients who fulfill the clinical diagnostic criteria for TTP do not have ADAM TS 13 deficiency³. For some authors measurement of ADAM TS 13 activity do not conclusively confirm the diagnosis of TTP, as it may be found decreased in many other acute inflammatory conditions¹. Our patient fulfills the pentad criteria, so we can say that this is a case of TTP. His clinical features and biochemical markers fully support this.

The three types of thrombotic microangiopathy are-TTP, DIC and HUS. The table below will show the differences-

	TTP	HUS	DIC
Thrombocytopenia	+	+	+
Hemolytic anaemia	+	+	+/-
Schistocytes	++	+	+/-
Clinical features	CNS dysfunction, Renal impairment, High fever	Diarrhoea, Renal dysfunction	Features of underlying disease
Laboratory findings	ADAM TS 13 decreased	Shiga toxins-	High FDP
Treatment	Steroid, PE Immunosuppression Anti coagulant	Plasma Exchange	Treatment of underlying disease

From this table it is seen that our patient has all the features of TTP. His FDP and D-dimer levels were raised, but it is reported that this two can be raised in TTP¹.

There are two types of TTP-congenital and acquired. Congenital TTP (Upshaw-Schulman syndrome) is characterized by the absence or severe deficiency of ADAM TS 13 activity by mutation in the ADAM TS 13 gene. Acquired idiopathic TTP without underlying diseases generally has severe deficiency of ADAM TS 13 activity caused by anti ADAM TS 13 auto antibodies. However acquired TTP due to various underlying diseases often does not show a severe deficiency of ADAMTS 13 activity or the presence of ADAM TS 13 inhibitors. TTP without severe ADAM TS 13 deficiency is termed as thrombotic microangiopathy¹. For the purpose of distinguishing TTP from TMA (Thrombotic microangiopathy), Fujimora and Matsumoto categorized TTP using plasma level of ADAM TS 13 activity (<3% severe, 3-25% moderate, 25-50% mild)².

The treatment of TTP is quite difficult. Mortality rate was about 90% before the invention of plasma exchange. Almost 20 years ago plasma exchange was reported to increase survival upto 78% compared to 51% survival for patients treated with plasma infusion alone³. The British Committee for Standards in Hematology recommends that Plasma exchange therapy continues for a minimum of two days after the return of platelet counts to normal, normalization of neurological status, increased hemoglobin and normalization of LDH. The residual presence of schistocytes in the peripheral blood after normalization of platelet count is common and is not predictive of relapse⁶. Corticosteroids again have a role in acquired TTP for inhibition of the antibodies against ADAM TS 13. Rituximab recommended in the treatment of relapsing or refractory forms of TTP (6). In places like our country where plasma exchange is unavailable, high volume plasma infusion (30 ml/kg) may be given.

We treated our patient with corticosteroid, plasma infusion and supportive measures only. At first we

treated him with steroid alone due to diagnostic dilemma. Patients' condition was improved after 10 days. His skin rashes disappeared, fever subsided and renal function was also improved. We started to taper steroid. At that time patient was unable to move his body due to generalized stiffness, for this he developed bed sore. For these ulcers he again developed fever, skin rashes and fluctuating level of consciousness. Now we are treating the patient with plasma infusion and steroids with supportive therapy.

References:

1. Arimoto M, Kmiyama Y, Okomee F, Ichibe A, Teranishi S, Tokunago H, et al. A case of thrombocytopenic purpura induced by acute pancreatitis Dove press, Date- March 2012, Vol: 2012:5, Page 307-311.
2. Yamada R, Nozawa K, Yoshimine T, Takasaki Y, Ogawa H, Takamori K, et al. A case of Thrombotic Thrombocytopenic Purpura associated with Systemic Lupus Erythematosus: Diagnostic Utility of ADAM TS 13 activity Autoimmune diseases, volume 2011, Article 10-483642 (6 pages)
3. Domian JT, Filho S, de Barros PV, Rios AMY, da Silva P, Barbosa FA, et al. Thrombotic Thrombocytopenic Purpura associated with Mixed Connective Tissue Disease: A Case Report. Case reports in medicine, Vol: 2011, Article ID: 953890 (5 pages)
4. See JRH, Sabagh T, Barde CJ. Thrombotic Thrombocytopenic Purpura: A Case Presenting With Acute Ischemic Colitis. Case reports in Hematology (Hindawi Corporation), Volume: 2013, Article ID: 592930, (4 pages)
5. Parikh PM, Chill VS, Mehta BC, Anjaria PD. Thrombotic Thrombocytopenic Purpura (a case report) Journal of post graduate medicine, Year 1987, Vol: 33, Issue-2, page 105-7.
6. Khayat SSE, Medkouri G, Etomba AM, Zamd M, Gharbi MB, Ramadani B. Thrombotic Thrombocytopenic Purpura and Systemic Lupus Erythematosus: a Rare and Life Threatening Association. Arab journal of Nephrology and Transplantation, Date 2012, May, 5(2):103-5.