

ORIGINAL ARTICLES

ENDOSCOPIC RETROGRADE CHOLANGIOPANCREATOGRAPHY FINDINGS DIFFERS FROM ULTRASOUND RESULTS: A STUDY ON CHOLEDOCHOLITHIASIS PATIENTS IN A TERTIARY CARE HOSPITAL OF BANGLADESH

TAREQ MAHMUD BHIUYAN¹, MOUSUMI SANYAL², SABRINA YESMIN S³

Abstract:

Background: Endoscopic retrograde cholangio-pancreatography (ERCP) is a universally established modality in evaluation and treatment of pancreatobiliary disorders. Choledocholithiasis is one of its common indications. In the context of Bangladesh, clinical studies on ERCP, specially, assessment of the role of pre-procedural Ultrasound as a screening tool, is relatively rare. In this work, we have analyzed the ERCP outcome of 95 patients and compared their pre-procedural ultrasound results afterwards.

Methods: This cross-sectional observational study was conducted in the BIRDEM General Hospital during June 2013 to January 2015 on 95 ERCP patients. Among 95 patients, maximum (27.7%) were diagnosed as Choledocholithiasis. The important diagnosis among the rest were, Chronic Calcific Pancreatitis (13.8%), Ca head of Pancreas (12.7%), Cholangiocarcinoma (11.7%), and peri-ampullary carcinoma (11.7%). Ultrasound could not detect common bile duct stone in 42% of choledocholithiasis patients. It detected dilated common bile duct in 30% patients and 15% patients had normal ultrasound report while they underwent ERCP due to high clinical suspicion and found to have duct stone afterwards.

Conclusion: The role of ultrasound as a screening test for choledocholithiasis should be progressively assessed by comparing it with MRCP and ERCP results. This study will encourage further research to find correlation between the ERCP and Imaging (both ultrasound and MRCP) in choledocholithiasis patients.

Key words: ERCP, Ultrasound, Choledocholithiasis, CBD stone.

Received: 03 September 2018

Accepted: 05 November 2018

DOI: <https://doi.org/10.3329/bjmed.v30i1.39916>

Introduction:

Endoscopic Retrograde Cholangiopancreatography (ERCP) was first reported in 1968 and was quickly accepted as a safe, direct technique for evaluating pancreaticobiliary disease¹. Currently ERCP is being used for both diagnostic and therapeutic purposes, such as: 1. Stone disease (Choledocholithiasis, cholangitis, biliary pancreatitis, pancreatic duct stones), 2. Ampullary/papillary abnormalities (Sphincter of Oddi dysfunction, peri-ampullary cancer,

cholangiocarcinoma, etc.), 3. Ampullary/papillary abnormalities (leaks, strictures, malignancies)².

Choledocholithiasis is one of the most common reasons behind undertaking ERCP³. Stones within the common bile duct are sometimes asymptomatic and may be found incidentally. However, more frequently they lead to symptomatic presentation with: biliary colic, ascending cholangitis, obstructive jaundice &/or acute pancreatitis. Although ultrasound is usually the first

1. Professor, Department of Gastroenterology, BIRDEM Medical College Hospital.

2. Medicine Consultant, Better Life Hospital, Rampura, Dhaka.

3. Associate Professor, Medicine Department, Dr. Sirajul Islam Medical College Hospital.

Corresponding author: Mousumi Sanyal, Medicine Consultant, Better Life Hospital, Rampura, Dhaka. email-mousumi_sanyal85@yahoo.com

investigation for biliary disease, it has average sensitivity for the detection of biliary stones within the bile duct, sensitivity has been variably reported between 13-55%⁴. Such a broad range of sensitivity is probably related to patient selection and number, equipment used and experience of the operator. Another important limiting factor is overlying bowel gas which impair visualization of the lower part of the common bile duct⁵. Magnetic resonance cholangiopancreatography (MRCP) and ERCP has largely replaced ultrasound as the gold standard for diagnosis of choledocholithiasis. Currently ERCP is becoming more popular because of its therapeutic role. In highly suspicious cases, ERCP can remove the stone as well as detecting the disease, although the sensitivity and specificity of ERCP for detecting common bile duct stones are more than 95%, small stones may be missed⁶. However, still physicians, especially in the settings of low income countries, prefer ultrasound because of availability and low cost.

This observational study has been designed to assess our experience in the use of ultrasound for the successful diagnosis of choledocholithiasis. Here the ultrasound results of ERCP proven Choledocholithiasis patients have been compared with the ERCP findings. This work will help to establish the sensitivity of ultrasound of hepato-biliary system in suspected Choledocholithiasis cases.

Materials & Methods:

This cross-sectional observational study was performed on 95 patients in the BIRDEM General Hospital from June 2013 to January 2015. The patients presented with the clinical presentation suggestive of pancreatico-biliary disease were included in the study. They were advised for complete blood count, random blood sugar, liver function test, coagulation profile and Ultrasound of Hepatobiliary system. Patients with high clinical suspicion of pancreatico-biliary disease with suggestive biochemical markers and evidence of imaging were selected for ERCP. The inclusion criteria were: a. age above 18 years, b. conscious and oriented, c. presented with abdominal pain, vomiting, itching, jaundice, fever, anorexia and weight loss, d. high Alkaline phosphatase (twice above the normal limit; >300 IU/L). The exclusion criteria are: a. non cooperative patient, b. any severe co morbidity, c. coagulopathy (Abnormal Platelet count, prothrombin time and APTT).

ERCP was performed by the Olympus 160 series with Allenger Fluoroscope. The procedure was performed under general anesthesia. The standard protocol was followed for pre and post procedural measures. After the procedure, all the results were input in SPSS 16 and were analyzed by the same software.

Those patients were confirmed to have choledocholithiasis by ERCP, their ultrasound findings were retrospectively reviewed and compared.

Results

Among 95 patients, 27.7% (n=26) patients had Choledocholithiasis and the rest 72.3% (n=69) patients had other diagnosis (Table 1). The other important diagnosis were: Chronic Calcific Pancreatitis(13.8%), Cholangiocarcinoma(11.7%), Cancer of Head of Pancreas(12.7%) and Peri-ampullary Carcinoma (11.7%).

Table-I

ERCP outcome with percentage performed in BIRDEM Hospital

Diagnosis	No of Patients	Percentage
Choledocholithiasis	26	27.7
Benign Papillary Stenosis	9	9.6
Biliary Ascariasis	3	3.8
Chronic calcific Pancreatitis	13	13.8
Cholangiocarcinoma	11	11.7
Carcinoma of Head of Pancreas	12	2.7
Periampullary carcinoma	11	10.0
Ca Gall bladder	5	5.4
Blocked Stent	2	2.12
Stricture CBD	2	2.12
Others	1	1.06

The mean age of the study population was 55 years. Male and female ratio was equal. The clinical presentation were mainly abdominal pain, jaundice, vomiting, itching, anorexia, weight loss and fever (figure 1). Abdominal pain and jaundice were the commonest presentation among both the groups (Ultrasound proven and non-proven CBD stone patients). Among the total study population, 58% of Choledocholithiasis patients were diabetic and 37% of the patients with other diagnosis were diabetic.

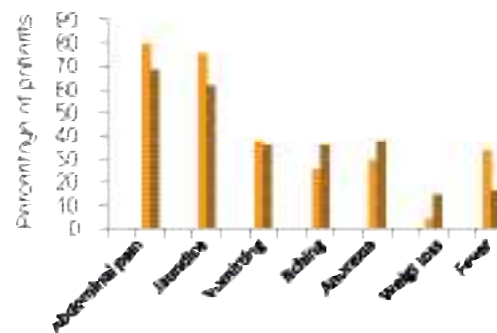
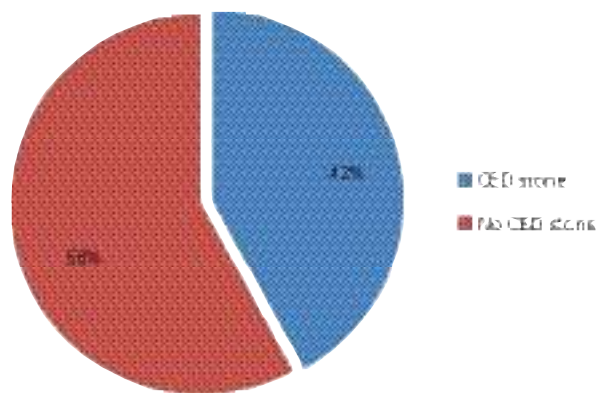


Fig.-1: Clinical presentation of the study population

Table-II*Investigation findings of the Choledocholithiasis patients who does not have CBD stone in ultrasound*

Criteria	Patient 1	Patient 2	Patient 3	Patient 4	Patient 5	Patient 6	Patient 7	Patient 8	Patient 9	Patient 10	Patient 11
Bilirubin	13.6	1.8	2.6	7	3.4	1.4	2.4	3.6	5.7	7.5	3.7
ALP	347	543	391	445	552	593	375	328	870	308	297
USG CBD dilated	YES	YES	NO	NO	NO	YES	YES	YES	YES	YES	NO

**Fig-2:** Presence of CBD Stone in ultrasound of the ERCP proven choledocholithiasis patients

Ultrasound could not detect common bile duct stone in 42% of choledocholithiasis patients (figure 2). But, their clinical presentation was highly suggestive and they had high Alkaline phosphatase (table 2). Common bile duct was dilated in 30% choledocholithiasis patients and Ultrasound was normal in 15% patients while they were diagnosed to have duct stone later with the means of ERCP.

Discussion:

In patients with suspected choledocholithiasis, ERCP has been the gold standard for the diagnosis and treatment in the past decades. The problem of ERCP is that it is a potentially invasive procedure with several complications such as; post-ERCP pancreatitis, cholangitis, bleeding, and bowel perforation. Therefore, confirming the presence of choledocholithiasis, preferably with imaging (ultrasound or MRCP) before performing ERCP is frequently desirable. The reason this is important is that the risk-producing problems related to an unnecessary diagnostic ERCP increase if the patient does not have stones, while ERCP is beneficial for patients with bile duct stones. However, consensus about the optimal noninvasive diagnostic method for patients with suspected choledocholithiasis is lacking⁷.

Among the 95 patients underwent ERCP due to suspicious pancreatico-biliary disease, there were varieties of diagnosis. Table 1 shows the wide varieties

of diagnosis found after ERCP. Here the maximum 27.7% of patients were diagnosed as choledocholithiasis. The clinical data on ERCP outcome, in the field of Bangladesh, is limited⁸. Thus, this work will help the researchers to get an idea about the common indications of ERCP in a tertiary care hospital.

Yousuf et al, in their article, described the broad spectrum of clinical presentation of ERCP patients⁸. Similar to our study, abdominal pain and jaundice were the commonest presentation. The only difference is that, we had significant number of population had weight loss, which was might be due to underlying malignancy or chronic pancreatitis.

During analysis of the background of these patients, we found that, 58% of CBD stone patients were diabetic and 37% of the patients with other diagnosis were diabetic. We understand that the study was performed in BIRDEM Hospital which basically deals with diabetic patient. But in that background, we expect to get a high percentage of diabetic patients equally in both groups. Interestingly, it was only high in patients with Choledocholithiasis. Ikrad mentioned in his article that, so far there is no established link between diabetes mellitus and development of gall stone⁹. However our recommendation will point toward more study to find any correlation between choledocholithiasis (as well as gall stone) and Diabetes. Precisely it is an issue of discussion whether the Diabetic population are more prone to develop Choledocholithiasis or Diabetes can occur as a complication of Choledocholithiasis.

The most important information came out during analysis of the investigation results. Still in our country, Ultrasound usually stands as the first line investigation for suspected choledocholithiasis patients. However, Chronan JJ et al described in his article, it has average sensitivity for the detection of biliary stones within the bile duct between 13-55%¹⁰. Among ERCP proven Choledocholithiasis patients, only 58% patients had USG reported stone in CBD. The rest 42% did not have any CBD stone in the Common bile duct. Now, analyzing the information of ultrasound negative group, the next question was, what were the information,

which led them to diagnostic ERCP? There are few clinical and biochemical parameters of choledocholithiasis which points towards its strong suspicion. One study categorized the likelihood of having ongoing choledocholithiasis as “moderate,” “strong” or “very strong.” Those included in the “very strong” category included visualized choledocholithiasis on trans-abdominal ultrasound, clinical cholangitis, and a total bilirubin >4 mg/dL. “Strong” indicators included a dilated common bile duct (CBD) > 6 mm and total bilirubin between 1.8-4 mg/dL. “Moderate” indicators included abnormal liver tests, age>55, and clinical gallstone pancreatitis¹¹. It is clear from the table 2 that all these patients had high bilirubin with clinical features of biliary disease. But ultrasound detected dilated bile duct in 7 of them.

And the rest had normal Ultrasonogram. This population consists of 15% of CBD stone. So, our study reveals that around 15% patients with choledocholithiasis did not show any significant findings in the Ultrasonogram. But on the ground of clinical and biochemical suspicion, the diagnostic ERCP was performed and found to have stone in CBD.

The criticism to our study that the population was relatively small and MRCP facilities were not available. Despite the apparent insensitivity of ultrasound to detect common duct stones, the modality is still a valuable non-invasive screening diagnostic tool, because in positive cases, patients may be spared from invasive cholangiographic procedures. However, this study will encourage the physicians to perform a larger study to evaluate the sensitivity of Ultrasound as a screening tool for Choledocholithiasis and compare it with ERCP outcome.

References:

1. McCune WS, Shorb PE, Moscovitz H. Endoscopic cannulation of the ampulla of Vater: a preliminary report. *Ann Surg.* 1968 May;167(5):752-6.
2. Kim J., Carr-Locke D. (2015) Indications for ERCP. In: Lee L. (eds) ERCP and EUS. Springer, New York, NY. DOI 10.1007/978-1-4939-2320-5_2.
3. Fernández-Esparrach G, Ginès A, Sánchez M, Pagés M, Pellisé M, Fernández-Cruz L. Comparison of endoscopic ultrasonography and magnetic resonance cholangiopancreatography in the diagnosis of pancreatobiliary diseases: a prospective study. *Am J Gastroenterol.* 2007;102:1632-9.
4. Hartung M, Gaillard F. Choledocholithiasis. *Radiopaedia Online Journal.* rid 8059. Available at <https://radiopaedia.org/articles/choledocholithiasis> (Last viewed on December 2018).
5. Sakijan AS, Atannih M. Choledocholithiasis: Diagnosis by Ultrasound. *Med. J. Malaysia.* 1987 June; 42(2):115-118.
6. NIH state-of-the-science statement on endoscopic retrograde cholangiopancreatography (ERCP) for diagnosis and therapy. *NIH Consens State Sci Statements* 2002;19:1-26. PMID: 14768653.
7. Lee TY. Optimal Evaluation of Suspected Choledocholithiasis: Does This Patient Really Have Choledocholithiasis? *Journal of Clinical Endoscopy.* 2017 Sep; 50(5): 415-416. PMID: 29017296.
8. Yousuf M, Hasan M, Saha SS, Ali SMA, Boksha S, Hossain M. Diagnostic Yields of ERCP: First Study of Previously Unexamined Population of Southeastern Part of Bangladesh. *Chattagram Maa-O-Shishu Hospital Medical College Journal.* 2013 January;12(1):1-3.
9. Ikard RW. Gallstones, cholecystitis and diabetes. *Surg Gynecol Obstet.* 1990 Dec;171(6):528-32. PMID: 2244290.
10. Cronan JJ. US diagnosis of choledocholithiasis: a reappraisal. *Radiology.* 1986 Oct;161(1):133-4.
11. Balmadrid B, Kozarek R. Prevention and management of adverse events of endoscopic retrograde cholangiopancreatography. *Gastrointest Endosc Clin N Am.* 2013;23(2):385-403.
12. Pan S, Guo Q. Endoscopic ultrasonography versus magnetic resonance cholangiopancreatography for suspected choledocholithiasis: Comments from the radiologists'. *Endosc Ultrasound.* 2016 Mar-Apr; 5(2):129-31.