

# EOSINOPHILIC ENTEROCOLITIS: A RARE NOSOLOGICAL ENTITY

K.KRATI<sup>1</sup>, Y.LEMFADLI<sup>1</sup>, I.BOUJGUENNA<sup>2</sup>, H.RAIS<sup>2</sup>

## Abstract

*Eosinophilic enterocolitis is an exceptionally rare disease with few cases described in the literature. It is the least frequent manifestation of the broad spectrum of gastrointestinal eosinophilic diseases. We describe a case of a female patient presenting with a form of the disease manifested by Koenig's syndrome and diarrhea. This posed a diagnostic challenge for us due to its non-specific symptoms, associated with the absence of standardized histological criteria, hence the need for a high level of suspicion. There is also no consensus regarding the treatment. It should be individualized according to the age of the patient and the severity of symptoms.*

**Keywords:** Eosinophilic enteritis, eosinophilic colitis, hyper-eosinophilia

Received: 09 October, 2020

Accepted: 25 December, 2020

DOI: <https://doi.org/10.3329/bjm.v32i1.51098>

## Introduction:

Eosinophilic enterocolitis is the least common subgroup of the broad spectrum of primary eosinophilic gastrointestinal disorders which can be subdivided into eosinophilic esophagitis, eosinophilic gastritis, eosinophilic enteritis, and eosinophilic colitis.<sup>1</sup> Since the small intestine is not frequently biopsied, there is little evidence related to eosinophilic enteritis.<sup>2</sup> Since 1979, only a few cases of eosinophilic colitis have been reported [2]. Its exact prevalence remains unknown, with a peak of prevalence in newborns and young adults and without any gender preference.<sup>2</sup> In this article, we present the case of eosinophilic enterocolitis in a 45-year-old woman and we discuss in the light of the data of the literature the diagnostic and therapeutic dilemma of this nosological entity.

## Case report:

We report the case of a 45-year-old woman with a history of three miscarriages and one stillbirth. She was admitted with a 3 month history of intermittent watery diarrhea at a rate of 4 to 5 stools per day, without mucus or blood, associated with Koenig syndrome in the right iliac fossa. She reported a profound deterioration in general condition with weight loss of 10 kg over 3 months. Symptoms worsened a week before admission with the onset of edema in the

lower limbs. She had no fever or other associated symptoms.

The patient had no history of atopic disease, no known food or drug allergy, and no recent travel abroad.

On physical examination, she was non-feverish with normal vital signs. She was malnourished and dehydrated with cleft muscle and fat pannicle. The edema of the lower extremities was soft white on the scoop with an absence of protein in the urine strips. Examination of the abdomen revealed abdominal tenderness of the right iliac fossa without defense or contracture and no other associated signs.

A complete blood count showed hyperleukocytosis (24,000 / mm<sup>3</sup>) and eosinophilia (13,496 / mm<sup>3</sup>), microcytic hypochromic anemia at 8.9 g / dL with ferritinemia at 51 ng/ml. There was an increase in C-reactive protein (29 mg / l) and hypoalbuminemia (14.9 g / l). The other laboratory results are defined in Table 1.

Copro-parasitological examination of the stool did not isolate pathogens. The serum immunoglobulin E assay was normal at 31 KU / l (N <150KU / l) and HIV serology was negative. The myelogram was without abnormalities.

---

1. Department of Gastroenterology, Mohamed VI University Hospital Center, Marrakech, Morocco

2. Department of Pathology, Mohamed VI University Hospital Center, Marrakech, Morocco

**Address of Correspondence:** Dr. Dr. K. Krati, Department of Gastroenterology, Mohamed VI University Hospital Center, Marrakech, Morocco

**Table-I***Biochemical and hematological parameters*

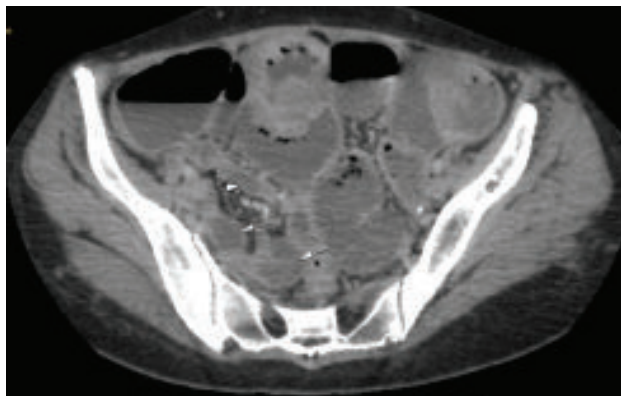
Parameters	Results
Hemoglobin	8,9 (g/dL)
MCV	71 ( $\mu^3$ )
MCHC	24 (pg)
Hematocrit	27 (%)
Leukocytes	24100 (/mm <sup>3</sup> )
Polynuclear neutrophils	5543 (/mm <sup>3</sup> )
Polynuclear eosinophils	13496 (/mm <sup>3</sup> )
Polynuclear basophils	0 (/mm <sup>3</sup> )
Lymphocytes	4097(/mm <sup>3</sup> )
Monocytes	964 (/mm <sup>3</sup> )
Platelets	601000 (/mm <sup>3</sup> )
Prothrombin	100 (%)
C reactive protein	29 (mg/L)
Natremia	128 (mmol/L)
Kalemia	4 (mmol/L)
Calcemia	70 (mmol/L)
phosphoremia	35 (mmol/L)
Albumin	14,9 (g/L)
Ferritinemia	46.8 (ng/mL)
Total cholesterol	0,56 (g/L)
Urea	0,16 (g/L)
Creatinine	2 (mg/L)
24 hour proteinuria	0.35(g/L)
Ig E	31 (KU/l)

At this stage an infectious attack was initially suspected without being able to rule out an inflammatory or tumor attack.

Due to concern for parasitic infection, the patient was placed on intravenous metronidazole.

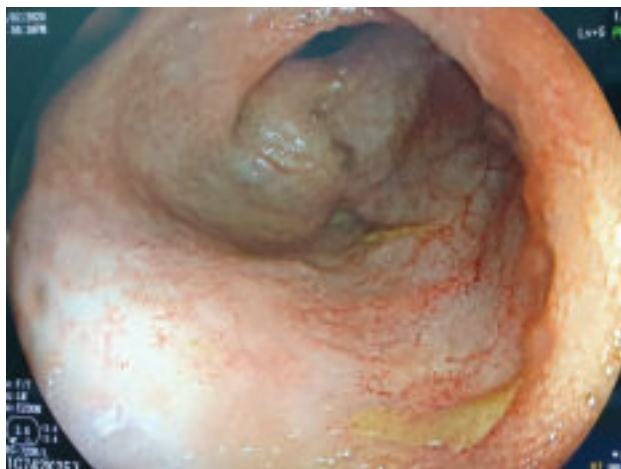
The abdominal ultrasound did not show any abnormalities apart from two small ovarian cysts.

Complement by a CT enteric scan revealed wall thickening of a few ileal loops in the hypogastric region, in the left iliac fossa and in the pelvic floor, measuring 15 mm, 17 mm and 12 mm respectively, stenosing with upstream stasis. It presents a target enhancement by the contrast product with submucosal edema. There was no significant deep lymphadenopathy (Figure 1).



**Fig.-1:** CT scan showing wall thickening of the ileal loops with upstream stasis

Colonoscopy was without major macroscopic abnormalities apart from erythema in the terminal ileum and colon (Figure 2). Biopsies of the terminal ileum and all segments of the colonic mucosa were taken.

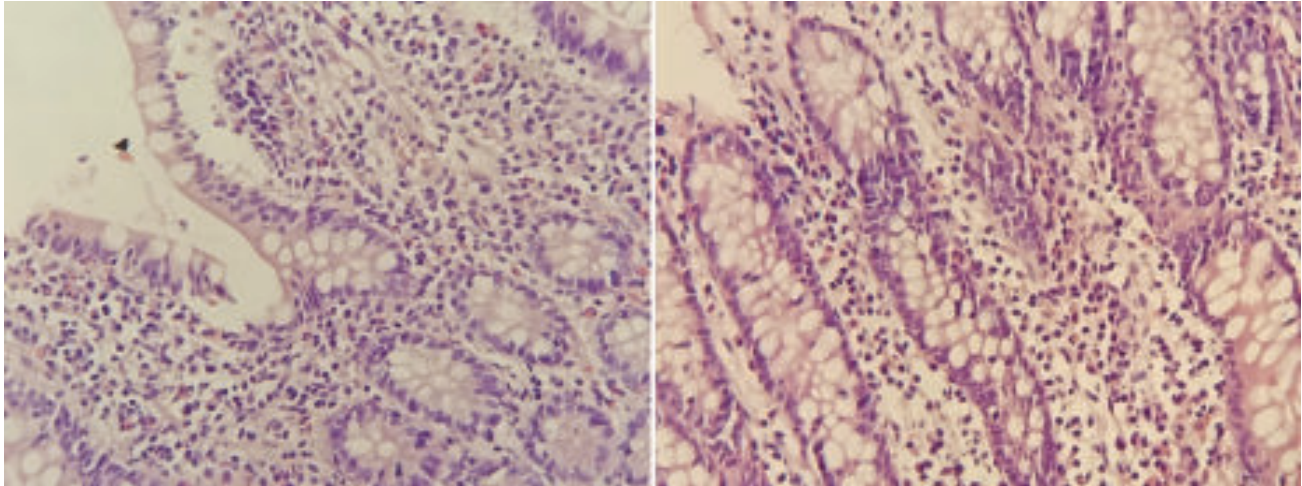


**Fig.-2:** Erythematous ileal mucosa

The anatomopathological study revealed an inflammatory infiltration of the ileal mucosa by lymphocytes, plasma cells and eosinophils, estimated at 29 eosinophils per field at high magnification x2, with the presence of regular lymphoid follicles, compatible with eosinophilic enterocolitis (Figure 3).

Based on the histopathologic findings, serum eosinophilia and the absence of secondary causes of intestinal eosinophilia, the diagnosis of eosinophilic enterocolitis was made.

Our patient began treatment with intravenous prednisone at 1 mg / kg / day for 7 days and then took over orally. The ionic disturbances and hypoalbuminaemia were corrected parenterally. The



**Figure 3:** Eosinophilic infiltration of the ileal mucosa (left) and colic (right)

course at week 1 and week 2 was marked by clinical improvement in symptoms, despite persistence of peripheral eosinophilia. She was educated on a 6 food elimination diet avoiding peanuts, milk, eggs, soybeans, wheat, and fish. By week three, she no longer showed up for her check-up appointment.

### Discussion

Eosinophilic enterocolitis is a disease entity linked to abnormal infiltration of the intestinal mucosa by polynuclear eosinophils. It is a rare entity on the spectrum of gastrointestinal eosinophilic disorders.<sup>3</sup> Gastroenteritis and eosinophilic colitis represent an estimated incidence of 22 to 28 cases / 100,000 in the United States.<sup>4</sup>

The pathogenesis of eosinophilic gastrointestinal disorders is not well understood. They probably result from a complex interaction between environment, genetics and immunological factors.<sup>5</sup> Several epidemiological studies suggest an allergic component, in particular food allergies, which elicits a Th2-type immune response leading to the production of cytokines, such as interleukins, IL-4, IL-5, IL-13 and eotaxins-3. This results in intestinal eosinophilia, which further causes local inflammation by releasing toxic cationic proteins.<sup>6</sup> Even less is known about the etiology of primary eosinophilic colitis. It is associated with food allergies and atopy in several cases described.<sup>1</sup> It can probably be both an IgE and non-IgE mediated disease.<sup>7</sup>

Klein et al.<sup>8</sup> proposed a classification system based on the depth of parietal infiltration. Mucosal infiltration is the most common type and is characterized by eosinophilic infiltration of the mucosa and sub-mucous membrane. Muscle type is characterized by muscle involvement. The serous type affects all layers

and is considered the rarest type.<sup>9</sup> The mucosal type is associated with persistent chronic symptoms and can lead to enteropathy with loss of protein.<sup>10</sup>

The diagnosis of eosinophilic enterocolitis is an exclusion diagnosis that requires a high level of suspicion. It is based on the association of non-specific gastrointestinal symptoms, the demonstration of an eosinophilic infiltration on the biopsies, and the exclusion of secondary causes of eosinophilic infiltration such as parasitoses, drugs, chronic inflammatory bowel disease, malignant causes, autoimmune damage and eosinophilic syndrome<sup>7,11</sup>. There are no standardized histological criteria to make the diagnosis<sup>2</sup>. Peripheral eosinophilia can be observed, but may be absent in 20% of patients. Sectional imaging results are non-specific and may show thickening of the intestinal wall and ascites in some cases.<sup>12</sup>

The treatment of eosinophilic enterocolitis remains a challenge in the absence of specific recommendations as there are no controlled trials to date on a specific treatment.<sup>9</sup> So far, the treatment of eosinophilic enterocolitis has been empirical and based on the severity of clinical manifestations, as well as the experience of clinicians. Patients with mild disease can be treated symptomatically, while more symptomatic patients and those with signs of malabsorption need more aggressive treatment.<sup>13</sup>

A high proportion of cases of eosinophilic gastroenteritis are associated with food allergy. Therefore, diet therapy may improve symptoms.<sup>12</sup> It involves a “six-food elimination diet,” avoiding milk, soy, eggs, wheat, peanuts / tree nuts, and shellfish / fish. The main limitation of diet therapy is patient compliance.

Corticosteroids are the optimal therapy for the induction of remission. Oral prednisone is the most common therapy, with an initial dose of 0.5-1 mg / kg and decreased over a period of 6-8 weeks. Relapses can occur and require low maintenance doses (1 to 10 mg / day) of prednisolone [14] or the substitution of prednisolone by budesonide which has a better safety profile<sup>15,16</sup>.

Other therapies targeting immune modulation have been described in reports, and small case series, will likely be useful in treating recurrent or refractory symptoms. They include mast cell inhibitors such as cromolyn, ketotifen, leukotriene receptor antagonists, anti-IL-5 antibodies, omalizumab, and anti IgE monoclonal antibodies.<sup>13</sup>

### Conclusion

Our clinical case highlights a rare entity that is often underdiagnosed. Further studies are needed to better define diagnostic criteria for this entity. Randomized controlled trials are also needed to establish a standardized treatment approach.

### References:

1. Alfadda AA, Storr MA, Shaffer EA: Eosino-philic colitis: epidemiology, clinical features, and current management. *Therap Adv Gas-troenterol* 2011; 4: 301-309. <https://doi.org/10.1177/1756283X10392443> PMID:21922029 PMCID:PMC3165205
2. Bates AWH: Diagnosing eosinophilic colitis: histopathological pattern or nosological en-tity? *Scientifica (Cairo)* 2012; 2012: 1-9. <https://doi.org/10.6064/2012/682576> PMID:24278727 PMCID:PMC3820477
3. Gilles Macaigne. Colites à éosinophiles de l'adulte. *Hépatogastro & Oncologie Digestive*. 2018;25(8):792-802. doi:10.1684/hpg.2018.1659
4. Spergel JM, Book WM, Mays E, et al. Variation in prevalence, diagnostic criteria, and initial management options for eosinophilic gastrointestinal diseases in the United States. *J Pediatr Gastroenterol Nutr*. 2011 Mar;52(3):300-6. <https://doi.org/10.1097/MPG.0b013e3181eb5a9f> PMID:21057327 PMCID:PMC4450826
5. Lopes Azevedo R, Pinto J, Ribeiro H et al : Eosinophilic Enterocolitis: An Exceedingly Rare Entity. *GE Port J Gastroenterol* 2018;25:184-188.<https://doi.org/10.1159/000481915> PMID:29998164 PMCID:PMC6029222
6. Elena Thampy Cherian, Hao Chi Zhang, Katie B. Guttenberg, Jamie M. Everett, Sushovan Guha, Looking Beyond the Obvious: Eosinophilic Enterocolitis, *The American Journal of Medicine* (2018). <https://doi.org/10.1016/j.amjmed.2018.02.008> PMID:29526542
7. Alfadda AA, Storr MA, Shaffer EA: Eosino-philic colitis: an update on pathophysiology and treatment. *Br Med Bull* 2011; 100: 59-72. <https://doi.org/10.1093/bmb/ldr045> PMID:22012125
8. Klein NC, Hargrove RL, Slesinger MH, Jeffries GH. Eosinophilic gastroenteritis. *Medicine (Baltimore)*. 1970 Jul;49(4):299-319 <https://doi.org/10.1097/00005792-197007000-00003> PMID:5426746
9. Uppal V, Kreiger P, Kutsch E: Eosinophilic gastroenteritis and colitis: a comprehensive review. *Clin Rev Allergy Immunol* 2016; 50: 175-188. <https://doi.org/10.1007/s12016-015-8489-4>. PMID:26054822
10. Pineton de Chambrun G, Gonzalez F, Canva JY, Gonzalez S, Houssin L, Desreumaux P, Cortot A, Colombel JF. Natural history of eosinophilic gastroenteritis. *Clin Gastroenterol Hepatol*. 2011 Nov;9(11):950-956 <https://doi.org/10.1016/j.cgh.2011.07.017> PMID:21806952
11. Samiullah, Bhurgri H, Sohail U: Eosinophilic disorders of the gastrointestinal tract. *Prim Care* 2016; 43: 495-504. <https://doi.org/10.1016/j.pop.2016.04.003> PMID:27545738
12. Zhang M, Li Y: Eosinophilic gastroenteritis: a state-of-the-art review. *J Gastroenterol Hepatol* 2017; 32: 64-72. <https://doi.org/10.1111/jgh.13463> PMID:27253425
13. Sunkara T, Rawla P, Yarlagadda KS, Gaduputi V. Eosinophilic gastroenteritis: diagnosis and clinical perspectives. *Clin Exp Gastroenterol*. 2019;12:239-253 <https://doi.org/10.2147/CEG.S173130> PMID:31239747 PMCID:PMC6556468
14. Wong GW, Lim KH, Wan WK, Low SC, Kong SC. Eosinophilic gastroenteritis: clinical profiles and treatment outcomes, a retrospective study of 18 adult patients in a Singapore Tertiary Hospital. *Med J Malaysia*. 2015;70(4):232-237.
15. Busoni VB, Lifschitz C, Christiansen S, GdD MT, Orsi M. [Eosinophilic gastroenteropathy: a pediatric series]. *Arch Argent Pediatr*. 2011;109(1):68-73.
16. Lombardi C, Salmi A, Passalacqua G. An adult case of eosinophilic pyloric stenosis maintained on remission with oral budesonide. *Eur Ann Allergy Clin Immunol*. 2011;43(1):29-30.