

## CASE REPORT

# ATYPICAL PRESENTATION OF COLONIC DIVERTICULAR DISEASE

REFAYA TASNIM<sup>1</sup>, NAWSABAH NOOR<sup>2</sup>, QUAZI TARIKUL ISLAM<sup>3</sup>

### Abstract:

*Hematochezia or passage of fresh blood per rectum is a relatively common finding in medical practice which mostly indicates lower gastrointestinal bleeding. The causes for lower gastrointestinal bleeding include diverticular disease, vascular ectasia, ischemic, inflammatory or infectious colitis, colonic neoplasia, hemorrhoids, anal fissures and small bowel lesions (Crohn's disease, Vascularectasia, Meckel's diverticulum). If a patient comes with severe hematochezia, the first and foremost task is to stabilize the patient and then find out the source of bleeding as soon as possible. Elderly patients presenting with severe hematochezia, is most likely due to colorectal malignancy but benign causes like colonic diverticulosis can also present as life threatening bleeding in rare occasions. Here we report a case of 70-years-old male patient presenting with severe painless hematochezia leading to severe anemia due to diverticulosis.*

**Keywords:** Diverticulosis, Hematochezia

Received: 20.10.2021

Accepted: 09.11.2021

DOI: <https://doi.org/10.3329/bjm.v33i1.56797>

**Citation:** Tasnim R, Noor N, Islam QT. Atypical Presentation of Colonic Diverticular Disease.. *Bangladesh J Medicine* 2022; 33: 94-98.

### Introduction:

Lower gastrointestinal bleeding is the hemorrhage from the source distal to the ligament of Treitz, is a common emergency in gastroenterology, with an estimated incidence of 33/100,000.<sup>1</sup> The cause can be differentiated by different age groups. Most commonly, in premature infant group: necrotizing enterocolitis; adolescents and young adult group: inflammatory bowel disease; in middle age to elderly group: colorectal carcinoma, diverticulosis, rarely upper GI massive bleeding can cause hematochezia. Anal fissure and hemorrhoids can occur in all age groups from adolescent to elderly.<sup>2</sup> Diverticular bleeding is reported to account for about 35% of painless lower gastrointestinal bleeding and occurs in up to 50% of elderly patients with diverticulosis.<sup>3</sup> The exact incidence is difficult to estimate, however.

Diverticula means the mucosal herniation of the colonic wall & it is the most common acquired morphological disorder of the large intestine mostly in the sigmoid colon and descending colon<sup>4</sup>. Diverticular disease (DD) is more prevalent in western countries but in Asia, diverticulosis is almost rare, though the prevalence has been increased recently along with the overall increase in prevalence throughout the world.<sup>5</sup>

The current accepted causes of diverticula formation are the transmission of muscular contraction pressure to the wall of the colon, inducing the formation of diverticula usually at the weakest point of the wall where penetration of the blood vessels occurs. It is also considered as a multifactorial disease. The multifactorial causes include genetics, environmental factors, behavioral factors as alcohol,

1. Assistant Registrar, Department of Medicine, Popular Medical College & Hospital, Dhaka, Bangladesh.

2. Registrar, Department of medicine, Popular medical college & hospital, Dhaka, Bangladesh.

3. Professor of Medicine, Popular medical college & hospital, Dhaka, Bangladesh.

**Address of Correspondence:** Dr. Refaya Tasnim, Assistant Registrar, Department of Medicine, Popular Medical College & Hospital, Dhaka, Bangladesh. Email: [refaya.tasnim@gmail.com](mailto:refaya.tasnim@gmail.com)

**Copyright:** @2021 Associations of Physicians of Bangladesh

smoking and low fiber-high fat diet which precipitates abnormal colonic wall motility.<sup>6</sup> Increasing age, male gender, obesity and hypothyroidism all increases the risk, whereas, diabetes mellitus reduces the risk of colonic diverticulosis.<sup>7</sup> With changes in dietary habits and the aging of society, the incidence of colonic diverticulosis is expected to increase.

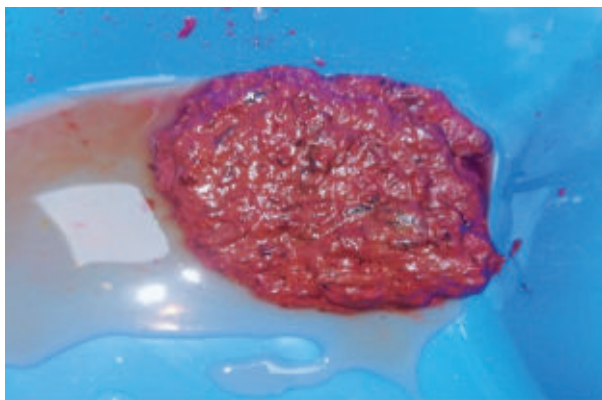
What may be the causative factor, over 50% cases of diverticular disease are asymptomatic. Although colonic diverticulosis is usually asymptomatic, diverticulitis and diverticular bleeding can occasionally occur. In particular, colonic diverticular bleeding causes sudden, painless hematochezia, and with massive bleeding, becomes a condition with high morbidity and mortality rates, in which blood transfusion and urgent treatment are required.<sup>8</sup>

Diverticular bleeding is arterial and occurs from rupture of the intramural branches of the marginal artery at the dome or neck of the diverticulum. Trauma from mechanical or chemical causes within the lumen of the diverticulum leads to injury to the penetrating vessels and bleeding.<sup>9</sup>

Complicated diverticulosis often mimics the presentation of colorectal cancer, ischemic colitis, IBD and infection.<sup>10</sup> When an elderly patient presents with severe hematochezia, this clinical presentation may initially direct towards colorectal malignancy, but complicated diverticulosis needs to be kept in mind as an important differential, although it is quite uncommon in this sub-continent.

#### Case presentation:

On 11<sup>th</sup> October, 2021, a 70-year-old male patient with multiple comorbidities such as hypertension, diabetes mellitus, seronegative RA was admitted in Popular medical college and hospital, Dhaka with the complaints of diarrhea with painless severe hematochezia in a frequency of 6-7 times per day for 5 days (Figure 1). He also complained of generalized weakness up to the point where he couldn't even



**Fig.-1:** Stool sample

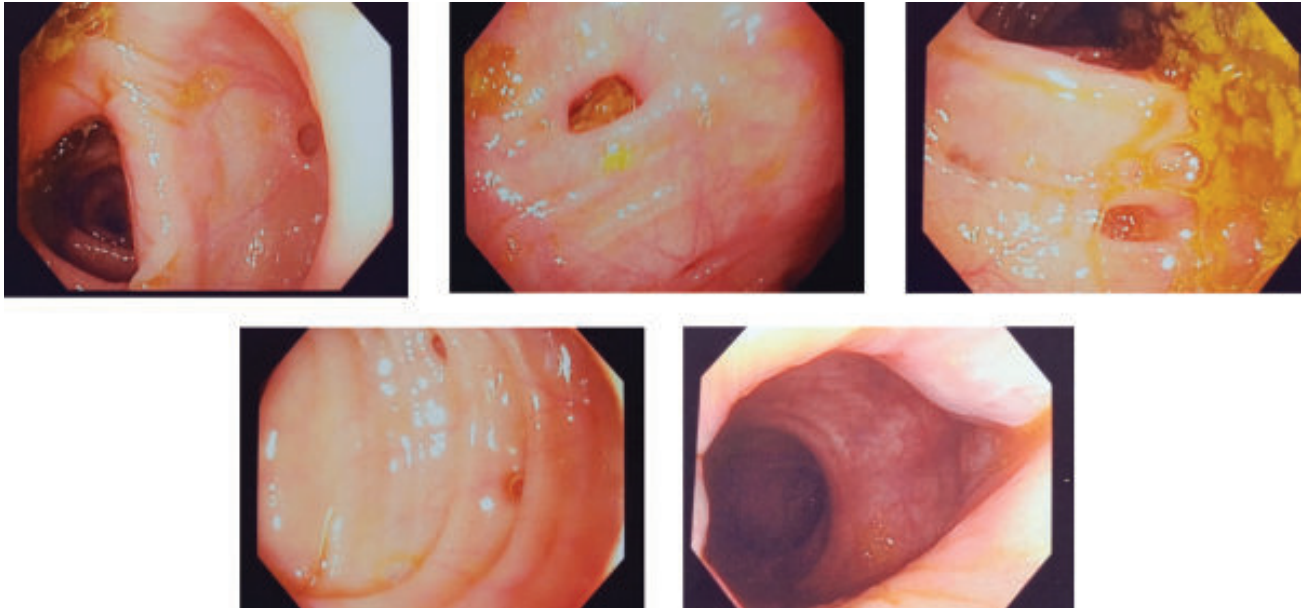
walk or sit by himself without any aid. He gave no history of fever, chest pain, shortness of breath, abdominal pain, anorexia or unintentional weight loss. On query, he complained about constipation for the last 2 years. His regular diet mostly includes white rice, fresh vegetables, potatoes, eggs, chicken, processed flour, sugar and dairy products; occasionally red meat. He did not have any similar episodes before. He is non-smoker & non-alcoholic. His diabetes mellitus, hypertension & seronegative RA were maintained with oral medications.

On admission, his BP was 90/70 mmHg, pulse: 106bpm, temperature: 98.4°F. He had BMI of 29 kg/m<sup>2</sup>. General examination showed the patient was severely anemic, moderately dehydrated, non-edematous, his JVP was not raised. On systemic examination, abdomen was soft, non-tender, no organomegaly was present. Cardiovascular & respiratory system examinations revealed no abnormalities, there was no sign of anemic heart failure. DRE and proctoscopy examination showed non-active second-degree hemorrhoids located at 7 & 11 O'clock position with presence of fresh blood on rectum.

After admission, his lab reports were as follows, Full blood count: Hemoglobin: 3.70 g/dL, HCT: 11.30%, MCV: 100.9 fl, MCH: 33 pg, MCHC: 32.7 g/dL, RDW: 15.8%, Total WBC count: 8.72 K/ $\mu$ L, Neutrophil: 77%, Lymphocyte: 15%, Platelet count: 245 K/ $\mu$ L, ESR: 121 mm in 1<sup>st</sup> hour. Stool R/E revealed RBC: plenty, Mucus: +, no ova, larva or protozoa present. Stool for C/S showed no growth. S. creatinine was 1.74 mg/dL and S. electrolytes, Urine R/E & LFT were within normal limit, ECG showed regular sinus tachycardia.

2 units of packed cell volume were given on emergency basis with subsequent another 3 units of packed cell volume for 3 subsequent days to stabilize the patient first. During the first week of hospital stay, his diarrhea gradually improved but painless severe hematochezia persisted initially despite medical treatment. Bleeding gradually stopped from 6/7<sup>th</sup> day. After the end of first week, his full blood count was repeated which showed, Hemoglobin: 10 g/dL, HCT: 31.10%, MCV: 88.1 fl, MCH: 28.3 pg, MCHC: 32.2 g/dL, RDW: 18.2%, Total WBC count: 5.46 K/ $\mu$ L, Neutrophil: 80%, Lymphocyte: 10%, Platelet count: 180 K/ $\mu$ L, ESR: 74 mm in 1<sup>st</sup> hour.

Considering the risk of perforation; full video colonoscopy was delayed until the end of first week of hospitalization, when the patient was finally hemodynamically stable. Colonoscopy reported as Diverticulosis coli with second-degree hemorrhoids with no SRH (Figure 2).



**Fig.-2:** Colonoscopy images: (A, B, C, D): Numerous diverticula in ascending colon, transverse colon and sigmoid colon. No stigmata of recent hemorrhage.(E): Second-degree hemorrhoids.

As this was his first episode of bleeding and ceased spontaneously, also, there was no SRH on colonoscopy, no therapeutic intervention was needed. And this patient had been discharged with dietary advice & diet chart regarding high-fiber, unrefined diet for life long and asked to keep close follow up, if any further episodes of bleeding occur in future.

#### **Discussion:**

Although diverticular disease is principally a condition that has become widespread in the 20th and 21st centuries, Fleischman coined the term, *divertikel* in 1815 & Klebs in 1869 1st realized that diverticula are acquired and thought to be caused by constipation<sup>11</sup>.

Diverticular disease of the colon is common in developed nations. Westernized nations have high prevalence rates of left-sided diverticulosis. Right-sided diverticulosis although rare in Western populations, is more common in Asia, where overall rates of diverticula are much lower.

Diverticulosis was a quite rare disease before urbanization started. It has been found to have a close relationship between the incidence and economic development of a country. The increasing incidence has been noticeable since the 20th century<sup>11</sup>. Although a cross sectional study shows the prevalence of colonic diverticulosis was significantly lower in Bangladeshis compared with other ethnic groups<sup>12</sup>, but as a result of developing industrialization here, it currently has an intermediate incidence rate.

Since the daily diets are changing vastly as being lower in fiber and higher in processed carbohydrates as refined sugar, flour & cereal; drinks containing unnaturally concentrated carbohydrates. This kind of diet changes the colonic pressures and motility and increasing age also changes the colon wall structure<sup>13</sup>. Even after all these changes, it takes almost 40-years to develop diverticulosis, so it is expected in the middle aged to elderly aged group.

Genetics, male gender, environmental factors, behavioral factors as alcohol, smoking, obesity, comorbid condition as hypothyroidism also plays a vital role in the formation colonic diverticula.

The usual location of diverticula is preferably near the end of the colon on the left side, that is sigmoid colon. But in this case report the involvement was extensive as countless diverticula were present throughout the colon from ascending colon to sigmoid colon, sparing the rectum.

The clinical presentation of colonic diverticula varies widely. Asymptomatic presence of diverticula is called diverticulosis. If it is associated with symptoms such as painless bleeding, then it is termed as diverticular disease. Stool impaction in diverticula can cause diverticular inflammation, called diverticulitis. Fistula formation is another complication, mostly colo-vesical fistula, rarely colo-vaginal fistula. Here, the presented case was about an episode of life threatening per-rectal bleeding in an elderly male primarily caused by colonic diverticular disease.

The painless severe bleeding is seen to be related to the characteristic changes in the angioarchitecture of colonic diverticula. These changes include asymmetric rupture of the vas rectum toward the lumen of the diverticulum precisely at its dome or anti mesenteric margin; conspicuous eccentric intimal thickening of the vas rectum, often with medial thinning and duplication of the internal elastic lamina at and near the bleeding point; and general absence of diverticulitis. This suggests that traumatic factors arising within the diverticular or colonic lumen induce asymmetric intimal proliferation and scarring of the associated vasa recta, predisposing to rupture and massive bleeding<sup>14</sup>.

Totally asymptomatic cases need no treatment or follow ups. Acute diverticulitis cases need broad spectrum antibiotic coverage for anaerobic & gram-negative organisms. 15-30% of such cases don't respond to conservative management & need surgery.

In 70-80% of DD cases with massive hemorrhage, bleeding ceases spontaneously. Subsequently a full video colonoscopy is the 1st line investigation to establish the source of bleeding and exclude any neoplasia. If SRH is found during colonoscopy, it indicates active bleeding & immediate intervention is needed.

#### **Conclusion:**

Diverticulosis is basically a dietary deficiency disease along with many other modifiable & non-modifiable risk factors precipitating its development. There is mostly preventive & may be a prophylactic benefit of taking a regular unrefined carbohydrate diet high with fibers. Also, regular physical exercise shows to help. To sum up, these healthy habits are likely to help to reduce the diverticulosis cases and any deleterious effects of it.

#### **Acknowledgments:**

The authors are grateful to all doctors and staffs of Department of Medicine, Popular medical College & Hospital Dhaka, Bangladesh.

#### **Declaration of interest:**

The authors report no conflict of interest.

#### **Funding:**

The author(s) received no financial support for the research, authorship, and/or publication of this article. The patient is aware that there is no patient identifiable information provided in the article and has consented to this publication. The clinical tests were all done as part of clinical practice.

#### **Abbreviations:**

DD: Diverticular disease, RA: Rheumatoid arthritis  
HCT: Hematocrit, MCV: Mean corpuscular volume,  
MCH: Mean corpuscular hemoglobin, MCHC: Mean corpuscular hemoglobin concentration

RDW: Red cell distribution width, WBC: White blood cells,

RBC: Red blood cells, ESR: Erythrocyte sedimentation rate,

Stool R/E: Stool routine examination, Stool C/S: Stool culture & sensitivity

Urine R/E: Urine routine examination, LFT: Liver function tests

ECG: Electrocardiography

SRH: Stigmata of recent hemorrhage

#### **References:**

- Xu B, Pan W, Zhao L, Sha S. Painless Hematochezia Due to Appendicitis-Case Report and Review of Literature. *Biomedical Journal of Scientific & Technical Research*. 2020;31(1):23947-50. <https://doi.org/10.26717/BJSTR.2020.31.005054>
- Ilyas MI, Szilagy EJ. Diverticular Disease: Management of Diverticular Bleeding: Evaluation, Stabilization, Intervention, and Recurrence of Bleeding and Indications for Resection after Control of Bleeding. *Clinics in Colon and Rectal Surgery*. 2018 Jul;31(4):243. <https://doi.org/10.1055/s-0037-1607963>. PMID:29942215 PMCid:PMC6014846
- Wedel T, Büsing V, Heinrichs G, Nohroudi K, Bruch HP, Roblick UJ, Böttner M. Diverticular disease is associated with an enteric neuropathy as revealed by morphometric analysis. *Neurogastroenterology & Motility*. 2010 Apr;22(4):407-e94. <https://doi.org/10.1111/j.1365-2982.2009.01445.x>. PMID:20040058
- Beranbaum SL, Zausner J, Lane B. Diverticular disease of the right colon. *American Journal of Roentgenology*. 1972 Jun;115(2):334-48. <https://doi.org/10.2214/ajr.115.2.334>. PMID:5037795
- Bae HJ, Kim ST, Hong SG, Lee H, Choi HS, Cho YK, Kim TH, Chung SH. Risk Factors for Asymptomatic Colon Diverticulosis. *The Korean Journal of Gastroenterology*. 2019 Sep 25;74(3):142-8. <https://doi.org/10.4166/kjg.2019.74.3.142>. PMID:31554029
- Kopylov U, Ben-Horin S, Lahat A, Segev S, Avidan B, Carter D. Obesity, metabolic syndrome and the risk of development of colonic diverticulosis. *Digestion*. 2012;86(3):201-5. <https://doi.org/10.1159/000339881>. PMID:22907510

7. Niikura R, Nagata N, Akiyama J, Shimbo T, Uemura N. Hypertension and concomitant arteriosclerotic diseases are risk factors for colonic diverticular bleeding: a case-control study. *International journal of colorectal disease*. 2012 Sep;27(9):1137-43. <https://doi.org/10.1007/s00384-012-1422-x>. PMID:22354135 PMCID:PMC3430839
8. Ilyas MI, Szilagy EJ. Management of diverticular bleeding: evaluation, stabilization, intervention, and recurrence of bleeding and indications for resection after control of bleeding. *Clinics in colon and rectal surgery*. 2018 Jul;31(04):243-50. <https://doi.org/10.1055/s-0037-1607963>. PMID:29942215 PMCID:PMC6014846
9. Katz S, Pardi DS. Inflammatory bowel disease of the elderly: frequently asked questions (FAQs). *Official journal of the American College of Gastroenterology | ACG*. 2011 Nov 1;106(11):1889-97. <https://doi.org/10.1038/ajg.2011.271>. PMID:21862997
10. Painter NS, Burkitt DP. Diverticular disease of the colon: a deficiency disease of Western civilization. *British medical journal*. 1971 May 22;2(5759):450. <https://doi.org/10.1136/bmj.2.5759.450>. PMID:4930390 PMCID:PMC1796198
11. Lahiri RP, Abeles A, Burnand KM, Alazawi W, Bhattacharya S, Foster GR, Knowles CH. A cross sectional study of colonic diverticulosis in the London Bangladeshi population. *United European gastroenterology journal*. 2013 Jun;1(3):191-7. <https://doi.org/10.1177/2050640613489282>. PMID:24917959 PMCID:PMC4040762
12. Heise CP. Epidemiology and pathogenesis of diverticular disease. *Journal of Gastrointestinal Surgery*. 2008 Aug;12(8):1309-11. <https://doi.org/10.1007/s11605-008-0492-0>. PMID:18278535
13. Meyers MA, Alonso DR, Baer JW. Pathogenesis of massively bleeding colonic diverticulosis: new observations. *American Journal of Roentgenology*. 1976 Dec 1;127(6):901-8. <https://doi.org/10.2214/ajr.127.6.901>. PMID:1087123.