

## CLINICAL IMAGE

### MEDICAL QUIZ : IMAGE - 1

SUMAIYA AKTER<sup>1</sup>, REFAYA TASNIM<sup>1</sup>, ASADUL KABIR<sup>2</sup>

Received: 03-04-2022

DOI: <https://doi.org/10.3329/bjm.v33i2.59299>

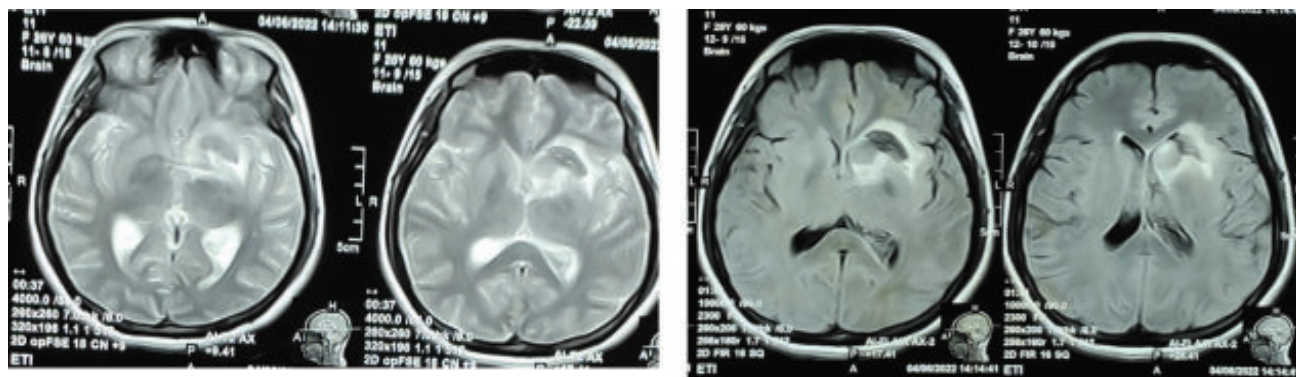
Accepted: 06-04-2022

**Citation:** Akter S, Tasnim R. Radiological image quiz. *Bangladesh J Medicine* 2022; 33: 229

A 26-years-old previously normotensive, non-diabetic lady presented on her 10<sup>th</sup> post-operative day of lower uterine cesarean section with a 5days history of headache and 2 days history of high-grade fever with chills & shivering, and she recently noticed swelling up of both legs. Examination revealed a drowsy, disoriented lady with temperature of 104°F, pulse - 130 bpm, high blood pressure - 150/100 mmHg, and bipedal edema. Her left sided planter reflex was

extensor and neck rigidity was present. Fundoscopic examination of eyes revealed mild papilloedema. She was primigravida with regular ante natal checkup and her pregnancy went uneventful till elective LUCS.

Her test reports showed neutrophilic leukocytosis, urine R/M/E revealed 10-12 pus cells, plenty of RBC and proteinuria. A magnetic resonance imaging (MRI) of brain was done and image is presented below.



**Question 1:** Mention the abnormal radiological findings.

**Question 2:** What is the radiological diagnosis with possible cause?

**Question 3:** How will you treat such a case?

**Question 4:** Which MRI sequence is best for diagnosis the hemorrhage?

1. FCPS part 2 trainee, Dept of Medicine, Dhaka Medical College Hospital, Dhaka, Bangladesh.

2. Professor, Dept of Medicine, Dhaka Medical College, Dhaka, Bangladesh.

**Address of correspondence:** Dr. Sumaiya Akter, FCPS Part 2 trainee, Dept of Medicine, Dhaka Medical College Hospital, Dhaka, Bangladesh. E-mail: [sumaiya.sneha118@gmail.com](mailto:sumaiya.sneha118@gmail.com)