

## CLINICAL IMAGE

### MEDICAL QUIZ : IMAGE - 2

MUHAMMAD ABDUR RAHIM

Received: 05-04-2022

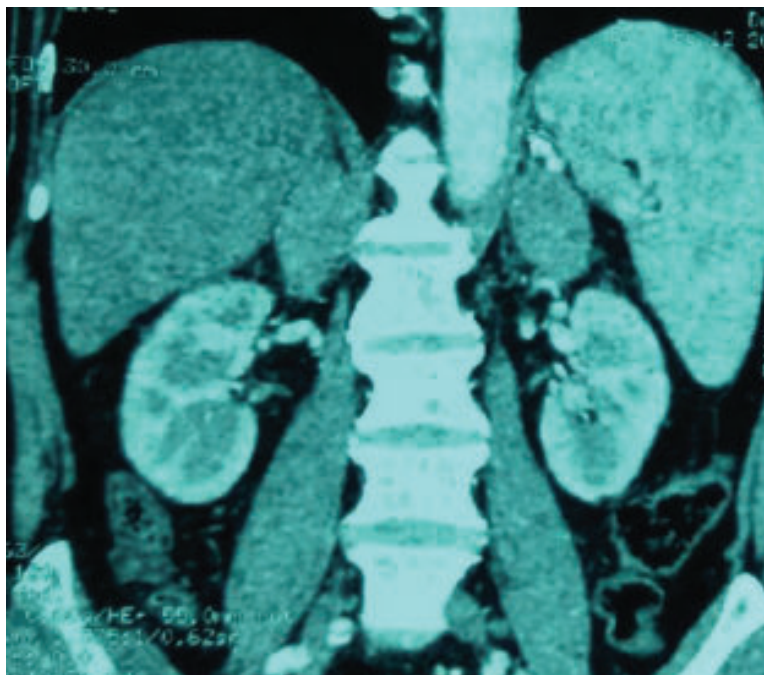
DOI: <https://doi.org/10.3329/bjm.v33i2.59300>

Accepted: 06-04-2022

**Citation:** Rahim MA. Medical Quiz : Image. Bangladesh J Medicine 2022; 33: 230

A 61-year-old man, diagnosed with type 2 diabetes mellitus, presented with a 3-month history of fever and weight loss. He had neutrophilic leucocytosis, a normal chest radiograph and Mantoux test (MT)

revealed a 5 mm induration at 72 hours. Abdominal computed tomography (CT) scan axial film is shown (Figure 1) below.



**Figure 1**

**Answer the following questions.**

**Question 1.** Mention two abnormal radiological findings.

**Question 2.** Mention three differentials.

**Question 3.** Mention one test that may establish the aetiological diagnosis.

---

**Address of correspondence:** Muhammad Abdur Rahim, Associate Professor, Nephrology, BIRDEM General Hospital, Dhaka, Bangladesh. Email: [muradrahim23@gmail.com](mailto:muradrahim23@gmail.com), Mob: +8801674534500

**Copyright:** @2021 Associations of Physicians of Bangladesh