

## CLINICAL IMAGE

### MEDICAL QUIZ:1

AKM MONWARUL ISLAM<sup>1</sup>, HUMAIRA JESMIN<sup>2</sup>

Received: .07.04.2023

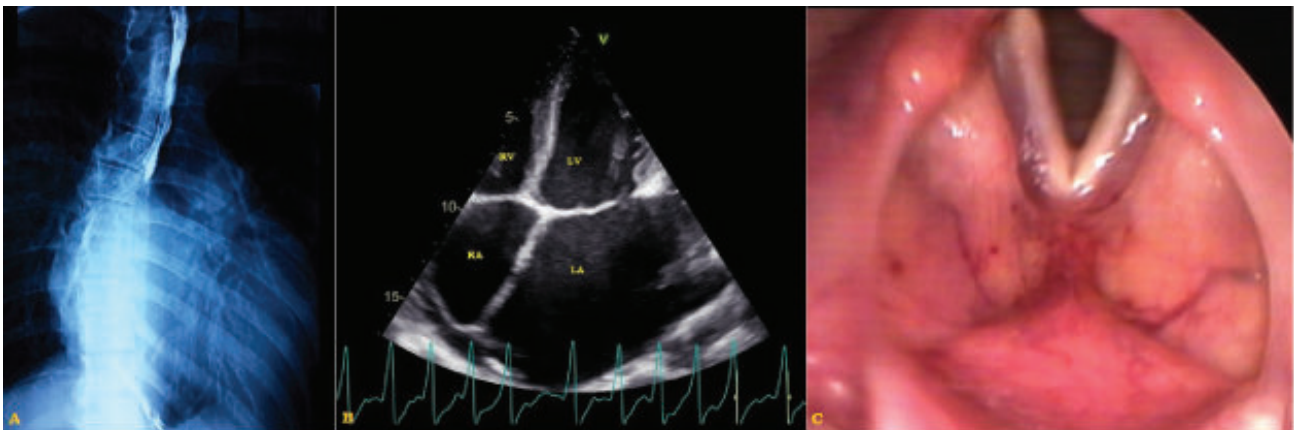
DOI: <https://doi.org/10.3329/bjm.v34i2.65621>

Accepted: 10.04.2023

**Citation:** Islam AKMM, Jesmin H. Medical Quiz-1. *Bangladesh J Medicine* 2023; 34: 172.

A 35-year-old lady presented with progressive breathlessness, dysphagia for 3 months, and hoarseness of voice for 1 month. She was on anti-tubercular drugs for the presumptive diagnosis of pulmonary tuberculosis, but there was no response. Physical examination revealed irregularly irregular

pulse, tapping apex beat, variable intensity of S<sub>1</sub>, and a localized mid-diastolic murmur in apical area. Endoscopy of upper gastrointestinal tract found no organic lesion. She underwent barium (Ba) swallow X-ray of oesophagus (A), echocardiography (B), and fiberoptic laryngoscopy (FOL) (C).



**Figure-1:** Barium swallow X-ray of oesophagus (A), echocardiography (B), and fiberoptic laryngoscopy (FOL) (C).

#### Questions:

- What are the findings in Ba-swallowx-ray of oesophagus?
- What is the single-most important observation in echocardiography?
- Mention the relevant finding(s) in fiberoptic laryngoscopy.
- What is the clinical diagnosis?
- Outline the pathophysiology of the condition.

- Associate Professor, National Institute of Cardiovascular Diseases, Sher e Bangla Nagar, Dhaka 1207, Bangladesh.
- Junior Consultant Medicine “OSD, DGHS, Mohakhali, Dhaka-1212, Bangladesh

**Address of Correspondence:** Dr. AKM Monwarul Islam, Associate Professor, National Institute of Cardiovascular Diseases, Sher e Bangla Nagar, Dhaka 1207, Bangladesh. Email: [drmonwarbd@yahoo.com](mailto:drmonwarbd@yahoo.com)

**Copyright:** © 2023 Association of Physicians of Bangladesh