

## CASE REPORT

# PARADOXICAL REACTIONS IN THE FORM OF OPTOCHIASMATIC ARACHNOIDITIS AND STROKE IN AN IMMUNOCOMPETENT GIRL WITH TUBERCULOUS MENINGITIS- A CASE REPORT

MD. ALAMGIR HOSSAIN<sup>1</sup>, AMINUR RAHMAN<sup>2</sup>, AJAY KUMAR AGARWALLA<sup>3</sup>, MUHAMMAD JAMIL AHMED<sup>4</sup>, ABUL HASNAT MD. RUSSEL<sup>5</sup>, SHAHJADA MOHAMMAD DASTEGIR KHAN<sup>2</sup>, MOHAMMAD MOSHIUR RAHMAN<sup>2</sup>, BIPLAB PAUL<sup>2</sup>, PALLAB KANTI SAHA<sup>2</sup>, ZAHED ALI<sup>6</sup>

### Abstract

The paradoxical response is characterized by clinical or radiologic worsening of pre-existing lesions or the appearance of new lesions following initiation of treatment for tuberculosis (TB). The paradoxical response has raised questions about the accuracy of the diagnosis, the potential for treatment failure, and the presence of an underlying disease, making it an important topic of care for clinicians. In this case report, we present the paradox reaction of a 14 year old girl diagnosed and treated for TB meningitis. This healthy immune girl is successfully treated with steroids, and we discuss the importance of treating the paradox of tuberculosis progression despite the use of effective anti-TB drugs.

**Key words:** Paradoxical Reactions, Optochiasmatic Arachnoiditis, Immunocompetent, Tuberculous Meningitis

Received: 25-05-2023

Accepted: 16-08-2023

DOI: <https://doi.org/10.3329/bjm.v34i3.68433>

**Citation:** Hossain MA, Rahman A, Agarwalla AK, Ahmed MJ, Russel AHM, Khan SMD et al. Paradoxical Reactions in the Form of Optochiasmatic Arachnoiditis and Stroke in an Immunocompetent Girl with Tuberculous Meningitis- A Case Report. *Bangladesh J Medicine* 2023; 34: 244-251.

### Introduction:

Patients with tuberculosis (TB) experience paradoxical reactions, which are clinical or radiological exacerbations of lesions or new lesions arising after treatment.<sup>1</sup> Paradoxical reactions are most commonly observed in the lungs, lymph nodes and in the central nervous system (CNS) affected by TB<sup>2</sup>. There is limited literature on paradoxical responses in HIV-

positive children. In a study of 115 HIV-positive children with pulmonary (and extrapulmonary) TB, 12 (10%) patients experienced paradoxical reactions.<sup>3</sup> It is important for clinicians to be aware of the clinical nature of paradoxical reactions, especially in patients with treatment failures or underlying diseases<sup>4</sup>. Paradoxical reactions present serious challenges in the management of CNS TB. Drug resistant TB is

1. Registrar, Department of Neurology, Sir Salimullah Medical College Mitford Hospital, Dhaka- 1100, Bangladesh.
2. Assistant Professor, Department of Neurology, Sir Salimullah Medical College, Dhaka- 1100, Bangladesh.
3. Assistant Registrar, Department of Neurology, Sir Salimullah Medical College Mitford Hospital, Dhaka- 1100, Bangladesh.
4. Registrar, Department of Neurology, Sylhet MAG Medical College Hospital, Sylhet, Bangladesh
5. Resident, Department of Neurology, Sir Salimullah Medical College Mitford Hospital, Dhaka, Bangladesh
6. Professor, Department of Neurology, Sir Salimullah Medical College, Dhaka- 1100, Bangladesh.

**Address of Correspondence:** Dr. Aminur Rahman, Assistant Professor, Department of Neurology, Sir Salimullah Medical College, Dhaka- 1100, Bangladesh, E-mail: [draminur@yahoo.com](mailto:draminur@yahoo.com)

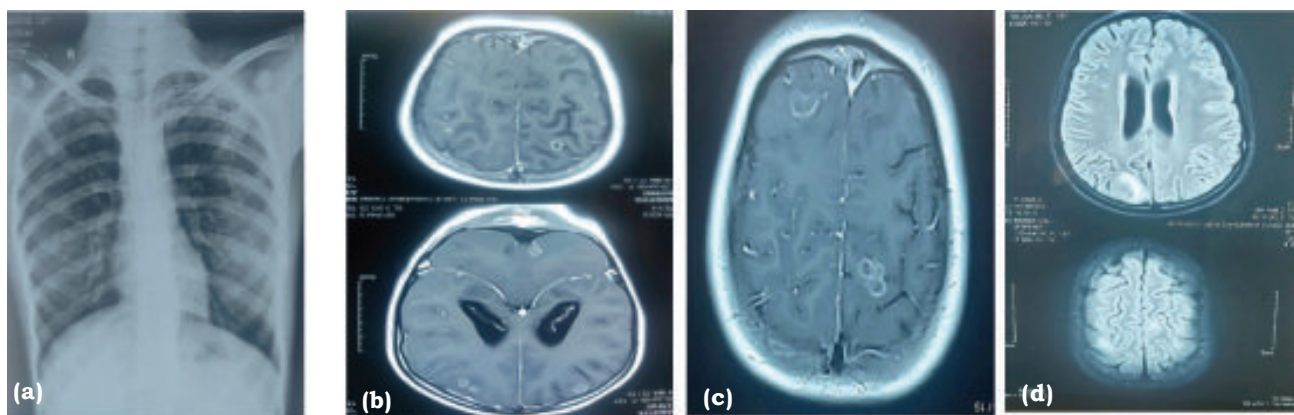
always a question when the patient is worsening, and paradoxical reactions often lead to inappropriate increment(s) or addition(s) of more toxic newer anti-tubercular drugs with multiple side effects <sup>4</sup>. This case of a child highlights this situation and increases clinicians' awareness.

**Case Report:**

A 14-year-old girl was admitted to the department of neurology, sir salimullah medical college Mitford Hospital. She had been complaining for 5 months, losing weight for 4 months, suffering from headache for 1 month, and was disoriented for last 1 day. On inquiry, she did not have a history of chronic cough or chest pain or breathing difficulty. She had joint pain and skin rash. She had oral ulceration and skin pigmentation. She was also in contact with a TB patient. Her father was diagnosed with pulmonary tuberculosis in 2018 and recovered completely with 6 months anti-tuberculosis drugs. She was diagnosed as Tuberculous meningoencephalitis (TBM) on the basis of physical examination, and laboratory findings,

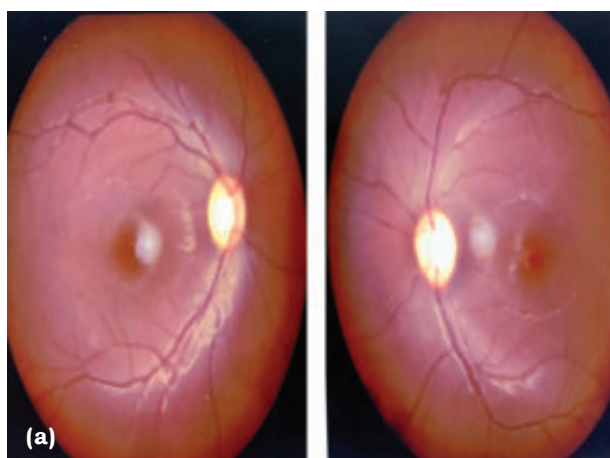
including CSF study, and radiological findings, including chest X-ray MRI of brain. The chest X ray showed inhomogeneous opacity in both lung fields (Fig-a). MRI of brain demonstrated multiple tuberculoma in both cerebral hemisphere and cerebellum (Fig 1: b, c, d). Anti-TB treatment (isoniazid, rifampicin, ethambutol, and pyrazinamide) and 0.2mg/kg Inj. Dexamethasone was given. As the treatment progressed, her complaints improved and the dexamethasone was decreased gradually.

After a month of hospitalization, the patient was discharged with a GCS of 15, cranial nerves normal, muscle power normal, fundus normal, and planter-flexor. However, 7 days later at home, the patient developed sudden right side weakness and blurred vision. She was again admitted to that hospital and upon examination had a GCS of 12 with a slurred, indistinct speech. She also had visual acuity (VA) finger counting and a bilateral dilated, poorly reacting pupil. Her fundal photograph showing bilateral optic atrophy (Figure: 2a) .Perimetry showing profound visual loss (Figure:2b).




**Fig-1: (a)** Chest X ray showing inhomogeneous opacity in both lung fields.

**Fig-1: b,c,d** MRI of brain showing multiple tuberculoma in both cerebral hemisphere and cerebellum.



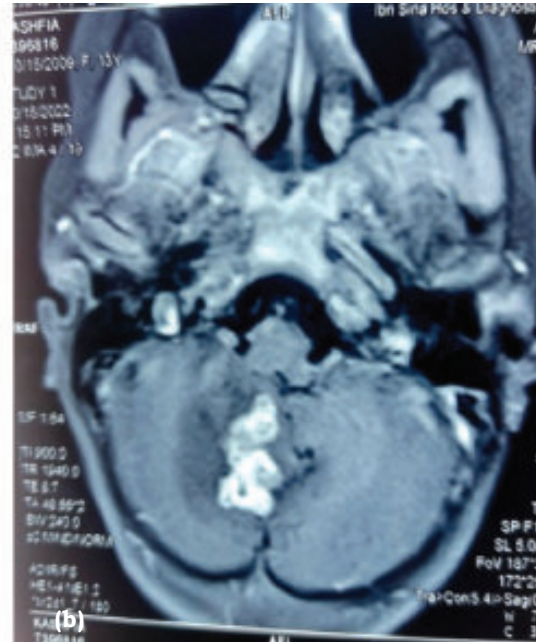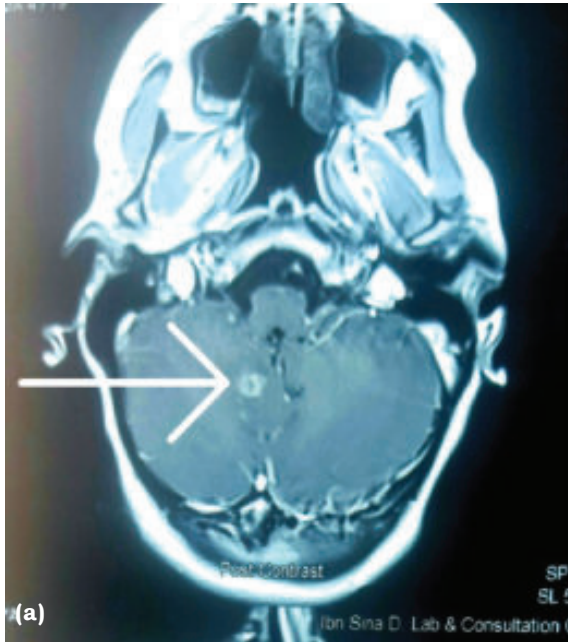
**Fig-2a :** Fundal photograph showing bilateral optic atrophy



**Fig:2b** Perimetry showing profound visual loss.

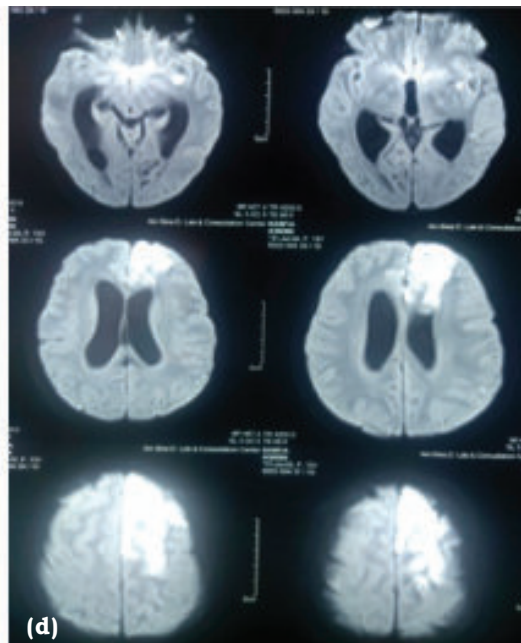
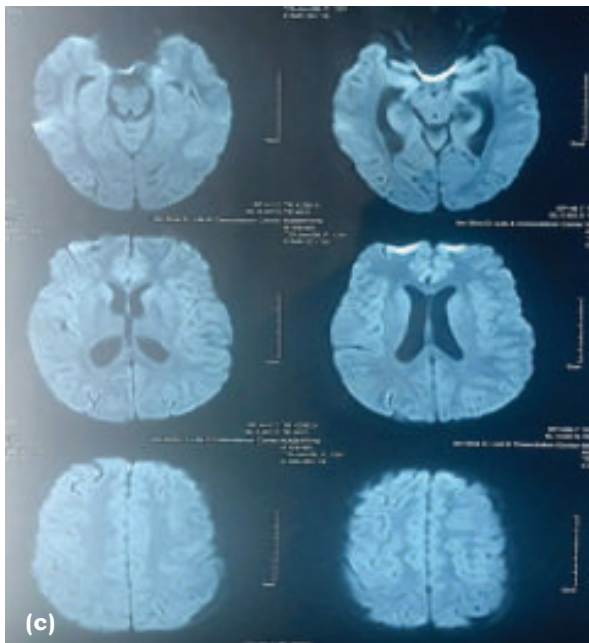
She was also diagnosed with right upper motor facial palsy and right side extensor planter response. At the hospital, an MRI of the brain was performed with contrast. The MRI showed that there was a large, growing, and absent-inhabiting tuberculoma on the right side of the brain in comparison to the previous film, and an increasing number surrounded by edema. In the current film, there was an infarct in the anterior

cerebral artery territory (ACA) that was completely absent in the previous film (Figures-3: a, b, c, d). in MRI of brain showed small, single tuberculoma in right cerebellar hemisphere without edema Fig-3 (a). (b) Multiple conglomerated tuberculoma surrounded by perilesional edema Fig-3 (b) (c) No evidence of infarct before starting treatment Fig-3 (c). A large ACA territory infarct after one month 7 days after starting treatment Fig-3 (d).



**Fig-3:** (a) Small, single tuberculoma in right cerebellar hemisphere without edema.

**Fig-3:** (b) Multiple conglomerated tuberculoma surrounded by perilesional edema



**Fig-3:** (c) No evidence of infarct before starting treatment.

**Fig-3:** (d) A large ACA territory infarct after one month 7 days after starting treatment.

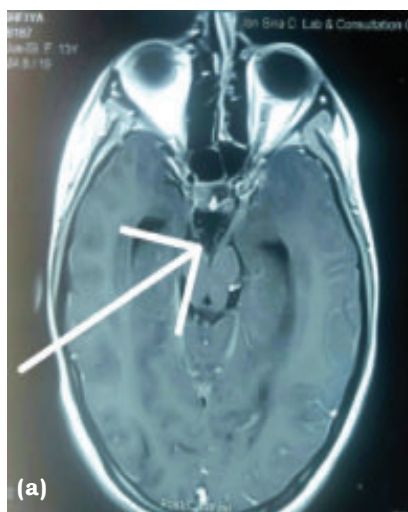
While assessing profound visual loss Ethambutol induced retrobulbar neuritis was our primary consideration. But new MRI features was a little bit surprising for us.

Simultaneously we keep examining her fundus several times. At one stage we found disk pallor in both eye. Then we went for fundal photograph and HVFA. (Figure: 2 a,b)

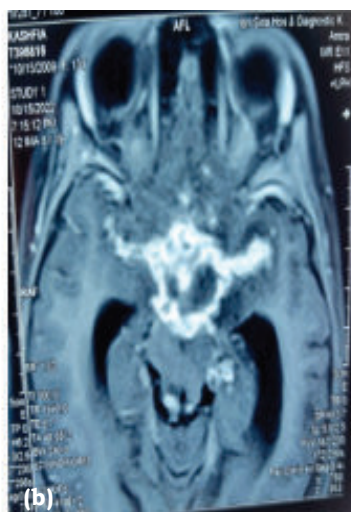
After comparison to previous MRI, the following findings were found in the most recent MRI (Fig-4a-c): Fig-4 : (a)Before starting treatment (b) Optochiasmatic arachnoiditis—Dense plaque-like basal exudates especially around the optic chiasm and cisternal part of optic nerve ). (c) T1W contrast sagittal images; shows multiple ring and nodular enhancing lesions and exudates in the suprasellar cistern involving the optochiasmatic region., increased exudation in the basal cisterns resulting in communicating hydrocephalus and transpendymal migration of CSF, robust meningeal enlargement compared to the previous MRI. Extensive investigations were conducted to exclude alternative diagnosis. CBC, CRP - normal, ANA - negative, p ANCA – normal, ANCA - normal, S Protein C & S - normal, S Homocysteine - normal, Anti HIV 1 & 2 - negative,

S. Calcium - 8.7 mg / dl, MRV of brain - normal. No alternative/ differential diagnosis was found after extensive investigations. Less/no chance of Multidrug-resistant TB (MDR TB) , presence of Paradoxical reactions IN TB (female gender) risk factors, disseminated/extra pulmonary Tuberculosis with high mycobacteriostatic antigen load, time association between initiating anti tubercular therapy and deterioration in clinical and radiological features- finally we considered our patient as case of Paradoxical Reaction (PR) to Anti-tubercular therapy..

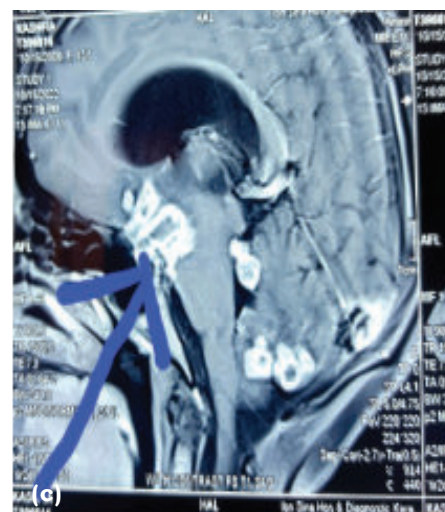To overcome the paradoxical reactions, we correct dose of Inj. Dexamethasone in tapering mode. Tab. Intravenous administration of 500 mg of Levofloxacin (0 + 0+1) was initiated as previously treated patient. Drug Susceptibility Testing (DST) not performed according to 2021 National TB Guideline. We found Clinical status at 2 months of post treatment:, her GCS found 15, VA 5/60 (both eyes), Optic disc pallor and facial palsy improved .Her muscle power found 3 on right side. She walked independently. Her MRI of brain (Figure: 5 a-f) features showed significant improvement. Fig-5:( a) and ( b) showing improvement of cerebellar lesions. (c) and (d) showing improvement of Optochiasmatic arachnoiditis (e) and (f) showing improvement of ACA infarct



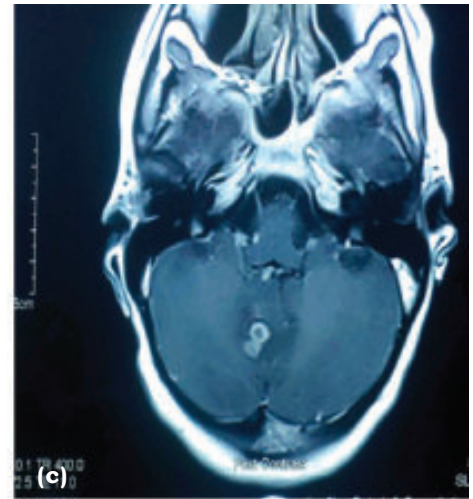
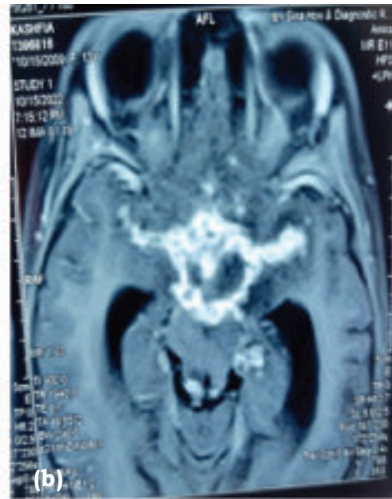
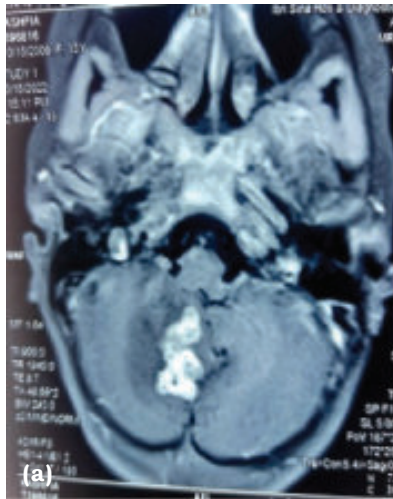
**Fig-4a** Before starting treatment



**Fig-4:** b Optochiasmatic arachnoiditis — Dense plaque-like basal exudates especially around the optic chiasm and cisternal part of optic nerve ).

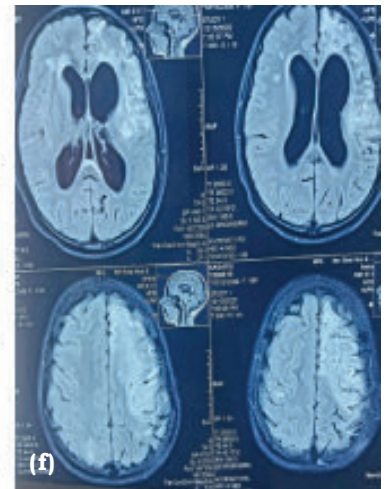
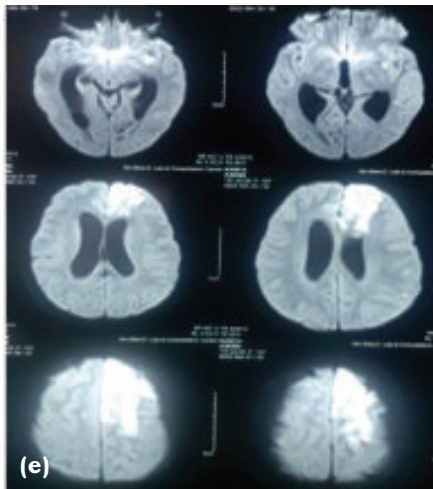
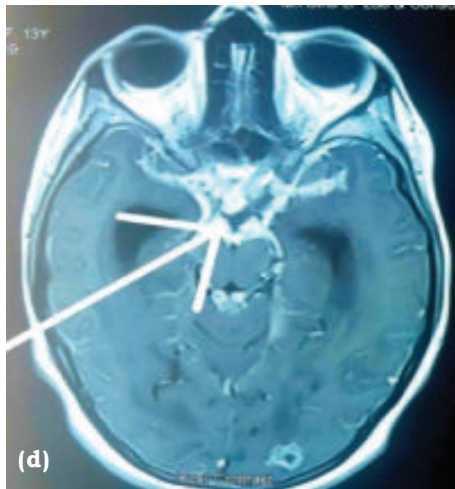


**Fig-4:** c T1W contrast sagittal images; shows multiple ring and nodular enhancing lesions and exudates in the suprasellar cistern involving the optochiasmatic region.



**Fig-5:** (a) and (b) showing improvement of cerebellar lesions

**Fig-5:** (c) showing improvement of Optochiasmatic arachnoiditis



**Fig-5:** (d) showing improvement of Optochiasmatic arachnoiditis

**Fig-5:** (e) & (f) showing improvement of ACA infarct

### Discussion:

Paradoxical reactions are mostly described in case reports and in small number of cases. They include a wide range of clinical symptoms and abnormalities in neuroimaging, as well as a change in the cerebral fluid picture. Changes in cerebral fluid may be lymphocytic, polymorphonuclear dominant or elevated protein. Paradoxical reactions do not always mean treatment failure. Corticosteroids have been shown beneficial effect.<sup>4,5</sup>

Paradoxical reactions occur in 6 to 30% of patients receiving treatment for tuberculosis<sup>6</sup>. These reactions are most common in adults and in immunocompetent patients. Very rarely, paradoxical reactions have been observed in children, and the earliest time at which it occurred was in a 21-day old

child who was receiving treatment for congenital pulmonary tuberculosis<sup>7</sup>. Paradoxical reaction manifestations, such as Optochiasmatic, Spinal Arachnoid, and a Large Brain Tumor, are serious conditions with severe disabilities and a high risk of death<sup>8</sup>. These conditions necessitate immediate treatment with immuno-modulatory drugs. Currently, high-dose corticosteroid therapy is the preferred treatment. Other immuno-modulating drugs such as TNF-A Antagonists, Thalidomide and Interferon- $\alpha$  are also used<sup>8</sup>.

While paradoxical reactions in adults are rare in Bangladesh, paradoxical reactions in children have never been reported in TB meningitis cases. In our case, a child had a paradoxical reaction (ACA stroke) causing profound visual loss, which was rarely

observed and reported. In contrast, the reported rate of paradoxical response in HIV infection patients is 35%, which is less than 5% in normal immune system TB patients<sup>9</sup> However, in our case, HIV was negative. Risk factors for paradoxical reactions include anemia; hypoalbuminaemia; lymphopenia; female gender; and disseminated / extrapulmonary TB<sup>10</sup> Our patient also had some risk factors. Anti-TB treatments do not need to be changed or stopped when paradoxical reactions occur. 95% of Mycobacteria is sensitive to the treatment<sup>11</sup> Resistance to anti- TB drugs is still a concern, especially in my country where the spread of resistant TB strain is a constant development.

Paradoxical reactions can be treated with systemic corticosteroids and/or surgical procedures. Corticosteroids reduce intracranial pressure, which helps in reducing any of the neurological symptoms of the disease<sup>3</sup>. Surgical alternatives include a ventriculoperitoneal shunt implementation in case of hydrocephalus or surgical *lyses* of adhesion in case of devastating Optochiasmatic arachnoiditis; however, no surgical treatment is required in our case. In our case we treated with Anti-tubercular therapy with Inj Dexamethasone started to overcome paradoxical response and continued proper dosage in tapering manner. This paradoxical response occurs 3 – 12 weeks after initiation of treatment for TB; however, this response may take up to 18 months<sup>12</sup>. We observed this paradoxical response in our patient at 5 weeks post-treatment with several central nervous system (CNS) symptoms. At 2 months post-treatment, her clinical status improved as follows: Glasgow Coma Scale (GCS) found 15, Visual acuity (VA) was 5 / 60 in both eyes Optic disk pallor was improving Facial Palsy was improved Muscle power was found 3/5 on right side and walked independently.

Drug resistant CNS TB was not a concern in our patient, as she demonstrated significant improvement in the first month of antiretroviral therapy. Complete improvement in her father's TB may suggest reduced risk of infection with a resistant organism.

### Conclusion:

The paradoxical response results in either an exacerbation of lesions clinically or radiological, or new lesions after initiation of treatment in patients with TB, which occurs in approximately one third of patients with TB. This has caused physicians to worry about whether the diagnosis is correct, if treatment will not work, or if there is another underlying disease. So this is a difficult situation for clinicians.

### Conflict of Interest:

The authors stated that there is no conflict of interest in this study

### Funding:

This research received no external funding.

### Ethical consideration:

The study was conducted after approval from the ethical review committee of Sir Salimullah Medical College. The confidentiality and anonymity of the study participant was maintained.

### Consent:

For the purpose of publishing this case report and any related photos, the parents are written informed consent was acquired.

### Acknowledgments:

The authors were grateful to the staffs and management of the Department of Neurology in Sir Salimullah Medical College Mitford Hospital, Bangladesh.

### References:

1. Monga PK, Dhaliwal U: Paradoxical reaction in tubercular meningitis resulting in involvement of optic radiation. *Indian J Ophthalmol.* 2009, 57:139-41. <https://doi.org/10.4103/0301-4738.45504>. PMID:19237788 PMCID:PMC2684430
2. Garg RK, Malhotra HS, Kumar N: Paradoxical reaction in HIV negative tuberculous meningitis. *J Neurol Sci.* 2014, 340:26-36. <https://doi.org/10.1016/j.jns.2014.03.025>. PMID:24680563
3. Singh AK, Malhotra HS, Garg RK, Jain A, Kumar N, Kohli N, Verma R, Sharma PK. Paradoxical reaction in tuberculous meningitis: presentation, predictors and impact on prognosis. *BMC Infect Dis.* 2016 Jun 21; 16:306. <https://doi.org/10.1186/s12879-016-1625-9>. PMID:27329253 PMCID:PMC4915108
4. Garcia-Monco JC, Ferreira E, Gomez-Beldarrain M. The therapeutic paradox in the diagnosis of tuberculous meningitis. *Neurology.* 2005; 65:1991-2. <https://doi.org/10.1212/01.wnl.0000188885.31724.07>. PMID:16380632
5. Kim SH, Kim YS. Immunologic paradox in the diagnosis of tuberculous meningitis. *Clin Vaccine Immunol.* 2009;16:1847-9. <https://doi.org/10.1128/CVI.00321-09>. PMID:19846679 PMCID:PMC2786389
6. Gupta M, Bajaj BK, Khwaja G. Paradoxical response in patients with CNS tuberculosis *J Assoc Physicians India.* 2003;51:257-60.
7. Thwaites GE, Nguyen DB, Nguyen HD, et al. Dexamethasone for the treatment of tuberculous meningitis in adolescents and adults. *N Engl J Med.*

- 2004; 351:1741-51. <https://doi.org/10.1056/NEJMoa040573>. PMID:15496623
8. Sinha MK, Garg RK, Anuradha HK, Agarwal A, Singh MK, Verma R, et al. Vision impairment in tuberculous meningitis: predictors and prognosis. *J Neurol Sci.* 2010;290:27-32. <https://doi.org/10.1016/j.jns.2009.12.012>. PMID:20056252
  9. Kalkan A, Serhatlioglu S, Ozden M, Denk A, Demirdag K, Yilmaz T, et al Paradoxically developed optochiasmatic tuberculoma and tuberculous lymphadenitis: A case report with 18-month follow up by MRI *South Med J.* 2006;99:388-92. <https://doi.org/10.1097/01.smj.0000209091.57281.23>. PMID:16634250
  10. Volpe-Chaves CE, Lacerda MLGG, Castilho SB, Fonseca SSO, Saad BAA, Franciscato C, Tibana TK, Nunes TF, Venturini J, Oliveira SMDVL, Paniago AMM. Vertebral tuberculosis as a paradoxical reaction to the treatment of pulmonary and meningeal tuberculosis in an immunocompetent patient: A case report. *Medicine (Baltimore).* 2020 May 22; 99(21):e20012. <https://doi.org/10.1097/MD.00000000000020012>. PMID:32481268 PMCID: PMC7249907
  11. Hawkey CR, Yap T, Pereira J, Moore DA, Davidson RN, Pasvol G, Kon OM, Wall RA, Wilkinson RJ. Characterization and management of paradoxical upgrading reactions in HIV-uninfected patients with lymph node tuberculosis. *Clin Infect Dis.* 2005;40:1368-71. <https://doi.org/10.1086/429317>. PMID:15825042
  12. Karagoz T., Altinoz H., Senol T., Kula O., Yarkin T., Yazicioglu O. Paradoxical response to antituberculous therapy. *Turkish Respiratory Journal.* 2007;4:17-20.