

CLINICAL IMAGE

MEDICAL QUIZ: IMAGE-1

AMINUR RAHMAN

Received: 10.08.2023

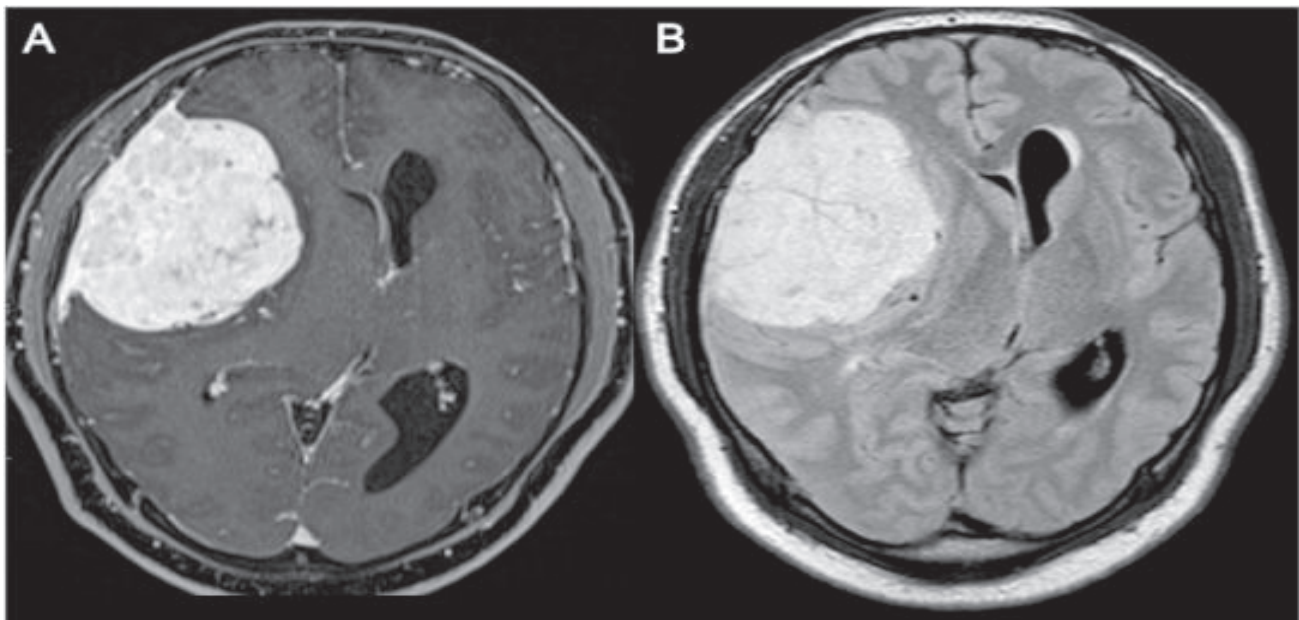
Accepted: 16.08.2023

DOI: <https://doi.org/10.3329/bjm.v34i3.68444>

Citation: Rahman A. Clinical Image-1. Bangladesh J Medicine 2023; 34: 260.

A 62-year-old female with no medical history, presented 3 months' ago headaches resistant to usual analgesics with behavior disorders. Symptoms worsened with an

onset of vomiting, without sensory-motor deficit or seizures. She undergoes a contrast enhanced MRI (A) and FLAIR (B). Ans the following questions.



Questions

1. Describe the film (3 important features)
2. What is the most likely diagnosis
3. What are the treatment modalities

Address of Correspondence: Dr Aminur Rahman, Assistant professor, Department of Neurology, Sir Salimullah Medical College, Mitford, Dhaka, Bangladesh, email: draminur@yahoo.com; Cell no: +08801711189092; [Orcid.org/0000-0001-9261-7734](https://orcid.org/0000-0001-9261-7734)

Copyright: © 2023 Association of Physicians of Bangladesh