

## CLINICAL IMAGE

### MEDICAL QUIZ: IMAGE - 2

MUHAMMAD ABDUR RAHIM

Received: 12.08.2023

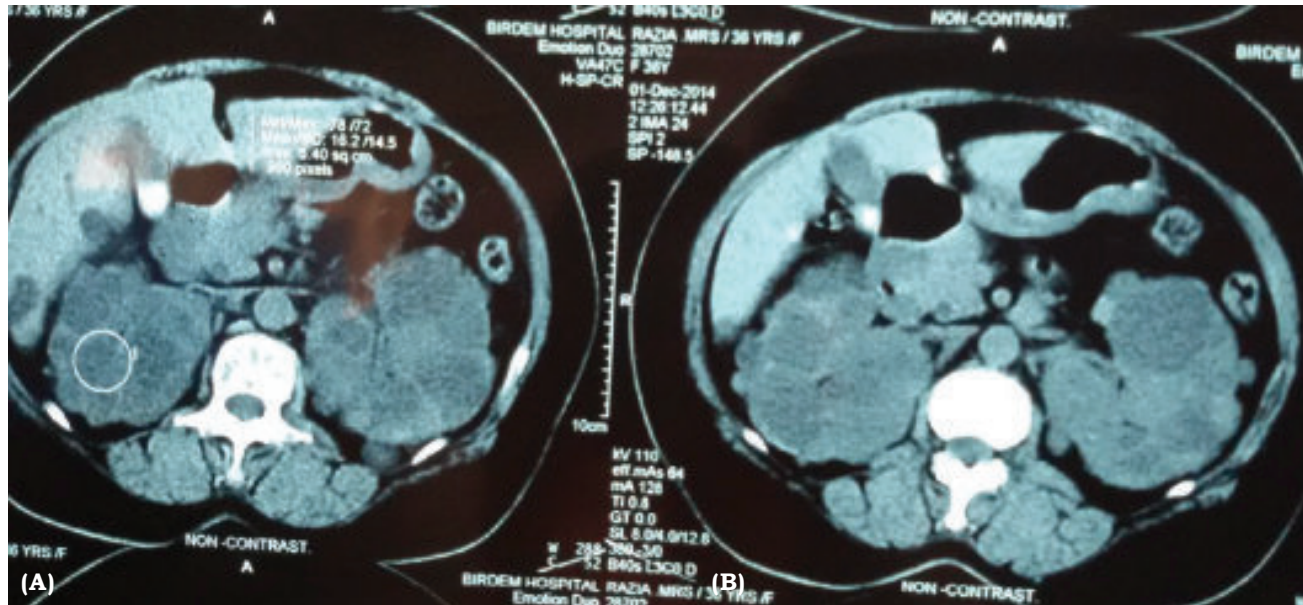
Accepted: 16.08.2023

DOI: <https://doi.org/10.3329/bjm.v34i3.68445>

**Citation:** Rahim MA. Medical Quiz: Image-2. Bangladesh J Medicine 2023; 34: 261.

A 50-year-old male patient, with family history of kidney failure, presented with hypertension and vague upper abdominal discomfort. Clinically, he had bilateral

ballotable kidneys. A non-contrast, computed tomography (CT) scan, axial film of his abdomen is shown. Read the film and answer the following questions.



#### Questions

1. Mention 2 abnormal radiological findings.
2. What is the most likely diagnosis?
3. Mention 1 cardiovascular association.
4. Patient developed sudden severe headache followed by unconsciousness. Mention possible cause and pathogenesis.

**Address of Correspondence:** Dr. Muhammad Abdur Rahim, Associate Professor, Department of Nephrology, BIRDEM General Hospital, Dhaka-1000, Bangladesh. Email: [muradrahim23@yahoo.com](mailto:muradrahim23@yahoo.com)

**Copyright:** © 2023 Association of Physicians of Bangladesh