

CLINICAL IMAGE

MEDICAL QUIZ: IMAGE-1

AMINUR RAHMAN

Received: 20/04/2024

DOI: <https://doi.org/10.3329/bjm.v35i2.72812>

Accepted: 22/04/2024

Citation: Rahman A. Medical Quiz: Image-1. Bangladesh J Medicine 2024; 35: 125

Clinical scenario:

A 58-year-old woman was transferred from the district hospital with complaints of headache, barely perceptible speech, and weakness in the right sided of body, with a week of onset, associated with partial seizures in the right upper limb. He had comorbidities were non-insulin-treated type 2 diabetes mellitus, medicated glaucoma, treated gastric cancer, smoking, and daily alcohol abuse. He was also presented for

dental pain and reported urgently a week ago but no regular dental follow-up.

During admission, at the Emergency Department, the patient presented a Glasgow Score of 15, fundus normal, right sided muscle power grade 3, and angle of mouth deviated to the right. No other changes in physical examination were sought. Magnetic resonance investigation (MRI) revealed (Fig. 1A-D) with a lesion and MRS (E-F) was also done. Please answer the following question.

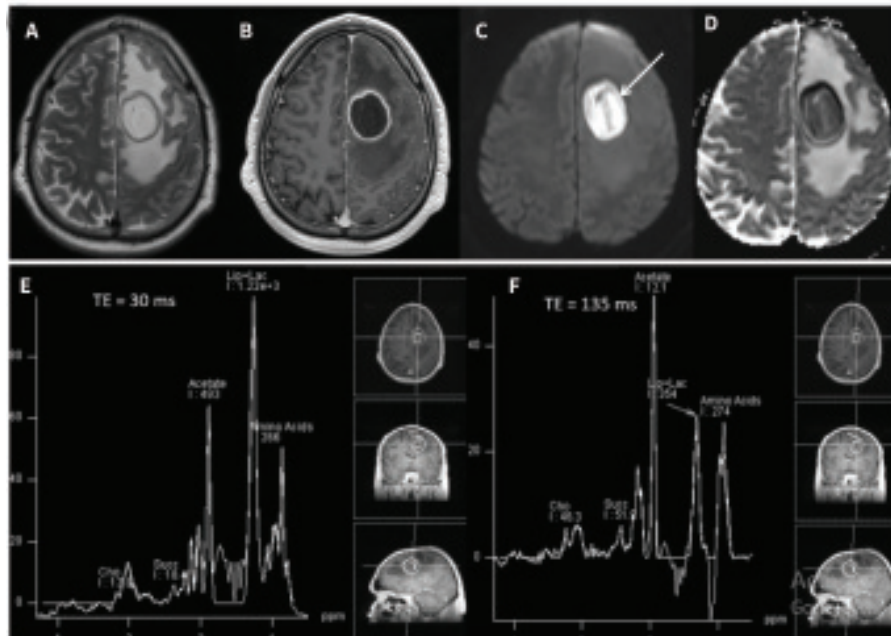


Figure (A-D) Conventional MRI: and MRS (E-F)

Questions:

1. What are the MRI findings?
2. What is diagnosis
3. What are the differentials?
4. What are the MRS findings?
5. Then above MRI+MRS findings what is your diagnosis
6. How you confirm the diagnosis?