

CLINICAL IMAGE

MEDICAL QUIZ: IMAGE-2

MUHAMMAD ABDUR RAHIM

Received: 20/04/2024

DOI: <https://doi.org/10.3329/bjm.v35i2.72880>

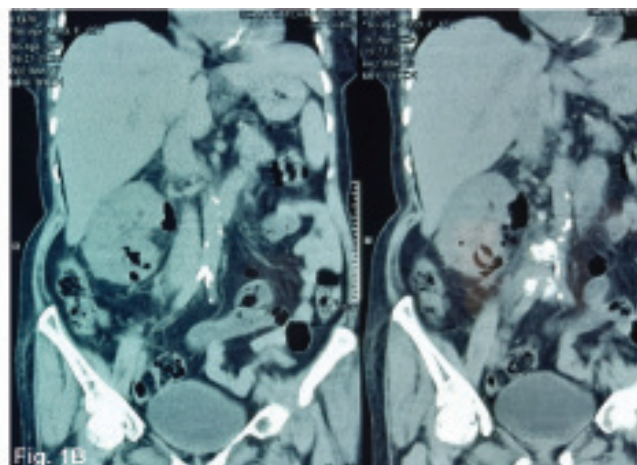
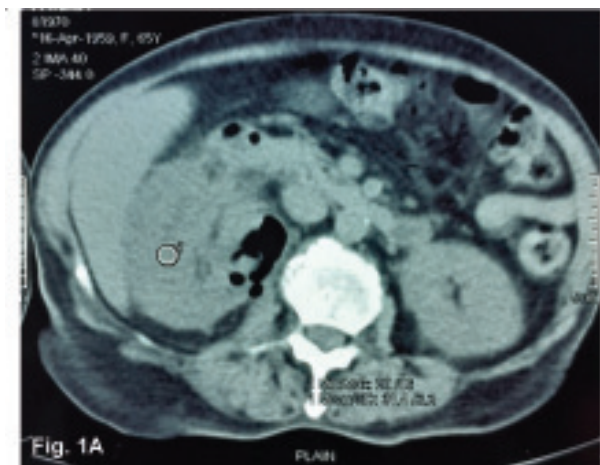
Accepted: 22/04/2024

Citation: Rahim MR. Medical Quiz: Image-2. Bangladesh J Medicine 2024; 35: 126

A 65-year-old lady, diagnosed with type 2 diabetes mellitus, hypertension and chronic kidney disease stage 4 presented with a 5-day history of high-grade fever with chills, vomiting and right loin pain. She was febrile with a temperature of 103° F, had tachycardia (pulse 116/min) and there was right renal angle tenderness. She had neutrophilic leukocytosis (total white cells 17,260/cmm of blood with 70.2%

neutrophils) and urine routine and microscopic examination revealed plenty of pus cells/high power field (HPF) and 4-6 red cells/HPF. Urine and blood cultures were requested.

A non-contrast abdominal computed tomography (CT) scan was performed. An axial and a coronal section is shown (Fig.1A & B). Study the films and answer following questions.



Questions

- Q 1. Mention abnormal CT findings.
- Q 2. What is the radiological diagnosis?
- Q 3. Mention one risk factor that might have contributed to the condition in this case.
- Q 4. Mention principles of management.