

Case Report

Plasmodium malariae in Chittagong, Bangladesh

Muhammad Ehsanul Haque¹, Muhammad Anwar Husain¹, Nasima Akter¹, Muhammad Abdul Mazed¹, Khan Mashrequl Alam¹, Muhammad Tipu Sultan¹, Arup Kanti Dewanjee¹, Muhammad Shaqil Ahmed¹, Muhammad Arifur Rahman¹, Muhammad Zakir Hossain¹

¹ Department of Microbiology, Chittagong Medical College, Chittagong

Summary:

We detected a case of *Plasmodium malariae* in Chittagong, Bangladesh. The person was an adult male, presented clinically as severe malaria. Blood slide examination by microscopy and pan malarial immunochromatographic test (ICT) revealed the case as *Plasmodium malariae* infection. The patient presented as severe malaria case for which he was hospitalized and recovered after seven days of quinine treatment.

Background:

Malaria remains a global concern. An estimated 300-500 million clinical cases occur each year throughout the world. Among them deaths occur in between 1.1-2.7 millions, most of them are children of below 5 years of age. Vast majority of cases are found in 107 countries in the tropical regions of Africa, Asia, Central and South Americas where the disease is endemic^{1,2}.

Malaria is also a major public health concern in Bangladesh. Approximately 33.6% of total populations (150 million) of the country are at risk of malaria. So far two species of malarial parasites i.e., *P vivax* and *P falciparum* are prevalent in the country but there is evidence of increasing proportion of malaria cases by *P falciparum* which become severe and often complicated². Apart from those two species recently *P malariae* is being detected which presents with severe disease.

Case report:

Md Abu Bakar, a 45 yr old male from Anwara in Chittagong got himself admitted in Chittagong Medical College Hospital (CMCH) in January, 2011. On admission clinical presentations as stated by the patient were high fever with rigor for one week associated with severe headache, bodyache, anorexia and prostration. At first there was evening rise of temperature with rigor which became

continuous in nature after three days. Having no definite diagnosis and physical improvement within short period of time patient himself left the hospital and visited a local physician who sent him to a local clinical laboratory asking for a blood examination for detection of malaria parasite with other relevant investigations. Blood smear microscopy of thick film revealed the presence of malaria parasite and the thin film showed *P malariae* of trophozoite form. Subsequent ICT Pf/Pv showed negative result. On the next day clinical investigations were again done in the dept of Microbiology of Chittagong Medical College for further confirmation. The thin blood film showed malaria parasite in trophozoite form with typical band form and merozoites. Only mature RBC was infected with no change in RBC size. Malaria parasite count found to be 550/mm³ of blood. ICT Pf/Pv (SD BIOLINE) again showed negative result whereas ICT Pan/Pf/Pv (Zephyr Biomedicals, Goa, India) was found positive which indicated the species were either *P malariae* or *P ovale*. Other laboratory parameters such as Haemoglobin, total and differential count of WBC, platelet count, serum creatinine and serum bilirubin were normal. Blood smear microscopy of malaria parasite with definite morphological resemblance with *P malariae* and a positive ICT Pan/Pf/Pv assay of same blood sample established the diagnosis as *P malariae* infection.

The patient was treated with oral quinine therapy and recovered rapidly.

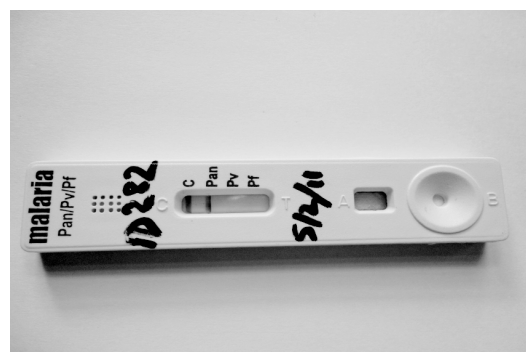

Fig 1: Immunochromatographic test -positive for *P. malariae/ovale*

✉ Correspondence:

Dr. Muhammad Ehsanul Haque
Lecturer,
Department of Microbiology,
Chittagong Medical College, Chittagong
Mob: 01819 375563
E-mail: ehkajol@yahoo.com

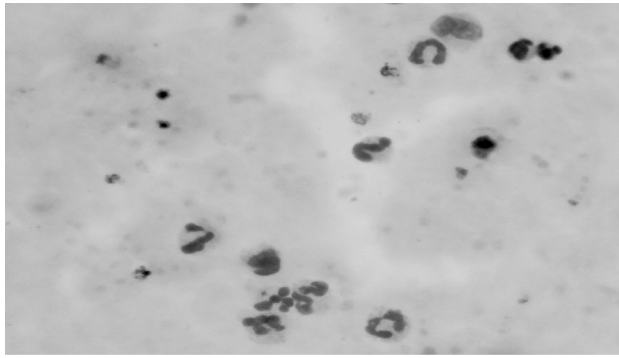


Fig II: Showing *P. malariae* in thick film

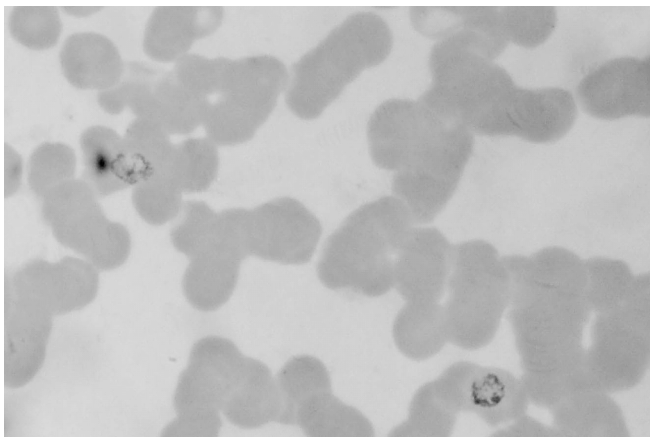


Fig III: Showing *P. malariae* in thin film

Discussion:

P. falciparum (malignant tertian malaria) and *P. malariae* (quartan malaria) are the most common species found in Asia and Africa³, but *P. malariae* infection has been reported rarely from Bangladesh⁴. So far only one case of PCR confirmed *P. malariae* infection has been reported from Bangladesh⁴. The present case has been diagnosed with the help of microscopy and ICT Pan/Pf/Pv assay. There was a delay in parasitological diagnosis due to the fact that the clinical presentations were more severe and atypical unlike *P. malariae* infection and much used ICT Pf/Pv assay was found negative. The classic quarternary pattern of fever for *P. malariae* infection was absent.

We performed these laboratory examinations in a tertiary care centre where laboratory set up and experienced microbiologists are available otherwise there is every chance of missing those cases if proper procedure has not been followed as early stages of *P. malariae* could be difficult to distinguish from other species by microscopy alone. In such kind of situation ICT Pan/Pf/Pv assay could be a good

alternative in addition to microscopic examination.

In summary, we report a rare case of *P. malariae* infection with severe illness. The patient made a rapid recovery with 7 days of oral quinine therapy.

Conclusion:

Though *P. malariae* is uncommon in this area but not absent. Proper laboratory diagnosis by trained personnel and newer immunochromatography kit may reveal the actual scenario. Moreover proper guideline for management of those rare malaria species at national level should be taken to avoid fatal complications.

References:

1. Mangold, K.A, Manson R.U, Koay S.C, Stephens L, Regner M.A, Thomson B.R., Peterson R.L, Kaul K.L. Real -Time PCR for detection and identification of plasmodium species. *J. Clin. Micro.* 2005; 43:2435-2440.
2. World Health Organization, Global burden of malaria WHO, 2005 [online]. [viewed 31/10/2007]. [Web http://www.unmillenniumproject.org/documents/Global_Burden_of_Malaria.pdf]
3. Ghaffer A, [online] Medical Microbiology and Immunology, University of South Carolina, [viewed 1/03/2011]. web <http://pathmicro.med.sc.edu/parasitology/blood-proto.htm>.
4. W. Rahman, K. Chotivanich, K. Silamut, N. Tanomsing, A. Hossain, M.A. Faiz, A.M. Dondorp, and R.J. Maude, 2010 *Plasmodium malariae* in Bangladesh, *Trans R Soc Trop Med Hyg*; 104(1): 78–80.