

Case Report

Acquired toxoplasmosis of a submental lymph node in a 14 year-old girl: case report.

Kazi Yesmin¹, Sahub Alam², Shahanara Begum¹, Farhana Afroze³, Hasina Iqbal⁴.

¹Department of Microbiology, Green Life Medical College. ²Department of ENT, UHC Shingair, Manikgong. ³Department of Pathology, Green Life Medical College. ⁴Department of Microbiology, Popular Medical College.

Introduction:

Toxoplasmosis is caused by *Toxoplasma gondii*, are of two types: congenital and acquired. Almost one-third of the population has been confronted to this protozoan¹. Infection of humans begins with the ingestion of tissue cysts in undercooked meat or from contact with cat feces. The infection also occurs by transplacental transmission or from ingestion of oocysts via soil (e.g. by way of gardening, handling or eating unwashed vegetables, or changing a cat litter box)².

There are very few current reports focused on the seroprevalence of toxoplasmosis. In a study from Northeast Nigeria, the sero-prevalence was found as 23.9% among 180 children screened by ELISA for *Toxoplasma gondii* specific IgG³. In Iraq, the seroprevalence of toxoplasmosis among wives and husband were 30.7% and 13.1% respectively⁴. In a recent study in France, a total of 273 people were tested for IgG- *Toxoplasma gondii* antibodies by ELISA and 47% were found positive⁵. The sero-prevalence of 15.33% and 24% has been revealed in pregnant women in India and Pakistan⁶⁻⁷ respectively. There are a few work on toxoplasmosis are done in Bangladesh. A study was carried out to determine the seroprevalence of *Toxoplasma gondii* among an antenatal population in a hospital of Bangladesh. About 38.5% and 1.1% were found positive for *toxoplasma* IgG antibody and *toxoplasma* IgM antibody respectively⁸. The sero-prevalence of *Toxoplasma gondii* was reported in adult women and domestic animals used for meat products from Mymensingh District, Bangladesh. Cattle, goats and sheep showed a high seroprevalence 12%, 32% and 40% respectively while all women in the same area were found seronegative⁹. Moreover,

the sero-prevalence of toxoplasmosis was found 15.89% in women with bad obstetric history in a tertiary care hospital at Mymensingh¹⁰. Epidemiological studies on *Toxoplasma gondii* infection were conducted in different group of populations at Mymensingh. Among the groups, 12.4% blood donors, 11.18% pregnant women, 50.00% butchers, 12.88% slaughtered goats and 33.33% cats had diagnostically significant antibody titers to *T. gondii*¹¹.

Immunocompetent adults are usually asymptomatic or may show symptom such as fever, malaise, fatigue and lymphadenopathy that resolve spontaneously¹². Lymphadenopathy is the most common manifestation in the 10 - 20% of immunocompetent individual. Most maternal infections are asymptomatic or manifested with mild disease¹³. Congenital toxoplasmosis occurs almost exclusively as a result of primary maternal infection during pregnancy. The diagnosis of *Toxoplasma gondii* infection or toxoplasmosis may be established by serological tests, amplification of specific nucleic acid sequences, histopathological demonstration of the parasite and/ or its antigens or by isolation of the organism¹⁴.

Case Report: A 14-years old girl presented with painless swelling in the submental region for five months. On examination, enlarged (1.5×1.0 cm), firm, non-tender and non-fixed lymph node in the submental region was found. Any other swelling or lymphadenopathy was not found in the patient. Overall systemic examination was normal. The lymph node was excised and examined histologically under the local anesthesia.

The histopathological examination of the lymph node showed reactive lymphadenitis. There are collection of epitheloid histocytes, some of them are within the secondary germinal centers. There was no evidence of caseous necrosis or malignancy in the node section. Subsequently serological test for antibodies of *Toxoplasma gondii* IgG and IgM were done by ELISA. The patient was found positive for both IgG and

✉ Correspondence:

- Dr. Kazi Yesmin
- Assistant Professor,
- Department of Microbiology
- Green Life Medical College
- E-mail: kyesmin@gmail.com
- Tel: +8801716063969

IgM antibodies. There was no history of association with pet cat. The diagnostic modalities including serologic test, was suggestive of acquired toxoplasmosis. The patient was treated with pyrimethamine and sulfadiazine for 3-4 weeks.

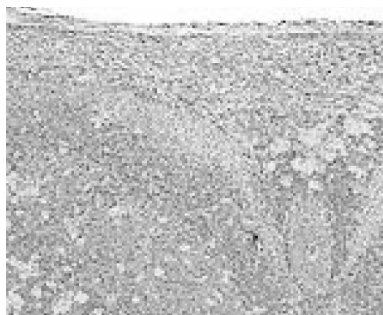


Figure: Lymph node showing the characteristic changes of toxoplasmosis (collection of epithelioid histiocytes, some of them are within the secondary germinal centers)

Discussion: *Toxoplasma gondii* is a protozoan parasite that infect up to a third of the world's population. Lymphadenitis is one of the frequently presenting sign of toxoplasmosis. In children, cervical lymph nodes are usually affected. We present a case of submental lymphadenopathy caused by *Toxoplasma gondii* in a girl suffered for five months without systemic involvement. There was no history of exposure to cat. Almost similar case of submental lymphadenitis by toxoplasmosis reported by Choi JS *et al* (2002) in Korea¹⁵ and by Takebe *et al* (1997) in Japan¹⁶. *Toxoplasma gondii* is acquired primarily through ingestion of cysts in infected, undercooked meat or oocysts that may contaminate soil, water and food. Drinking of unfiltered water increases the risk of *Toxoplasma gondii* seropositivity, indicating the potential importance of oocysts transmission by water¹⁷. Recent studies have identified water as a potential source of the infection in both human and animals¹⁸⁻²⁰. At least one hundred and ninety-nine outbreaks of human diseases due to the waterborne transmission of parasitic protozoa occurred and were reported in Australian continent, North America and Europe. Out of them, four outbreaks were caused by *T. gondii*²¹. In United States only 16% of people aged from 12 to 49 years have a positive serology for toxoplasmosis²². The sero-prevalence in developed countries is generally lower than that of developing countries because of improvement of hygiene condition and widespread freezing. Freezing meat at -20°C for 48 hours or heating to 50°C for 4 to 6 minutes kill the agents²³. Patient with lymphadenopathy due to *Toxoplasma gondii* should be treated effectively. In immunocompromised patients, reactivation of latent disease can cause life-threatening encephalitis and congenital transmission of *Toxoplasma gondii* to the fetus. Rarely,

reactivation of infection in immune compromised women during pregnancy can result in congenital toxoplasmosis.

Conclusion: When toxoplasmosis is suspected, it is important to emphasize that the patient may or may not be exposed to cats. If there is no history of exposure of the patient to cat possibility of transmission by ingestion of vegetables or water contaminated with oocysts may be taken into consideration.

Reference:

1. Nagaraja B, Ramana BV, Murty DS, Naidu BHV, Kailaanath RB. Prevalence of toxoplasmosis among antenatal women with bad obstetric history. *Int J Pharma Biosci* 2012; 1: 222-227.
2. Furtado JM, Winthrop KL, Butler NJ, Smith JR. Ocular toxoplasmosis: parasitology, epidemiology and public health. *Clin Experiment ophthalmol* 2012; 41: 82-94.
3. Kamani J, Mani AU, Egu GO, Kumshe HA. Seroprevalence of human infection with *Toxoplasma gondii* and the associated risk factors, in Maiduguri, Borno state, Nigeria. *Ann Trop Med Paraitol* 2009; 103: 317-321.
4. Mohanad M, Shehab A, Abudalla H. Seroprevalence of *Toxoplasma gondii* in couples in Ramadi City using ELISA. *IJMMS* 2012; 4: 55-59.
5. Fromont EG, Riche B, Rabilloud M. *Toxoplasma* in a rural population in France: detection of a household effect. *BMC infect Dis* 2009; 9: 76.
6. Khurana S, Bagga R, Agrawal A. Serological screening for antenatal *toxoplasma* infection in India. *Indian J Med Microbiol* 2010; 28: 143-146.
7. Haikh DM, Zafar MN, Ahmed E, Rizvi S, Hashim Y, Barakzai R. Seroprevalence of toxoplasmosis (By detecting IgM Antibodies) in women with Repeated Abortion. *JPM* 2013; 43: 214.
8. Ashrafunnessa, Khatun S, Islam MN, Haq T. Seroprevalence of *Toxoplasma* antibodies among the antenatal population in Bangladesh. *J Obstet Gynaecol Res* 1998; 24(2): 115-9.
9. Shahiduzzaman M, Islam R, Khatun MM, Batanova TA, Kitoh K, Takashima Y. *Toxoplasma gondii* seroprevalence in domestic animals and humans in Mymensing District, Bangladesh. *J Vet Med Sci* 2011; 73(10): 1375-6.

10. Samad MA, Begum N, Shamsunahar, Ahmed MU. Serological diagnosis of *Toxoplasma gondii* infection in women associated with gynaeco-obstetric problems. Southeast Asian J Trop Med Public Health 1993; 24(1): 102-6.
11. Samad MA, Dey BC, Chowdhury NS, Akhtar S, Khan MR. Sero-epidemiological studies on *Toxoplasma gondii* infection in man and animals in Bangladesh. Southeast Asian J Trop Med Public Health 1997; 28(2): 339-343.
12. Jones JL, Kruszon-Moran D, Wilson M, McQuillan G, Navin T, McAuley JB. *Toxoplasma gondii* infection in the United States: Seroprevalence and Risk Factors. Am J Epidemiol 2001; 154: 357-365.
13. Montoya JG, Remington JS, Mandel GL, Bennett JE, Dolin R. *Toxoplasma gondii*. In: Principles and Practice of Infectious Diseases, 5th Ed. Philadelphia: Churchill Livingstone 2000:2858-2888.
14. Remington JS, McLeod R, Thulliez P, Desmonts G, Klein J. Toxoplasmosis. In: Infectious Diseases of the fetus and newborn infant, 5th Ed. Philadelphia: W.B. Saunders 2001: 205-346.
15. Choi JS, Park YK, Ryu JS, Kim KS. A case of submental lymphadenitis by Toxoplasmosis. Korean J Otolaryngol-Head Neck Surg, 2002; 45(8): 828-830.
16. Takebe M, Yamada Y, Inoue Y, Matsukawa S, Chiba H, Kusama H. A case of atypical necrotizing lymphadenitis in the submental and submandibular regions. Japanese J Oral and Maxillofacial Surg, 1997; 43(6): 505-507.
17. Bahia-Oliveira LM, Jones JL, Azevedo-silva J, Alves CC, Orefice F, Addiss DG. Highly endemic, waterborne toxoplasmosis in north Riode Janeiro state, Brazil. Emerg Infect Dis 2003; 9: 55-6.
18. Bowie wR, King SA, werker DH, et al. Outbreak of toxoplasmosis associated with municipal drinking water. Lancet 1997; 350: 173-177.
19. Miller MA, Gardner IA, Kreuder C, et al. Coastal freshwater runoff is a risk factor for *Toxoplasma gondii* infection of southern sea otters. Int Parasitol 2002; 32: 997-1006.
20. De Moura L, Bahia.-Oliveira LM, wada MY, et al. waterborne toxoplasmosis, Brazil, from field to gene. Emerg Infect Dis 2006; 12: 326-9.
21. Baldursson S, Karanis P. Water-borne transmission of protozoan parasites: Review of worldwide outbreaks. An update 2004-2010. Water Research 2011; 45(20): 6603-6614.
22. Jone LJ, Kruszon-Moran D, Wilson M. *Toxoplasma gondii* infection in the United States, 1999-2000. Emerg Infect Dis 2003; 9: 1371-1374.
23. Kodjikian L. Toxoplasmsis and pregnancy. J Fr Ophthalmol. 2010; 33: 362-367.