

Case Report

Demodicosis: A Case Report

Chandan Kumar Roy¹, Md Shahadat Hossain², Ismet Nigar¹, Rehana Razzak Khan¹, SM Ali Ahmed¹

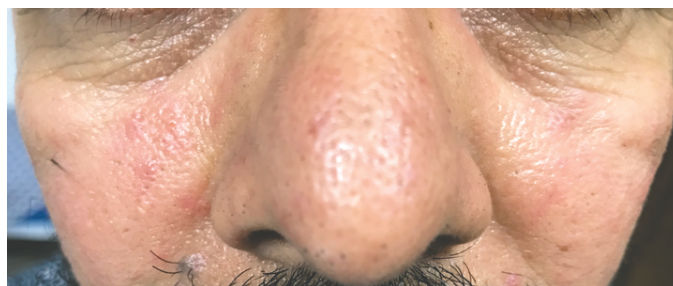¹Department of Microbiology and Immunology, Bangabandhu Sheikh Mujib Medical University, Dhaka, Bangladesh.

²Department of Dermatology and Venereology, Shaheed Suhrawardy Medical College, Dhaka, Bangladesh.

Demodex mite is a human ecto-parasite found in or near the pilo-sebaceous units of skin. *Demodex folliculorum* and *Demodex brevis* are two species typically found on humans. *Demodex* infestation usually remains asymptomatic in most of the cases and may have a pathogenic role only when present in high densities and in persons with immune imbalance. All pathological conditions caused by *Demodex* mites are termed demodicosis or demodicidosis, which can be an etiological factor of or resemble a variety of dermatoses. A high index of clinical suspicion about the etiological role of *Demodex* in various dermatoses can help in early diagnosis and appropriate, timely, and cost effective management¹. Demodicosis is one of the rare cutaneous infections affecting the face and eyelids. Usually pruritic, erythematous, maculopapular or papulopustular lesions characterize the clinical conditions. Demodicosis can have variable presentations, e.g., pityriasis folliculorum, rosacea-like demodicidosis, or demodicidosis gravis. Here, we present a case of facial demodicosis and describe its management².

A 48-year-old male presented with the chief complaint of itchy, red, maculopapular eruptions on the central part of the face for the last 06 months. He has been residing in Kingdom of Saudi Arabia (KSA) as an overseas Bangladeshi worker for last 26 years and working as a professional pastry chef for 19 years. During his holidays in Bangladesh in late 2019, he was attended to a dermatologist and clinically diagnosed as acne vulgaris and initially treated with oral Doxycycline and Azithromycin with topical Clindamycin. In the subsequent follow-up with no clinical improvement, he was send to the Department of Microbiology and Immunology of Bangabandhu Sheikh Mujib Medical University, Dhaka for laboratory

investigations to evaluate demodicosis. There was no history of photosensitivity or flushing episodes. There was no history of pet animals in the house. Routine general physical examination was found normal. On cutaneous examination, the central part of the face was mainly involved, with mild involvement of the external ear. The lesions were erythematous maculopapular eruptions with mild scaling. There were no telangiectasia, and hair, nail, eye, and mucosal surfaces were normal. Routine hematological examination was within normal limits. Sebum secretion was collected from naso-labial area and from lesions by scrapping and examined under light microscope after maceration with 20% KOH. No fungal elements were seen but adult *Demodex* mites were detected in moderate numbers. Subsequently, more skin surface scrapings were taken from different affected sites and almost all samples showed the elongated bodies of the *Demodex* mite (five or more in a single low-power field). With these findings, the diagnosis of demodicosis was confirmed and the patient was advised to apply topical benzyl peroxide on the lesions and also he was suggested avoiding sunlight. After a few days, the facial lesions started to subside gradually. Subsequent follow-up evaluations showed complete recovery and repeat skin scrapings were negative for *Demodex* mites.



Picture 01: Maculopapular lesions over the central part of face

Correspondence:

Chandan Kumar Roy

Associate Professor


Department of Microbiology and Immunology

Bangabandhu Sheikh Mujib Medical University

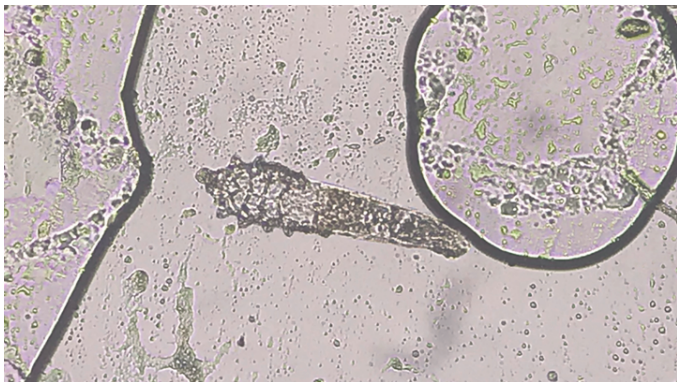
Shahbag, Dhaka, Bangladesh.

Mobile : 01711-381612

Email : chandon.roy@gmail.com



Photomicrograph 01: Adult *Demodex* mite in Phase contrast microscopy (Phase III-10X100 magnification)



Photomicrograph 02: Adult *Demodex* mite in light microscopy (10X40 magnification)

The causative organism of demodicosis is a saprophytic mite that usually resides in the human pilosebaceous unit. This mite belongs to family Demodicidae of class Arachnida in the order Acarina³. The infestation may be clinically inapparent but under certain circumstances these mites may multiply rapidly, leading to the development of different pathogenic conditions such as suppurative or granulomatous skin reactions resembling suppurative folliculitis, rosacea, or perioral dermatitis⁴.

The physiological role of human *Demodex* mites in healthy skin remains enigmatic, and the way in which they evade immune surveillance, especially the innate immune system, can be crucial for the understanding of human-parasite interactions. Induction of inflammation is the essential step in the pathogenesis. The proliferation of *Demodex* mites, activation of unknown virulence factors and the pathogenic role of endosymbionts in the mites are core issues that warrant intensive investigation. Clinical

distinction from other mimicking inflammatory dermatoses, such as papulopustular rosacea or perioral dermatitis, is important. Effective acaricidal drugs (e.g., Ivermectin) and their optimal dosage in killing *Demodex* mites remain to be determined and standardized. Advancement in this field is hampered by the lack of appropriate in vitro or in vivo models for experimental studies. Recognition of human demodicosis as a primary disease will promote further development of novel therapeutic strategies⁵.

To summarize, demodicosis should be considered in the differential diagnosis of recurrent or recalcitrant facial eruptions. Demodicosis is often misdiagnosed as rosacea owing to their similar presentations. Subtle differentiating clues may often be overlooked in a busy practice. Differentiating between the two entities is important as some treatment modalities for rosacea can aggravate demodicosis. Correct diagnosis, which is imperative for proper treatment, can only be made by finding extrafollicular *Demodex* mites in the KOH microscopic examinations, skin surface biopsy, skin biopsy specimens, or a combination of these.

Conflict of interest: None

Funding agency: None

References

1. Rather PA, Hassan I. Human demodex mite: the versatile mite of dermatological importance. Indian journal of dermatology. 2014 Jan;59(1):60.
2. Kaur T, Jindal N, Bansal R, Mahajan B. Facial demodicosis: A diagnostic challenge. Indian journal of dermatology. 2012;57(1):72.
3. Burns DA. Follicle mites and their role in disease. Clinical and experimental dermatology. 1992 May;17(3):152-5.
4. Hsu CK, Hsu MM, Lee JY. Demodicosis: a clinico-pathological study. Journal of the American academy of dermatology. 2009 Mar 1;60(3):453-62.
5. Chen W, Plewig G. Human demodicosis: revisit and a proposed classification. British journal of dermatology. 2014 Jun;170(6):1219-25.