

Original article:

The occurrence of C-shaped root canal in Malaysian population

Nie YK¹, Bakar WZW², Alam MK³

Abstract

Background: The recognition of unusual canal's configurations and variations are essential for successful endodontic diagnosis and treatment. This study was aimed to investigate the occurrence of C- shaped root canal in Malaysian population. **Design:** This is an *in vitro* study whereby 241 extracted human first and second molars with intact root were collected from several dental clinics in Malaysia. **Materials and Methods:** The roots were sectioned at three levels: subpulpal level, 3mm from apical tip and middle level between the first and last level. The appearance of the root canal sections were assessed using stereomicroscope (Leica, Germany) and pictures were taken. Data were analyzed statistically using Fisher's Exact and Binomial test with $p < 0.05$ indicates statistically significant difference. **Results:** The occurrence of C- shaped canal among molars collected is 3.73%. Hundred percent of the molars with C- shaped root canal configuration are mandibular molars and 77.8% are belonged to Chinese racial. **Conclusion:** The findings show that C- shaped root canals do occur among Malaysian people especially Chinese racial. Besides, all the teeth that possess C- shaped root canal configuration are lower molars.

Key words: occurrence, C- shaped, canal configuration

Introduction

The study of root anatomy of teeth has an endodontic as well as anthropological significance. A successful endodontic treatment very much depends on endodontist's ability to recognize unusual root canal anatomy, successful intra-radicular reproduction, obturation and so on¹. Most of teeth have shown accessory canals, multiple foramina, fins and deltas. In 1984, Vertucci also reported that the clinician must treat the tooth by assuming there is presence of accessory root canals unless proven otherwise².

A great deal of variations can present especially the canal configuration of mandibular second molar. Mandibular second molars usually have two roots and three root canals but variations in the number of roots as well as canal morphology are not uncommon. In 1979, Cooke and Cox first described the term C-shaped root canal³. They reported three cases where the root canals were like the English capital letter 'C', in which canals were connected by a continuous slit. C-shaped canals are commonly found in permanent mandibu-

lar second molars but they can also be found in maxillary first molars, maxillary second molars, and mandibular first and second premolars, third molars and mandibular first molars⁴⁻⁷. The mandibular second molars with C-shaped root canals vary in their configurations and many methods have been used to classify such canals².

C-shaped root canal was classified into 3 categories by Melton (1991) which were: Type I that is continuous C-shaped canal; Type II that is emicolon-shaped canal, orifice in which dentine separates a main C-shaped canal from one mesial distinct canal, and Type III which is 2 or more separate canals.

The shape and the number of roots are determined by Hertwig's epithelial sheath, which bends in a horizontal plane below the amelocemental junction and fuses in the centre leaving openings for roots⁹. Fused roots may form either by coalescence owing to cementum deposition with time, or as a result of failure of Hertwig's epithelial sheath to develop or

1. Yeap Kian Nie, School of Dental Science, University Sains Malaysia.
2. Wan Zaripah Wan Bakar, Senior Lecturer, School of Dental Science, University Sains Malaysia., wzaripah@kb.usm.my
3. Mohammad Khursheed Alam, Senior Lecturer, School of Dental Science, University Sains Malaysia., dralam@gmail.com, dralam@kk.usm.my

Corresponds to- Wan Zaripah Wan Bakar, Senior Lecturer, School of Dental Science, University Sains Malaysia., email: wzaripah@kb.usm.my

The occurrence of C-shaped root canal in Malaysian population

fuse in the furcation area¹⁰. A C-shaped canal appears when fusion of either the buccal or lingual aspect of the mesial and distal roots occurs. This fusion remains irregular and the two roots stay connected by an interradicular ribbon¹¹. The pulp chamber has a single ribbon-shaped orifice with a 180° arc from the distal to mesial canal¹². The floor of the pulp chamber is deep and has an unusual anatomical appearance¹¹. Two or three canals may be found in the C-shaped groove, or the C-shape may be continuous throughout the length of the root.

This study was undertaken to determine the frequency of C-shaped root canals in Malaysian population as there is no study has been reported. It is important to be familiar with variations in tooth anatomy and characteristic features in various racial groups since such knowledge can aid location and negotiation of canals, as well as their subsequent management.

Result of this study could give an overview of how regular the occurrence of C-shaped canal in Malaysia, and therefore dentist can take early strategies and improve the technique to maximize the rate of success.

Materials and Methods

A total numbers of 241 extracted molars which follow the criteria were collected from several dental clinics of several states in Malaysia in this *in vitro* study. The inclusion criteria was first and second maxillary and mandibular extracted human molars with an intact root, and the exclusion criteria was teeth with fractured or broken root. Sample size was calculated with standard deviation of 11.87 following previous similar study by Jafarzadeh and Wu (2007) with conventional Z value of 1.96 for 95% confidence interval¹³.

Teeth collected were cleaned using scalers and kept in 0.1% Thymol solution¹⁴. Roots for each tooth were sectioned at three levels: subpulpal level, 3mm from apical tip and middle level between the first and last level and pictures were taken using stereomicroscope (Leica, Germany). The presence of C-shaped canal was determined by two independent examiners. Data were collected and was analyzed for report writing using SPSS

version 17.0 (SPSS Inc, 2008). All statistical analysis was conducted using using Fisher's Exact and Binomial test with $p < 0.05$ indicates statistically significant difference. Ethical consideration was obtained from the Human Research & Ethics Committee of USM (USMKK/PPP/JEPeM [213.3(15)]).

Results

In this study, 241 extracted molars were sectioned and assessed. Table 1 revealed the frequency of molars with C-shaped canal configuration. It was found that occurrence of C-shaped canal was 9 cases (3.74%) and all were found in mandibular molars (100%). Majority are found in lower second molars with 8 cases (3.32%) or 88.8% of total number of molars having C-shaped canal and this is statically significant. All the C-shape canal observed are continuous from the first level to the third level.

Table 1: Frequency and percentage of teeth with C-shaped canal configuration

Teeth	Frequency (n=241)	Percentage (%)
16, 26	0	0.00
17, 27	0	0.00
36, 46	1	0.42
37, 47	8	3.32
Total	9	3.74

Table 2: Frequency of C-shaped canal by racial

Table 2: Frequency of C-shaped canal by racial

Race	Frequency	Percentage (%)
Malay	1	11.1
Chinese	7	77.8
India	0	0.0
Others	1	11.1
Total	9	100.0

As shown in Table 2, most of the C-shaped canal were found in Chinese racial with 7 cases (77.8%) out of total 9 cases, followed by Malay and others racial with 11.1% respectively. Table 3 shows that C-shaped canal is statistically significant to be more commonly found in the Chinese racial than the non-Chinese racial.

Table 4 showed that there is almost equal occurrence of C-shaped canal among the different age group. In other words, there is no significant relationship between C-shaped canal and the age group they were found in.

Table 3: Comparison of the occurrence of C-shaped canal in Chinese and non-Chinese population

Frequency = f; Percentage = %

The occurrence of C-shaped canal	Chinese		Non-Chinese		Total	
	f	%	f	%	f	%
Yes	7	14.58	2	1.04	9	3.73
No	41	85.42	191	98.96	232	96.27
TOTAL	48	100.00	193	100.00	241	100.00

Table 4: Frequency of C-shaped canal by age

Age	Frequency	Percentage (%)
< 16	0	0.0
16-30	2	22.2
31-45	3	33.3
46-60	2	22.2
> 60	2	22.2
Total	9	100.0

Table 5: Frequency of different types of C-shaped canal

Type of C-shaped canal	Frequency	Percentage (%)
Type I	2	22.2
Type II	3	33.3
Type III	4	44.4
Total	9	100.0

All the three types of C-shaped canal were observed (Figure 1, 2 and 3) and frequency was shown in Table 5. Type III has the highest frequency which is 4 cases (44.4%), followed by Type II (33.3%) and lastly Type I (22.2%).

Discussion

The report of teeth with C-shaped canal has drawn attention of dental practitioner especially endodontist due to the lower success rate of root canal therapy. Clearly, the root canal anatomy cannot always be predicted, and this can be the source of failure. A solid understanding of the tooth anatomy including the number and course of various root canals represents the basic for successful endodontics therapy.

In the present study, the total occurrence of C-shaped canal among the 241 extracted human molars is 9 cases or 3.73%. The low percentage of occurrence can be explained by inclusion of all the molars, which is both maxillary and mandibulars in this study to prevent bias, although Bolger (1988) reported that it is only common to be found in mandibular second molars¹⁵. Nevertheless, 100% of C-shaped canals were only found in lower

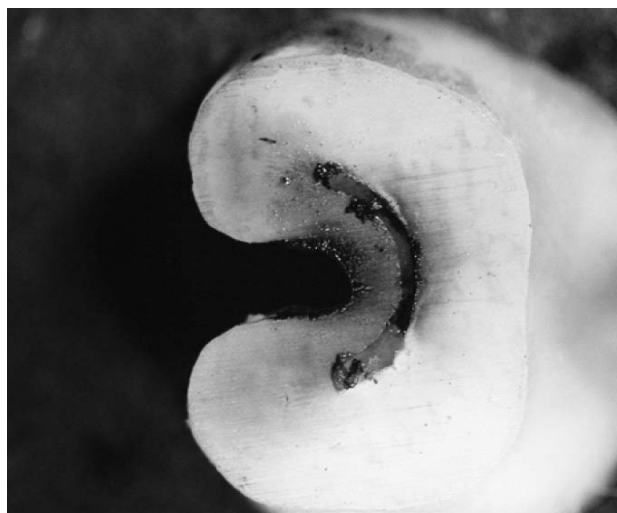

Figure 1: Example of Type 1 (continuous C-shaped canal)




Figure 2: Example of Type II (semicolon-shape C-shaped canal)

molars with fused root which may form either by coalescence owing to cementum deposition with time, or as a result of failure of Hertwig's epithelial sheath to develop fusion in the furcation area¹⁰. C-shaped canal appears when fusions of either the buccal or lingual aspect of the mesial and distal roots occur. These fusions remains irregular, and two roots stay connected by an interradicular rib-

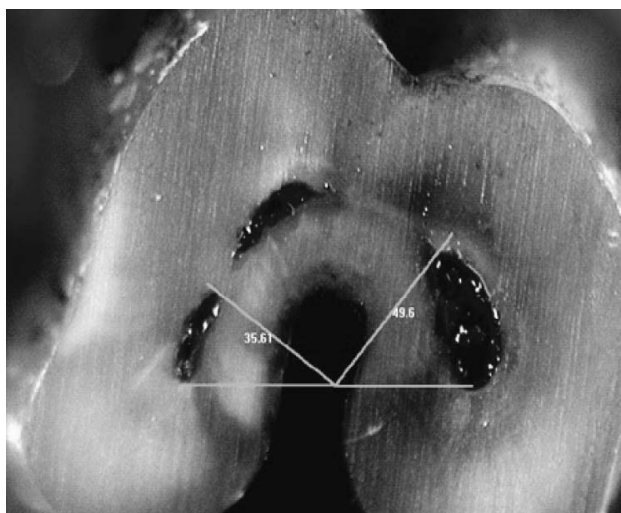


Figure 3: Example of Type III (C-shaped canal with two or more separate canals)

bon¹¹.

Apart from that, there is a very high occurrence in Chinese racial, that is 14.6%, compare to that of non-Chinese racial, 1.04% and among the C-shaped canal that were found, there are 7 out of 9 cases or 77.8% in Chinese racial, and this finding is consistent with what reported in previous study by Yang *et al.* (1988) where high prevalence of C-shaped canal was found in Chinese population in study conducted in China¹⁶.

Present study also showed almost equal occurrence of C-shaped canal among different age group. There is also no statistically significance between the occurrence and age group which implies that age is not a strong determinant on occurrence of C-shaped canal. This is also consistent with what

reported by Zheng *et al.* (2011) that the prevalence of C-shaped canal did not differ with age¹⁷.

All three types of C-shaped canals were found in this study, which were by Type I (continuous C-shape canal); Type II (semicolon-shaped canal) and Type III (comprises 2 or more separate canals) as mentioned by Melton *et al.* (1991). Among these three types, Type III has the highest frequency and followed by Type II and lastly Type I⁸. Melton also commented on the large amount of debris in instrumented canal space found in histological sections of these teeth, for which many authors agree on using ultrasonic files to facilitate their removal. Accordingly, ultrasonic irrigation with 1.26% sodium hypochlorite and 17% EDTA was used alternatively to remove the smear layer and to enhance the penetration of the plasticized gutta percha.

Conclusion

The findings from this study demonstrated that C-shaped root canals do occur among Malaysian people, and is more commonly to be found in the Chinese population compare to other races. Besides, all the teeth that possess C-shaped root canal configuration are lower molars. Hence, such unusual configuration of the root canal should be recognized earlier and precaution or referral to endodontist should be made.

Acknowledgement

This research was supported by Universiti Sains Malaysia's short term grant (304/PPSG/61311041).

References

1. Howlader TH, Alam MK, Sultana A. Efficacy of silicone as a dowel impression material. *Bangladesh Journal of Medical Science*. 2012; **11**(4): 331-334. <http://dx.doi.org/10.3329/bjms.v11i4.12614>
2. Vertucci FJ. Root canal anatomy of the human permanent teeth. *Oral Surg Oral Med Oral Pathol* 1984; **58**: 589-99. [http://dx.doi.org/10.1016/0030-4220\(84\)90085-9](http://dx.doi.org/10.1016/0030-4220(84)90085-9)
3. Cooke HG, Cox FL. C-shaped canal configurations in mandibular molars. *J Am Dent Assoc* 1979; **99**: 836-9. PMID:290680
4. Yilmaz Z, Tuncel B, Serper A, Calt S. C-shaped root canal in maxillary first molar a case report. *Int Endod J* 2006; **39**:162-6. <http://dx.doi.org/10.1111/j.1365-2591.2006.01069.x> PMID:16454798
5. Baisden MK, Kulild JC, Weller RN. Root canal configuration the mandibular first premolar. *J Endod* 1992; **18**: 505-8. [http://dx.doi.org/10.1016/S0099-2399\(06\)81352-X](http://dx.doi.org/10.1016/S0099-2399(06)81352-X)
6. Sikri VK, Sikri P. Mandibular premolars: aberrations in pulp space morphology. *Indian J Dent Res* 1994; **5**: 9-14. PMID:9495145
7. Gulabivala K, Opananon A, Ng YL, Alavi A. Root and canal morphology of Thai mandibular molars. *Int Endod J* 2002; **35**:56-62. <http://dx.doi.org/10.1046/j.1365-2591.2002.00452.x> PMID:11853239
8. Melton DC, Krell KV, Fuller MW. Anatomical and histological features Of C-shaped canals in mandibular second molars. *J Endod* 1991; **17**: 384-8. [http://dx.doi.org/10.1016/S0099-2399\(06\)81990-4](http://dx.doi.org/10.1016/S0099-2399(06)81990-4)
9. Orban B, Mueller E. The development of bifurcation of multirrooted teeth. *JADA* 1929; **16**: 297-19.
10. Pederson PO. The East Greenland Eskimo dentition: Numerical variations and anatomy. Bianco Lunos Bogtrykkeri, Copenhagen 1949. PMID:15407471
11. Barnett F. Mandibular molar with C-shaped canal. *Dent Traumatol* 1986; **2**: 79-81. <http://dx.doi.org/10.1111/j.1600-9657.1986.tb00131.x>
12. Cohen S, Burns R. Pathways of the pulp. *St. Louis, Mosby* 1994; 184-9. PMID:1294422
13. Jafarzadeh H and Wu YN. *The C-shaped root canal configuration: A review of J Endod* 2007; **33**: 517-23.
14. Glavicic S, Anic I, Braut A, Miletic I, Borcic J. Vertical force and torque analysis during mechanical preparation of extracted teeth using hand Pro Taper instruments. *Aust. Endod J*;no.doi:10.1111/j.17474477.2010.00252.x.
15. Bolger WL, Schindler WG. A mandibular first molar with a C-shaped root configuration. *J Endod* 1988; **14**: 515-9. [http://dx.doi.org/10.1016/S00992399\(88\)80110-9](http://dx.doi.org/10.1016/S00992399(88)80110-9)
16. Yang ZP, Yang SF, Lin YC, Shay JC, Chi CY. C-shaped root canals in mandibular second molars in a Chinese population. *Endod Dent Traumatol* 1988; **4**: 160-3. <http://dx.doi.org/10.1111/j.1600-9657.1988.tb00315.x> PMID:3267526
17. Zheng Q, Zhang L, Zhou X, Wang Q, Wang Y, Tang L, Song F, Huang D. C-shaped root canal system in mandibular second molars in a Chinese population evaluated by cone-beam computed tomography. *Int Endod J* 2011; **44**: 857-862. <http://dx.doi.org/10.1111/j.1365-2591.2011.01896.x> PMID:21599707
18. Howlader TH, Alam MK, Sultana A. Efficacy of silicone as a dowel impression material. *Bangladesh Journal of Medical Science*. 2012; **11**(4): 331 334. <http://dx.doi.org/103329/bjms.v11i4.12614>