

Case report

Right non recurrent laryngeal nerve associated with anomalous origin of right subclavian artery and a bicarotid trunk

Maruthupandian.D¹, Karunakaran.K², Arul V³*

Abstract:

Non recurrent laryngeal nerve is a rare anatomical variation with an incidence in literature of 0.3 % to 1.6 % on the right side. This variation places the nerve at risk of inadvertent injury during head and neck surgeries. Awareness about this abnormality and meticulous dissection of the nerve in every case is the only way to stay safeguarded. Here we present a case of right non recurrent laryngeal nerve in a 32 years old female patient who underwent near total thyroidectomy for nontoxic multi nodular goitre. During surgery, the right recurrent laryngeal nerve could not be identified in its normal location. Further dissection revealed a non recurrent laryngeal nerve arising from the vagal trunk. A CT angiogram was done post operatively and showed an anomalous origin of the right subclavian artery as the last branch of the aortic arch and a bi-carotid trunk. Every surgeon operating on the neck should be aware of and anticipate this variation of the recurrent laryngeal nerve especially when the nerve cannot be identified in the normal location.

Key words: non recurrent laryngeal nerve; thyroidectomy; multi nodular goitre; anomalous right subclavian artery; nerve injury; carotid trunk

Bangladesh Journal of Medical Science Vol. 15 No. 03 July'16. Page : 485-487

Case report:

A 32 yr old female presented with a swelling in front of the neck .clinical examination showed a thyroid swelling with multiple palpable nodules in both lobes which were firm in consistency and had no retro sternal extension. There were no palpable cervical lymph nodes. An USG of neck confirmed this findings. The patient was clinically and biochemically euthyroid. FNAC was consistent with nodular goiter. On direct laryngoscopy vocal cord function was normal bilaterally. With the diagnosis of euthyroid multinodular goitre the patient was posted for near total thyroidectomy. During thyroidectomy the recurrent laryngeal nerve could not be identified in its usual location. Instead there was a white cord like structure transversing parallel to and between the branches of the inferior thyroid artery. This structure was traced laterally in to the carotid sheath and was found to arise from the right vagal trunk. Medially this structure

was found to enter the crico thyroid membrane and hence identified to be non recurrent laryngeal nerve. Thyroidectomy was completed and the recurrent laryngeal nerve on the left side had a normal course.

The postoperative period of the patient was uneventful and a vocal cord examination showed equal movement on both sides. A CT angiogram done retrospectively revealed an anomalous origin of a right subclavian artery as the last branch of the aortic arch. This artery crossed from left to right posterior to the esophagus. Moreover the right and left common carotid artery originated from the aortic arch as a common trunk (bicarotid trunk) which was the first branch of the aortic arch. A normal left subclavian artery arose between the bicarotid trunk and the anomalous right subclavian artery. The patient did not have any difficulty in swallowing (dysphagia lusoria) on retrospective questioning.

1. D Maruthupandian, Professor, Department of General Surgery, Madurai Medical College, Madurai.
2. K Karunakaran, Assistant Professor, Department of General Surgery, Madurai Medical College, Madurai.
3. V Arul, Post Graduate, Department of General Surgery, Madurai Medical College, Madurai.

Corresponds to: V Arul, Post Graduate, Department of General Surgery, Madurai Medical College, Madurai. India. **E-mail:** arulmbbs@gmail.com

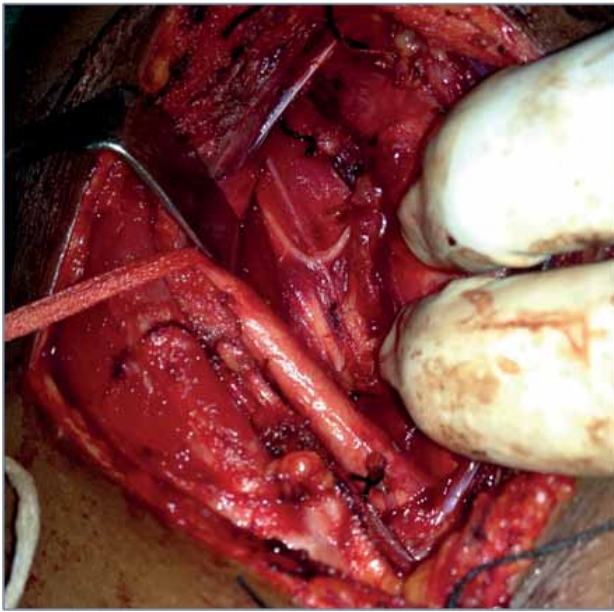


Fig 1: Intraoperative photograph showing right non recurrent laryngeal nerve.

Discussion:

During embryological development, the series of mesodermal thickenings called the pharyngeal arches develop in between the future mouth (stomatodeum) and the pericardium to form the neck. In the process, the developing heart with the great vessels descends into the thorax. The recurrent laryngeal nerve (RLN) is the nerve of the 6th pharyngeal arch and lies caudal to the artery of this arch. During the descent of the heart, the RLN is dragged downwards into the thorax by the developing great vessels. The nerve thus has to follow a recurrent course into the larynx. On the left side the nerve lies under the ligamentum arteriosum (remnant of the left 6th arch artery). However, the distal part of the right 6th arch artery and the 5th arch artery disappears. Hence the nerve comes to lie under the right subclavian artery (4th arch).

In Anomalous origin of the right subclavian artery, the right 4th arch artery fails to develop. Hence the inferior laryngeal nerve (synonymous with RLN normally) is not recurrent on the right side, but passes directly to the larynx without being drawn down as a loop by the subclavian artery. In this condition the anomalous right subclavian artery develops from the distal part of the right dorsal aorta and hence arises from the descending portion of the aortic arch as its last branch. In such cases the anomalous artery usually crosses from the descending aorta on the left to the right side

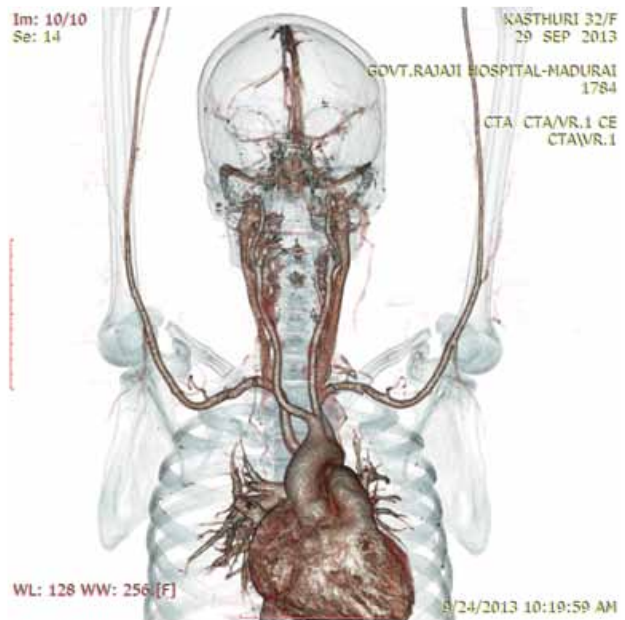


Fig 2: Reconstructed image CT angiogram seen from anterior aspect. Reconstructed image CT angiogram seen from posterior aspect.

of the body. During this part of its course, the artery usually lies posterior to the esophagus and may compress it producing dysphagia in 5% cases (dysphagia lusoria davidbayford 1789).

The recurrent laryngeal nerve on the right side originates from the vagus nerve where it crosses the right subclavian artery and loops around it before ascending in the trachea oesophageal groove, the nerve may branch before it enters the larynx at the cricothyroid membrane. The nerve lies in close proximity to the branches of the inferior thyroid artery and the parathyroids. The superior parathyroid lies dorsal to the nerve and the inferior parathyroid ventral. The identification of the nerve during thyroidectomy is facilitated by mobilising a prominence on the posterolateral border of the thyroid gland called the tubercle of zuckerkandle. The recurrent laryngeal nerve has mixed motor, sensory and autonomic nerve supply. It supplies all laryngeal muscles except for cricothyroid which is innervated by the external branch of superior laryngeal nerve. It also provides sensory supply to the larynx below the level of the glottis. Unilateral paralysis of the RLN causes the ipsilateral vocal cord to lie in a medial position or just lateral to the midline. A normal, although weakened voice may be present due to compensation by the contralateral cord. If the vocal cord remains paralysed in an abducted position a severely impaired voice and an ineffectual cough may result. Bilateral RLN injury causes complete loss of voice or airway obstruction

necessitating emergency tracheostomy.

Conclusion:

There are two main types of nonrecurrent laryngeal nerve described. Type 1 – nerve arises directly from the cervical vagus and runs together with the vessels of the superior thyroid pedicle. Type 3 – it follows a transverse path parallel to the inferior thyroid artery (further subdivided into Type 2 A when it turns over the trunk and Type 2B when it runs under the trunk or between the branches of the artery).

The incidence of nonrecurrent laryngeal nerve quoted in literature ranges from 0.3 – 1.6 % on the right

side and approximately 0.04 % on the left side.

The anomalous origin of the right subclavian artery appears in the general population with an incidence of 0.1 to 4%. The incidence of ARSA combined with bicarotid trunk varies from 0 – 2.5%.

Every surgeon operating on the neck should be aware of and anticipate this variation of the recurrent laryngeal nerve especially when the nerve cannot be identified in the normal location. Visualisation of the recurrent laryngeal nerve in every case is the only way to remain safeguarded and prevent inadvertent injury.

Conflict of interest: None

References:

1. Efficient, effective, safe procedure to identify non-recurrent inferior laryngeal nerve during thyroid surgery. Watanabe A, Taniguchi M, Kimura Y, Ito S, Hosokawa M, Sasaki S. *Head Neck*. 2014 Dec 9. doi: 10.1002/hed.23932.
2. Medially placed vagus nerve in relation to common carotid artery: a pointer to a non-recurrent laryngeal nerve. Sagayaraj A, Deo RP, Merchant S, Mohiyuddin SM, Nayak AC. *Eur Arch Otorhinolaryngol*. 2014 Sep 23.
3. Clinical relevance and surgical anatomy of non-recurrent laryngeal nerve: 7 year experience. Dolezel R, Jarosek J, Hana L, Ryska M. *Surg Radiol Anat*. 2014 Sep 9.
4. The nonrecurrent laryngeal nerve: anatomic and electrophysiologic algorithm for reliable identification. Kamani D, Potenza AS, Cernea CR, Kamani YV, Randolph GW. *Laryngoscope*. 2015 Feb;125(2):503-8. doi: 10.1002/lary.24823.
5. Characteristic travelling patterns of non-recurrent laryngeal nerves. Hong KH, Park HT, Yang YS. *J Laryngol Otol*. 2014 Jun;128(6):534-9. doi: 10.1017/S0022215114000978.
6. Right-sided aortic arch with anomalous origin of the left subclavian artery: case report. Vučurević G, Tanasković S, Ilijevski N, Kovačević V, Kecmanović V, Radak D. *Srp Arh Celok Lek*. 2011 Sep-Oct;139(9-10):666-8. Serbian
7. Right Nonrecurrent inferior laryngeal nerve and arteria lusoria: the diagnostic and therapeutic implication of anatomic anomaly. C.avisse, C.marcus, J.F.Delattre, C.Marcus, J.P.Cailliez – tomasi, J.P.Palet, V.Ladam-Marcus, B.Menenteau, J.B.Flament. issue 3 , PP-227-232, S.I: surgical and radiological anatomy, vol. volume 20
8. Identification of the non recurrent laryngeal nerve during thyroid surgery: 20 years experience. Toniato A, Mazzarotto R, Piotto A, Et al, S.I.: world jsurg, 2004 jul.28 (7): 659-61
9. Sadler, Thomas W, Langman's Medical Embryology 10th edition. S.I : Lippincott Williams & Wilkins, 2006
10. Singh Inderbir, Human Embryology 9th edition. S.I : Macmillan, 2012.