

## **Case report**

### **Treatment of Angle class I malocclusion with severe crowding by extraction of four premolars: A case report**

*Alam MK<sup>1\*</sup>, Nowrin SA<sup>2</sup>, Shahid F<sup>3</sup>, Haque S<sup>4</sup>, Imran A<sup>5</sup>, Fareen N<sup>6</sup>, Sujon MK<sup>7</sup>, Zaman S<sup>8</sup>, Islam R<sup>9</sup>, Nishi SE<sup>10</sup>*

#### **Abstract**

**Aims:** To correct the Angle class I malocclusion with crowding via four premolar extractions.

**Presentation of case:** A 19-year-old Malaysian female presented with the bimaxillary protrusion, crowding, high canines, midline deviation and edge-to-edge anterior bite. Upper lateral incisors were palatalized and in crossbite interactions with the opposite teeth. **Discussion:** Treatment was initiated using fixed orthodontic appliances followed by four 1<sup>st</sup> premolar extractions in both arches. Case was finished with good inter cuspatation of the upper and lower teeth. Molars were finished in a Class I relationship with canine guidance, and ideal overjet and overbite were obtained. **Conclusion:** Successful finishing of a case with beautiful smile, obtained proper overjet and overbite, corrected cross bite, midline shifting and the improved soft tissue profile.

**Keywords:** *Class I malocclusion; premolar extraction; crowding; orthodontic treatment.*

*Bangladesh Journal of Medical Science Vol. 17 No. 04 October '18. Page : 683-687*

*DOI: <http://dx.doi.org/10.3329/bjms.v17i4.38339>*

#### **Introduction**

Due to increased consciousness regarding facial appearance, aesthetic treatment has become very common practice these days. As anterior teeth come first during smile, aesthetic alignment of anterior teeth is very important in every orthodontic treatment. Any misplacement or irregularity in this area causes most patients to pursue orthodontic treatment.

More important than the different types of procedure or the philosophies of treatment, the types and degree of malocclusion, the patient's age, the patient's desires, and the skill of the orthodontists are the most influential in the outcome of the procedure<sup>1</sup>. The incident of malocclusion commonly occurs in equal or greater rate in adults than in children or adolescents. Among all malocclusions, crowding

is the most common complication in adults, and is found in around 24% of females and 14% of males<sup>2</sup>. It mainly occurs when there is misbalance among supporting bony structures and tooth size mass. Choice of treatment for crowding depends on age, affected jaw and the severity of crowding. To achieve best results, it is important to decide how we manage each case of crowding. The problem may be solved by extracting teeth in both arches<sup>3</sup> or without extraction<sup>4</sup>. The degree of the malocclusion and the number of teeth extracted also affect the treatment duration<sup>5</sup>.

The present case describes orthodontic treatment in a patient with Class I malocclusion with severe crowding in the anterior region and dental midline deviation, treated with four premolar extractions.

1. Mohammad Khursheed Alam, Orthodontic Department, College of Dentistry, Jouf University, Sakaka, Saudi Arabia.
2. Shifat A Nowrin
3. Fazal Shahid
4. Sanjida Haque
5. Anas Imran
6. Nashid Fareen
7. Mamun Khan Sujon
8. Shaila Zaman
9. Rafiqul Islam
10. Shamima Easmin Nishi  
Orthodontic Unit, School of Dental Science, Universiti Sains Malaysia, Kota Bharu, Malaysia.

**Correspondence to:** Mohammad Khursheed Alam, Orthodontic Department, College of Dentistry, Jouf University, Sakaka, Saudi Arabia. E-mail address: [dralam@gmail.com](mailto:dralam@gmail.com), Email: [xyz@abc.com](mailto:xyz@abc.com)

### **Case report**

The subject was a 19-year-old female, she came for treatment because she was concerned about the severe crowding of her anterior teeth with dental midline deviation. The patient had no other medical history. Clinical examination showed severe crowding in both upper and lower arches in the anterior region. As the arch-length deficiencies were present 12 mm in the maxillary arches and 10 mm in the mandibular arch. Both upper lateral incisors were palatally positioned and in a crossbite relationship with the opposite teeth. The patient had the bimaxillary protrusion with Class I molar relationships on both sides with edge-to-edge bite in the anterior region. The midline of the upper dental arch coincided with the facial midline but the midline of the lower arch had shifted to the left about 4mm. There were no clinical signs of clicking or discomfort in the temporomandibular joints or any restriction or deviation in jaw movement. No pathologic findings were detected on the panoramic radiograph. Lateral cephalometric analysis revealed a skeletal Class I skeletal relationship (Figure 1).

### **Treatment planning**

According to the information gathered from both clinical examination and diagnostic records, it was planned to relieve the maxillary and mandibular crowding with fixed appliance along with extraction of all first premolars.

The problems list was concisely as follows:

- (1) Bimaxillary protrusion with Angle Class I molar relationship with high canine,
- (2) severe tooth crowding in the upper dental arch and moderate tooth crowding in the lower dental arch in anterior region,
- (3) edge to edge anterior bite,
- (4) buccally placed upper and lower canines,
- (5) crossbites of the upper right and left lateral incisors,
- (6) lower dental midline deviated about 4 mm to the left side.

The patient was identified as having an angle Class I malocclusion and a skeletal Class I jaw base relationship with severe crowding in the anterior region of both arches.

The treatment objectives were to correct the crowding and crossbite to improve the facial profile.

The treatment plan was suggested as follows: (1) extraction of the upper and lower first premolar teeth, (2) alignment of the upper and lower teeth with preadjusted edgewise appliances, (3) retention with the upper and lower removable retainers.

### **Treatment progress**

Prior to the extractions, scaling was done and an impression was taken for the study model. Six weeks after that all first premolars were extracted, the treatment was started with bonding of brackets and buccal tubes using 0.022 slots preadjusted edgewise brackets, MBT (McLaughlin, Bennett, and Trevisi) prescription. Anchorage control is fundamental to successful orthodontic treatment. Orthodontic tooth movement has always been limited to action-reaction reciprocal force mechanics in anchorage control. The current case was managed with the conventional anchorage system as the present case was of bimaxillary protrusion with rare observation of crowding in the anterior segment. As well as the arch-length deficiencies were present 12 mm in maxillary arch and 10 mm in the mandibular arch. By the extraction of all first premolars the gained spaces were 14.15mm and 13.87mm in maxillary and mandibular respectively. The intramaxillary anchorage with the wire bendings were used to prepare the anchorage<sup>6</sup>. As the case form lateral cephalogram evaluation is of bimaxillary protrusion, no anchorage was burned. After leveling rotation rectification, a 0.017 × 0.025 inch heat activated NiTi arch was interleaved, followed by 0.017 x 0.025 Stainless steel. The space closure was finally done on 0.019 × 0.025 inch stainless steel arch wire using NiTi coil springs. The crossbite of the right lateral incisor region were corrected by raising the occlusion with bite blocks for two weeks. During several visits, different types of elastics were also given for proper occlusion and to correct the midline deviation. After getting satisfactory overbite and overjet, class I molar and canine relationship had been attained. Almost one and a half years later, all the fixed appliances were removed. The case was debonded after 18 months of active treatment. Essix type retainer was given for both arches. The retention period was constant for one year.

### **Results and discussion**

After the orthodontic treatment, good inter cuspatation of the upper and lower teeth was attained. Class I molar and canine relationships were achieved in both sides along with proper overbite and overjet. The crowding was corrected in both dental arches. The inclinations of the upper and lower canines and midline deviation were corrected, resulting in a good inter incisal angle. Soft tissue profile of the patient was enhanced. The occlusion and the facial profile were virtually steady during the retention phase (figure 2, 3, 4). Figure 5 shows the post treatment

exta and intra oral photographs.

Since ancient times, orthodontic treatment has been striving to systematically and scientifically obtain special goals. One of the main goals of orthodontic treatment is to maintain the stability of occlusion after the orthodontic treatment. Various studies of orthodontics have been done to estimate the stability of occlusion<sup>7,8</sup>. Stability of treatment depends on the treatment approach, type of malocclusion, patient cooperation and growth and flexibility of the hard and soft tissues<sup>9</sup>.

For the current case, orthodontic diagnosis and treatment planning were based on the aesthetics. We focused on improving the position of the patient's upper and lower arch crowding in relation to the soft tissue profile.

For patients presenting with a crowded arch, there is debate as to which treatment method (extraction or non-extraction) is the most effective in attaining long-term stability. To correct the crowded arch, premolar extraction has been a recognized practice. But even with retraction in extraction treatment, teeth may return to their pre-treatment position. As now-a-days the aesthetic of soft tissue profile and growth changes are becoming main factors during treatment planning, orthodontic treatment methods are favoring non-extraction with that in mind<sup>10</sup>.

Different studies have found that relapse of anterior crowding is common in patients who are treated via the extraction method<sup>11,12</sup>. Moreover, it is similarly shown that patients treated without extraction also experience relapse<sup>13,14</sup>.

Rather than relapse, there are also evidences in successful orthodontic treatment to correct the crowding using extraction and non-extraction methods. A retrospective study of Angle Class I malocclusions has been done where crowding treated with non-extraction method<sup>15</sup>. A long-term follow up study stated that patient with severe anterior crowding treated without any extraction showed stable results<sup>16</sup>. On the other hand, there is also evidence of successful orthodontic treatment to correct crowding, wherein both extraction and non-extraction methods led to no relapse. Likewise, 30 subjects of class I malocclusion with crowding

treated with the four 1st premolar extractions method also showed similar stability<sup>17</sup>.

In the present case, we decided to extract both the upper and lower first premolar teeth for the following reasons:

- (1) Minimum retraction of the upper incisors and extensive retraction of the lower incisors were desirable because of edge-to-edge bite and the upper lateral incisors were in crossbite
- (2) To maintain Class I molar relationships

### **Conclusion**

Proper treatment plan that is based on sound diagnosis is the key for success and stable orthodontic treatment results. Consequently, we succeeded in attaining the desirable esthetics and occlusion. Timely management of a case and regular review ensures successful completion in a minimal span of time. Relative proportions of tooth size in upper and lower arches are fundamental to achieve maximum intercuspation and desired functional occlusion. Finally, patient finished the treatment with beautiful smile, obtained proper overjet and overbite, corrected cross bite, midline shifting.

### **Consent**

Written consent was taken from the patient before starting the treatment and they were also made aware of the publication.

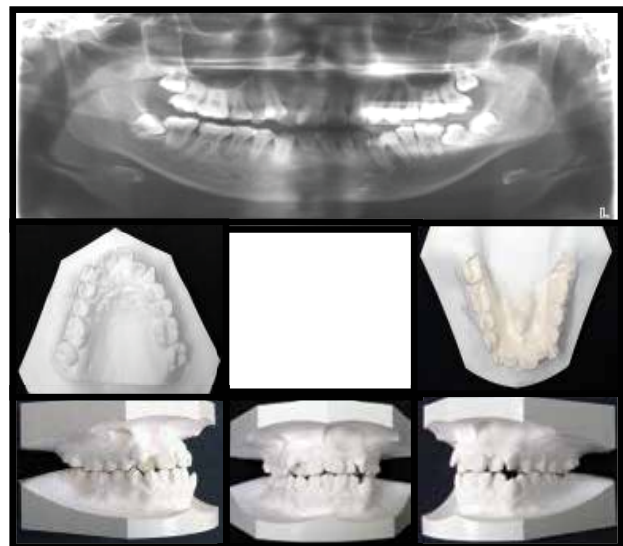


Fig. 1. Pre-treatment orthodontic radiographs and dental model photographs.

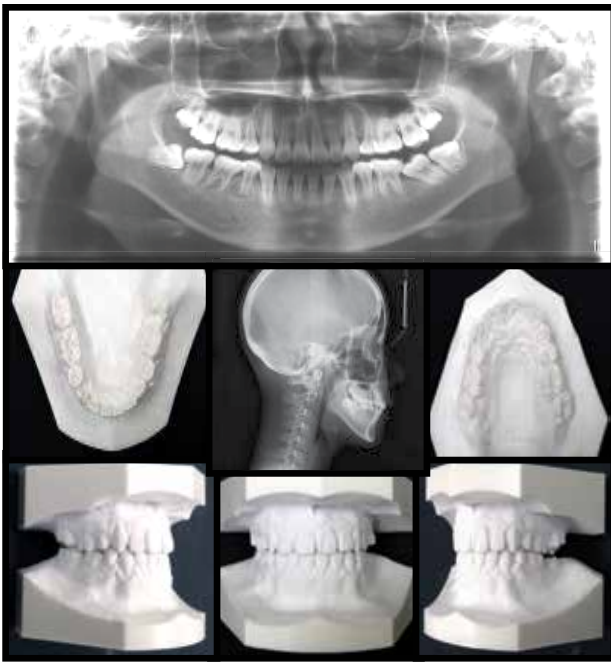


FIG. 2. Post- treatment radiograph and model photographs.




FIG. 4. Pre and post treatment changes highlighted in left side

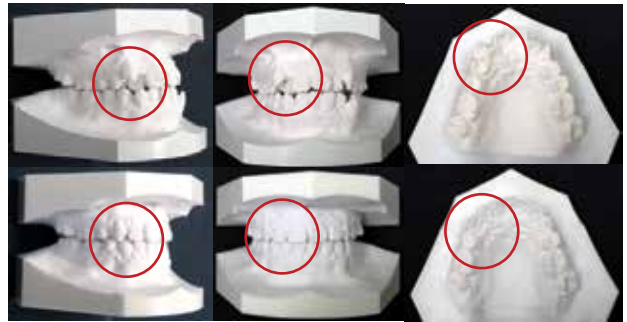


FIG. 3. Pre and post treatment changes highlighted in right side.

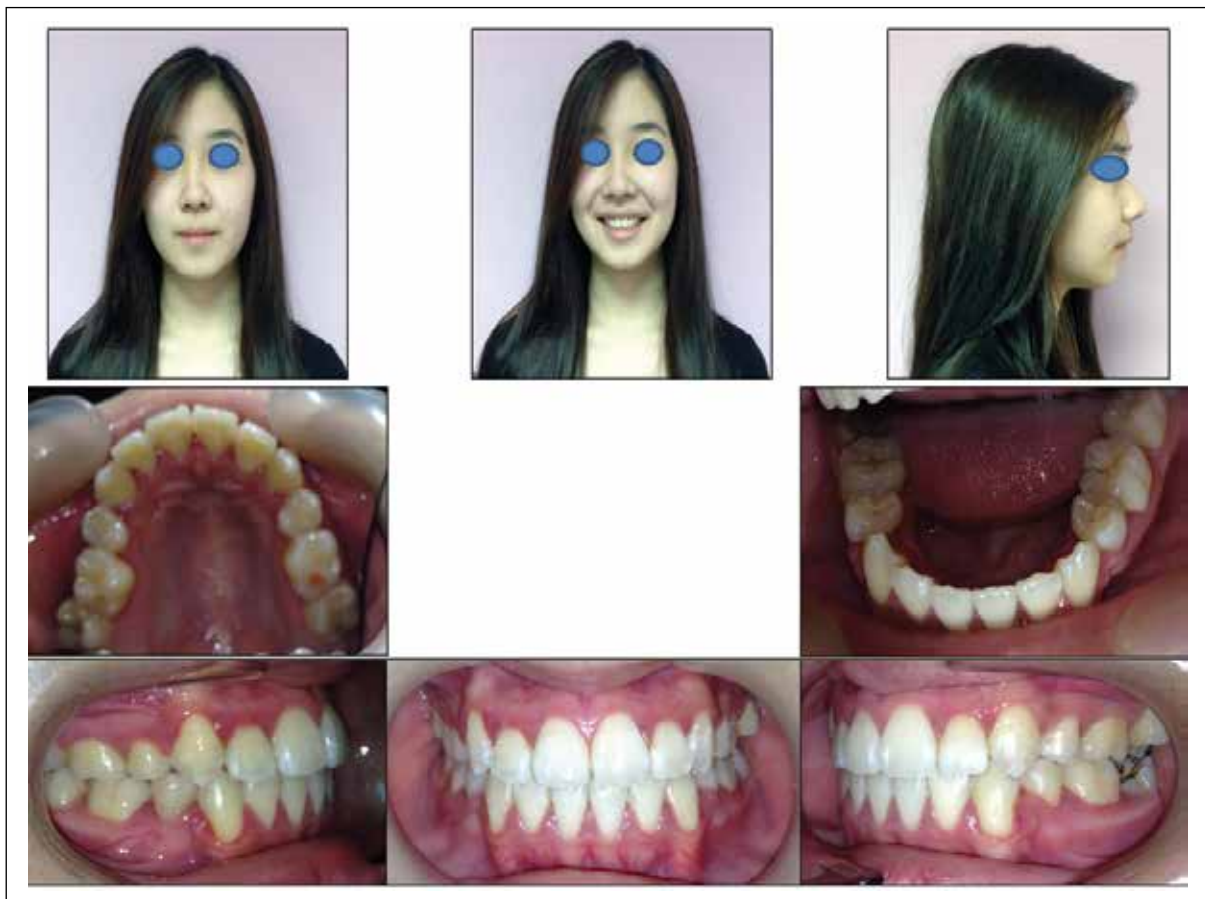

Figure 5 Post treatment Extra and Intra oral photographs.

## References

1. Yu HS, Baik HS, Sung SJ, Kim KD, Cho YS. Threedimensional finite-element analysis of maxillary protrusion with and without rapid palatal expansion. *Eur J Orthod*. 2007;**29**(2):118–25.
2. Buttke, T.M., and Proffit, W.R. Referring adult patients for orthodontic treatment. *J Am Dent Assoc*. 1999;**130**:73-9.
3. Yamamoto T, Torii M, Yashiro K, Takada K. Treatment of Angle Class III malocclusion with tooth-size discrepancy caused by the large upper and lower first premolar teeth. *Orthod Wave*. 2008;**67**(2):81-6.
4. Cai B, Zhao X-G, Xiang L-S. Orthodontic decompensation and correction of skeletal Class III malocclusion with gradual dentoalveolar remodeling in a growing patient. *Am J Orthod Dent Orthop*. 2014;**145**(3):367-80.
5. Vig KWL, Weyant R, Vayda D, O'Brien KD, Bennett E. Orthodontic process and outcome: efficacy studies—strategies for developing process and outcome measures: a new era in orthodontics. *Clin Orthod Res*. 1998;**1**:147-55.
6. Cornelis MA, Scheffler NR, De Clerck HJ, Tulloch JC, Behets CN. Systematic review of the experimental use of temporary skeletal anchorage devices in orthodontics. *Am J Orthod Dentofacial Orthop*. 2007;**131**:S52-S58.
7. Little RM, Riedel RA, Årtun J. An evaluation of changes in mandibular anterior alignment from 10 to 20 years postretention. *Am J Orthod Dentofacial Orthop*. 1988;**93**:423-28.
8. Fidler BC, Årtun J, Joondeph DR, Little RM. Long-term stability of Angle Class II Division 1 malocclusions with successful occlusal results at end of active treatment. *Am J Orthod Dentofacial Orthop*. 1995;**107**:276-85.
9. Al Yami AE, Kuijpers-Jagtman AM, Van't Hof MA. Stability of orthodontic treatment outcome: follow-up until 10 years postretention. *Am J Orthod Dentofac Orthop*. 1999;**115**:300-04.
10. Erdinc AE, Nanda RS, Işıksal E. Relapse of anterior crowding in patients treated with extraction and nonextraction of premolars. *Am J Orthod Dentofac Orthop*. 2006;**129**(6):775-84.
11. Persson M, Persson EC, Skagius S. Long-term spontaneous changes following removal of all first premolars in Class I cases with crowding. *Eur J Orthod*. 1989;**11**:271-82.
12. Little RM, Riedel RA, Engst ED. Serial extraction of first premolars—postretention evaluation of stability and relapse. *Angle Orthod*. 1990;**60**:255-62.
13. Yavari J, ShROUT MK, Russell CM, Haas AJ, Hamilton EH. Relapse in Angle Class II Division 1 malocclusion treated by tandem mechanics without extraction of permanent teeth: a retrospective analysis. *Am J Orthod Dentofacial Orthop*. 2000;**118**:34-42.
14. Freitas KMS, Freitas MR, Henriques JFC, Pinzan A, Janson G. Postretention relapse of mandibular anterior crowding in patients treated without mandibular premolar extraction. *Am J Orthod Dentofacial Orthop*. 2004;**125**:480-87.
15. Little RM, Wallen TR, Riedel RA. Stability and relapse of mandibular anterior alignment—first premolar extraction cases treated by traditional edgewise orthodontics. *Am J Orthod*. 1981;**80**:349-65.
16. Filho RML, Lima AL. Long-term outcome in a patient with Class I malocclusion with severe crowding treated without extractions. *Am J Orthod Dentofac Orthop*. 2004;**126**(4):495-504.
17. Quaglio CL, de Freitas KMS, de Freitas MR, Janson G, Henriques JFC. Stability and relapse of maxillary anterior crowding treatment in Class I and Class II Division 1 malocclusions. *Am J Orthod Dentofac Orthop*. 2011;**139**(6):768-74.