

Case report

Endoscopic excision of nasal septal schwannoma: case report and review of literature

Norsyamira Aida Mohamad Umbaik¹, Rosdi Ramli², Baharudin Abdullah³

Abstract:

Schwannomas are benign tumors arising from Schwann cells of myelinated nerve sheath. Schwannomas of the nasal cavity and paranasal sinuses are rare, with only 4% occurrence. We report a case of a 48-year-old lady who presented with 1-year history of progressively worsening left nasal blockage. Rigid nasoendoscopy showed a smooth, globular mass occupying the left nasal cavity. The mass arose from the left nasal septum and impinged on the anterior part of the middle turbinate posteriorly and inferior turbinate anteriorly. Computed tomography of the paranasal sinuses showed a 3.8 × 1.8 x 3.7-cm enhancing soft tissue density in the left nostril. The mass obliterated the left nasal cavity and caused deviation of the septum to the right. The patient underwent an endoscopic excision and histopathologic examination confirmed the diagnosis of Schwannoma. Postoperative recovery was uneventful and no recurrence was seen in the follow-up period.

Keywords: Nasal Septum; Schwannoma; Endoscopic excision

*Bangladesh Journal of Medical Science Vol. 18 No. 03 July'19. Page : 660-662
DOI: <https://doi.org/10.3329/bjms.v18i3.41646>*

Introduction

Schwannoma or neurilemmomas are neurogenic benign lesions, originating from myelinated Schwann cells of the peripheral nerve sheath.¹⁻⁴ Approximately 25-45% Schwannomas occurred in head and neck region^{1,2,5} with the most common nerve affected is the cranial nerve VIII presenting as vestibular Schwannoma (formerly known as acoustic neuromas).^{2,3} Whereas only about 4% occurrence in the nasal cavity and paranasal sinuses has been reported,¹⁻³ and the nasal septum Schwannomas is even rarer, with only few cases previously reported in the literature.^{2,5} The first case of nasal septal Schwannoma was first described by Bogdasian and Stoutin 1943⁵. We encountered an exceptionally rare case of this nasal septal Schwannoma which presented with unilateral solitary nasal mass.

Case report

A 48 years old lady with underlying hypertension, presented with progressive left nasal blockage for one year duration associated with occasional blood-stained, foul smelling nasal discharge and headache. She has no background history of allergic rhinitis. Rigid nasoendoscopy showed globular left nasal mass arising from left nasal septum and extending down to the floor of left nasal cavity [Figure 1]. The mass was reddish and fleshy but does not easily bleed upon being probed. Both Fossa of Rosenmullers were clear. Punch biopsy taken and suggestive of neurofibroma. Thus patient was subjected for contrast enhanced computed tomography (CECT) of the paranasal sinuses to see the mass extension which showed a well-defined polypoidal shape enhancing soft tissue density in the anterior part of the left nasal

1. Norsyamira Aida Mohamad Umbaik
2. Rosdi Ramli
Department of Otorhinolaryngology and Head and Neck Surgery, Hospital Raja Perempuan 3. Zainab II, 15586 Kota Bharu, Kelantan, Malaysia.
3. Baharudin Abdullah Department of Otorhinolaryngology-Head & Neck Surgery, School of Medical Sciences, Universiti Sains Malaysia Health Campus, 16150 Kota Bharu, Kelantan, Malaysia.

Correspondence to: Professor Dr Baharudin Abdullah, Department of Otorhinolaryngology-Head & Neck Surgery, School of Medical Sciences, Universiti Sains Malaysia, Health Campus, 16150 Kota Bharu, Kelantan Email: baharudin@usm.my

cavity and left middle meatus measuring 3.7cm X 1.8cm X 3.7cm [Figure 2]. It minimally extends to right nasal cavity and in close proximity to the left inferior and middle turbinate and pushing the left middle turbinate superiorly. The mass also cause deviation of the nasal septum to the right. However it does not erode any of the mucosa, cartilage or bone and also does not extend beyond the nasal cavity. Thus, we proceeded with endoscopic excision of the left nasal mass. Intraoperatively, the mass was fine, fleshy and broad-based, arising from anterior part of left septum. There was no significant bleeding during excision. Biopsy taken before proceeds with debriding the mass till it was fully excised. Hemostasis are secured intraoperatively using Neuray packing with Moffets solutions which was removed after five minutes, without need of postoperative nasal packing. Postoperatively, patient was able to be discharged home the next day with no evidence of bleeding within 24 hours post surgery. Patient was seen at outpatient clinic two weeks post surgery with symptom free and no post operative complications. Biopsy taken intraoperatively showed presence of Antoni A and Antoni B features under immunohistochemistry, which are characteristics of Schwannoma rather than neurofibroma. Patient is currently under follow up and she was seen four monthly for repeat rigid nasoendoscopy [Figure 3]. Currently eight months post surgery and patient is symptom free with no recurrence.

Discussion

The presentation of sinonasal Schwannoma is usually non-specific and mostly occurs as a result of the mass effect of the tumor. As this tumor is slow growing, typically the nasal septal Schwannoma manifests with unilateral nasal blockage which gradual in onset and takes few months or years before patient seek treatment. Other symptoms include nasal discharge, epistaxis and anosmia. Facial pain, headache and facial swelling also has been reported as the tumor obstructing the drainage of the paranasal sinuses.^{2,5} Nasoendoscopic findings usually showed unilateral solitary benign looking mass. However, given large variability of unilateral nasal mass pathologies, the diagnosis of septal Schwannoma requires a high degree of suspicion and a clear illustration of the Antoni A

and Antoni B structures on histological examination.² It is important though, to differentiate between the Schwannoma and neurofibroma as it implicates the risk estimation of malignant transformation of these tumors. It is reported that Schwannoma has 2% risk of malignant transformation compared to neurofibroma which has more malignant potential (up to 12% risk) with more locally aggressive nature.^{3,7,9,13} Schwannoma originating from nasal septum and paranasal sinuses are presumed to arise from the ophthalmic branch and maxillary branch of trigeminal nerve or from parasympathetic nerve (from the sphenopalatine ganglion) or from sympathetic nerve (from the carotid plexus).^{1-3,5,6} However, it is difficult to establish the origin of the nerve intraoperatively as the tumor usually arise from the nerve endings of the small branches.^{1,2} Contrast-enhanced computed tomography (CECT) of the paranasal sinuses is helpful in evaluating the size of the mass, origin, localization of the tumor and involvement of surrounding structures. It also will help surgeon to plan the best approach to remove the tumor either open approach or endoscopic approach. Magnetic resonance imaging (MRI) is indicated in large tumor that locally aggressive or has invade surrounding structures.⁵⁻⁶ Benign Schwannoma can erode bone by pressure and may extend beyond the nasal cavity as reported in Eun H. et al and Ling-Feng et al, but this particular feature does not points towards malignant transformation of the tumor. Malignant Schwannoma is diagnosed histologically by evidence of malignant cells characteristics.^{5,8} As this tumor is benign with very low malignant transformation, a minimally invasive surgery is preferable by most authors including our centre. Endoscopic approach with either tumor removal in en bloc or piecemeal excision, are done under general anesthesia. But some authors have reported a successful removal of the tumor under local anesthesia in outpatient setting.^{3,4,13} Some authors chose open approach due to large and locally invasive tumor.^{2,10,11} No recurrence has been reported in the literature reviewed and most of the authors has been following up the patients in six months to two years period. We are following up our patient four monthly with repeat nasoendoscopy and also notice no recurrence so far.

Conclusions

Septal schwannoma is an interesting encounter because it is a rare presentation of a well-understood disease process. Being rare as a differential diagnosis of unilateral nasal mass, the possibility of their existence should be acknowledged as one of the benign lesion with risk of malignant transformation if not successfully treated.

Ethical approval: Prior the submission, this case report was approved by ethics committee.

Funding: No funding

Conflict of interest: The authors declare that they

have no conflict of interest.

Author's contribution:

Data gathering and idea owner of this study: Norsyamira AMU, Rosdi R, Baharudin A.

Study design: Norsyamira AMU, Rosdi R, Baharudin A.

Data gathering: Norsyamira AMU, Rosdi R, Baharudin A.

Writing and submitting manuscript: Norsyamira AMU, Rosdi R, Baharudin A.

Editing and approval of final draft: Norsyamira AMU, Rosdi R, Baharudin A.

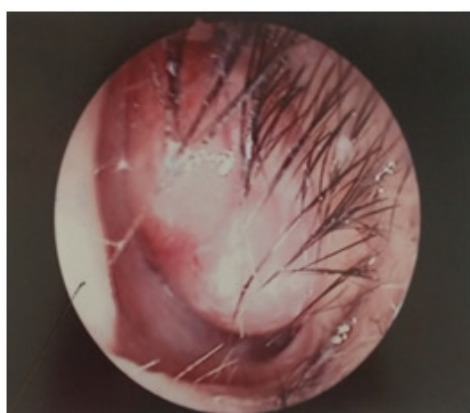


Figure : 1

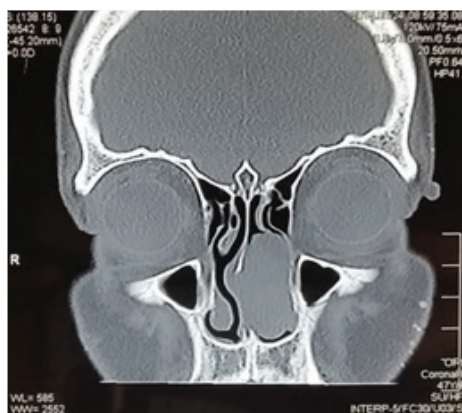


Figure : 2

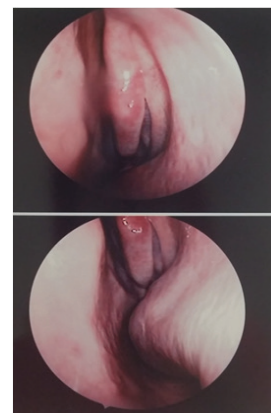


Figure : 3

References:

1. Debrata P, Saumya RD, Santhos KP. A case of expansile ancient schwannoma of the nose and paranasal sinuses. *Egyptian Journal of Ear, Nose, Throat and Allied Sciences* (2015); **16**: 265-268.
2. Brandon C, Curtis O, Ghassan A. A suprising cause of unilateral nasal obstruction and epistaxis: nasalseptal schwannoma. *Journal of Surgical Case Reports JSCR* 2014; **3**: 1-3
3. Ling-Feng W, Chih-Feng T, Chee-Yin C. Schwannoma of the nasal septum: A case report. *Med Sci* 2004; **20** : 142-5
4. Peng Z, Fan Z, Jinnan L, Shixi L. Only septal deviation? A tiny Schwannoma in the nasal septum. *Indian J Otolaryngol Head and Neck Surg* 2012; **65** (1) : 80-82
5. Bhaskar M, Sharmistha S, Biswanath P, Mallika P. Schwannoma of nasal septum: A rare case report with literature review. *Egyptian Journal of Ear, Nose, Throat and Allied Sciences* 2012; **13**: 121-125 <https://doi.org/10.1016/j.ejenta.2012.08.002>
6. EunHp, Seung-Sin L, Sung WB. A Schwannoma in the nasal septum. *Eur Arch Otorhinolaryngol* (2008) **265**: 983-985 <https://doi.org/10.1007/s00405-007-0541-4>
7. Renata C, Juliana A, Reginaldo R, Shirlei S. Plexiform Schwannoma of the nasal tip: surgical approach. *Braz J Otorhinolaryngol.* 2012; **78**(3): 134
8. Sharlene C, Vitor Y, Andre L, Marcia N, Luiz A. Malignant paranasal sinus schwannoma. *Braz J Otorhinolaryngol.* 2012; **78**(4): 135 <https://doi.org/10.1590/S1808-86942012000400026>
9. Fadzilah I, Salina H, Khairuzzana B, Rahmat O, Primuharsa Putra SH. Nasal vestibule schwannoma: report of a rare case. *Ear Nose Throat J.* 2014 Jun; **93** (6): E 33-5
10. Giulliano E, Marcos R, Soraia M, Nasal Schwannoma. *Rev Bras Otorhinolaryngol* 2006; **72** (5): 714
11. Gokceer T, Yaylaci A, Akkaynak AC, Peker O, Karaaslan O. Nasal schwannoma: a report of two cases. *Kulak BurunBogazIhtisGerg.* 2004; **13**(1-2): 46-50
12. J.L. Quesada, A. Enrique, J. Lorente. Sinonasal schwannoma treated with endoscopic microsurgery. *Otorhinolaryngol Head Neck Surg* 2003; **129**:300-2 [https://doi.org/10.1016/S0194-5998\(03\)00528-X](https://doi.org/10.1016/S0194-5998(03)00528-X)
13. Joginder S, Samarpal S, Sukhdeep K. Schwannoma of membranous nasal septum. *Braz J Otorhinolaryngol.* 2013; **79**(6):789 <https://doi.org/10.5935/1808-8694.20130140>