

Case report

Multiple Idiopathic Cervical Resorption: A Case Report

DK Roy, S Sharma, P Suwal, V P Singh, A Iyer,

Abstract:

Multiple idiopathic cervical resorption (MICR) is a disease of the tooth in which there is progressive cervical resorption of multiple teeth leading to exfoliation of crown. The etiological factors for such a resorption are various but the lack of definitive single etiological factor/disease process makes management of such processes extremely difficult. A flap surgery followed by restoration with glass ionomer cement was carried out for the cessation of resorption process, finally a cast partial denture was delivered for prosthetic rehabilitation.

Key Words: cervical, idiopathic, multiple, root resorption.

Introduction:

The first case of idiopathic cervical resorption was probably reported by Mueller and Rony in 1930¹. It is an entity that demonstrates pathognomic deep cervical resorption of vital teeth originating at cemento-enamel junction². It may occur spontaneously in the absence of either local or systemic factors. The finding of such resorption in the cervical areas of the teeth is relatively rare and cervical root resorption involving multiple teeth is very uncommon³. The etiological factors for such a resorption are various but the lack of definitive single etiological factor/disease process makes management of such processes extremely difficult. Early diagnosis and a perfect treatment plan can arrest the progression of such lesions.

Case Report:

A 32-year-old male, policeman by profession presented to the Department of Oral Medicine and Radiology with a chief complaint of replacement of missing upper back teeth. The patient gave a history of pain and sensitivity in the maxillary third molar region bilaterally which later progressed to involve all the maxillary molars which became mobile within a short period of one and half month. The patient had visited a dentist who had extracted all the mobile maxillary molars and did root canal treatment in 25

(FDI System). The detailed clinical examination revealed the extraction site to have healed satisfactorily. The root canal treated 25 was found to be mobile. An Intra Oral Peri apical radiograph {IOPAR} was done and was compared with the radiograph done six months back by a dentist. The previous radiograph showed resorption of 25 and 26 around the cervical area (Figure I1). The radiograph taken during the first visit (Figure I2) showed progression of resorption in 24 which was normal in the previous radiograph. Further an orthopantomogram (Figure III3) was taken which showed resorption of 13, 14 and 23. All the mandibular teeth were clinically as well as radiographically normal. A detailed medical history suggested that patient was medically healthy. There was no history of similar problem in any of his maternal and paternal ancestors. The following biochemical investigations were also carried out to rule out any endocrinal disorders leading to resorption of bone and teeth⁴. Calcium (total) = 8.3 mg/dl, Alkaline Phosphatase = 323 U/L, T₃ = 4.87 pg/ml, T₄ = 1.89 ng/dL, TSH = 0.67 μIU/ml. The test carried out implied that there was slight elevation in the level of alkaline phosphatase as per the reference range (100-290U/L) given by the laboratory, and other findings were within the normal limits. The treatment protocol followed was extraction of 24 and 25, root canal treatment of 13 and 23 in

1. Dr. Deepak Kumar Roy, Dental Surgeon, Department of Prosthodontics, CODS, BPKIHS, Dharan, Nepal

2. Dr. Shivalal Sharma, Associate Professor and Head Department of Periodontology CODS, BPKIHS, Dharan, Nepal

3. Dr. Pramita Suwal, Associate Professor and Head, Department of Prosthodontics CODS, BPKIHS, Dharan, Nepal.

4. Dr. Varun Pratap Singh, Assistant Professor and Incharge Head, Department of Orthodontics CODS, BPKIHS, Dharan, Nepal

5. Dr. Ashok IyerTutor, Department of Prosthodontics CODS, BPKIHS, Dharan, Nepal.

Corresponds to: Dr. Varun Pratap Singh, Assistant Professor and Incharge Head, Department of Orthodontics CODS, BPKIHS, Dharan, Nepal **Email: varunde@gmail.com**

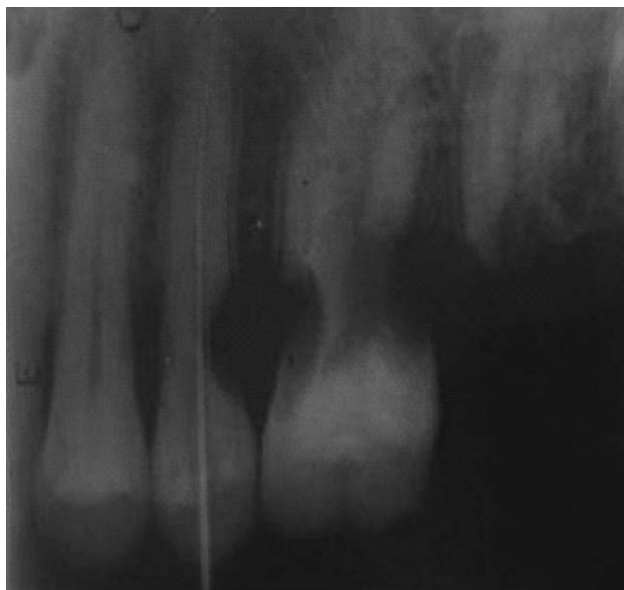


Fig 11: Intraoral periapical radiograph showing severe cervical resorption with 25, 26. { As mentioned in the article , the case was first treated by a general dentist and patient provided this radiograph, he did root canal treatment for 25 }

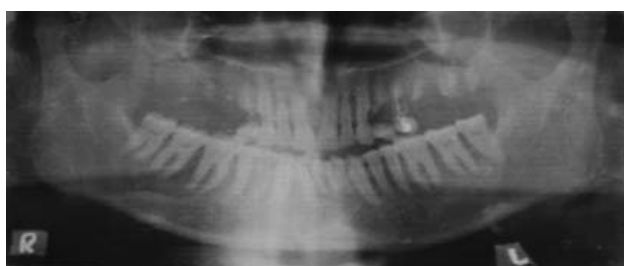

Fig 3: Orthopantomograph showing severe cervical resorption of multiple upper teeth.

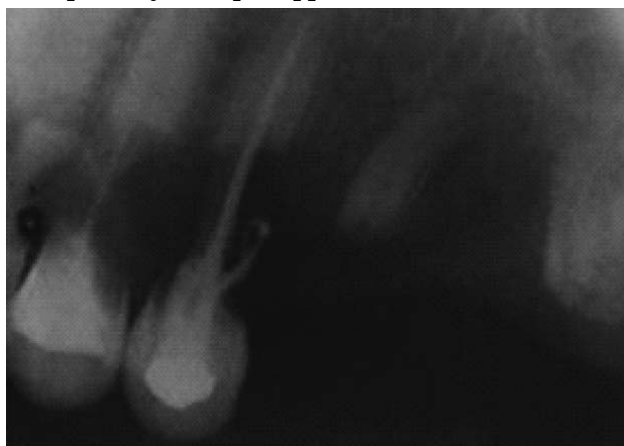

Fig 112: Intraoral periapical radiograph taken during the first visit showing progression of the resorption in 24, 25 (RCT treated).{This radiograph was taken in our hospital when the patient reported to us and as mentioned in the report ,the general dentist tried to extract the 26 and he left root stumps which were eventually extracted in our hospital}

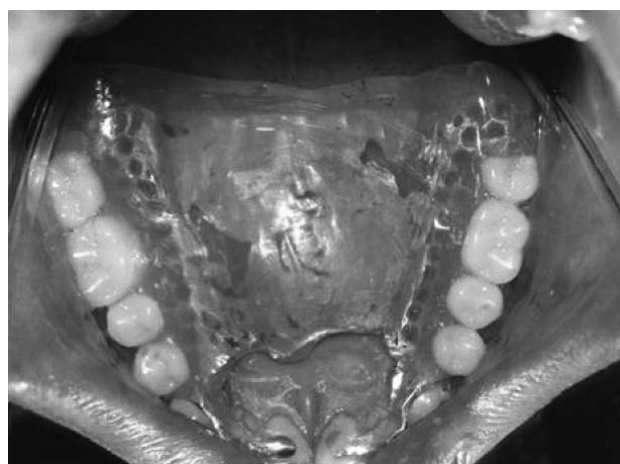

Fig 4: Final restoration of the occlusion of patient with cast partial denture

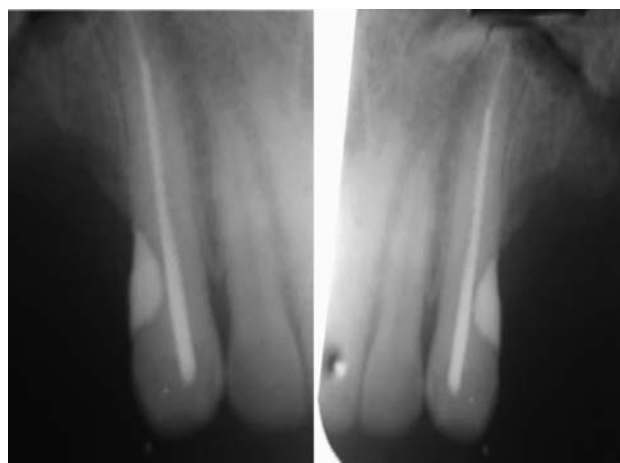

Figure V5: Follow up radiographs after 1 year of treatment showing complete cessation of resorption which the resorption approximated the pulp, followed by flap reflection and removal of the smear layer from the tooth surface, and cervical restoration with glass ionomer cement. Finally for prosthetic rehabilitation, a cast partial denture made of cobalt chromium alloy was delivered to the patient (Figure IV4). The patient was kept under a regular follow up every three months to check for progression of disease. { A follow up radiograph is added for reference {Figure-V5}

Discussion:

The first case of idiopathic cervical resorption was reported by Mueller and Rony in 1930¹. The etiology of this multiple idiopathic cervical resorption type of resorption however remains elusive. This type of resorption may Multiple idiopathic cervical resorption (MICR) may occur due to various factors such as tetracycline root conditioning⁵, guided tissue regeneration⁶, surgeries⁷, root canal treatment and

bleaching⁸, and orthodontic treatment or trauma⁹. {These findings are taken from different articles in different fields of dentistry, that's why different references are cited} However, none of the reported cases in dental literature show up with a definite etiological factor, hence prediction and prevention of such cases are very difficult. Treatment is compounded because of lack of etiological factors. Unless early treatment is initiated, the resorption progresses to a large irreversible loss of tooth structure. The treatment includes oral hygiene reinforcement, supragingival debridement and restoration with calcium hydroxide and glass ionomer cement¹. Root resorption can also sometimes be misdiagnosed and confused with root caries. The clinical and radiographic distinction between cervical root resorption and root caries is helpful in order to establish the proper treatment plan. Root caries is usually

seen in areas of gingival recession which is clinically soft to touch, and radiographically ill defined, saucer-like and radiolucent, whereas, cervical root resorption is most commonly an incidental radiographic finding. On exploration, hard sensation accompanied by a sharp scarping sound is felt in the areas of resorption. Radiographically, the sharp edges of the cavity border can be significant in the differential diagnosis of root caries¹⁰.

Conclusion:

Multiple idiopathic cervical root resorption is an occult, progressive condition of unknown aetiology till today. However, the resorption can be arrested in the initial stage by flap reflection and restoration of the teeth with calcium hydroxide and glass ionomer cement.

References

1. Mueller E, Rony HR. Laboratory studies of an unusual case of resorption. *J Am Dent Assoc.* 1930;**17**: 326-334
2. Kim PH, Heffel LB, Multiple idiopathic resorption in primary dentition: Review of literature & case report. *Oral Surg Oral Med Oral Pathol Oral radiol Endod* 1994;**88**; 501-505
[http://dx.doi.org/10.1016/S1079-2104\(99\)70070-3](http://dx.doi.org/10.1016/S1079-2104(99)70070-3)
3. Nikolidakis D, Nikou G, Meider GI, Jansen JA. Cervical external root resorption: 3 year follow up of a case. *Journal of Oral Science*: **50**(4); 487-91
<http://dx.doi.org/10.2334/josnusd.50.487>
PMid:19106479
4. Strachan MWJ, Walker BR. Davidson's Principles & Practice of Medicine. 21st ed. Edinburgh: Churchill Livingstone Elsevier; 2010. Chapter 20, Endocrine disease; pp 731 – 794.
5. Ben-Yehouda A. Progressive cervical root resorption related to tetracycline root conditioning. *J Periodontol* 1997; **68**:432-35PMid:9182737
6. Blomlof L, Lindskog S. Cervical root resorption associated with gingival tissue regeneration - a case report. *J Periodontol* 1998; **69**:392-395
PMid:9579627
7. Liang H, Burkes ET & Frederiksen NL. Multiple idiopathic cervical root resorption: systematic review & report of four cases. *Dentomaxillofac radiol.* 2003;**32**; 150-55
<http://dx.doi.org/10.1259/dmfr/12925020>
8. Trope M. Cervical root resorption. *J Am Dent Assoc.* 1997; 128(suppl):56s-59sPMid:9120148
9. Lydiatt DD, Holling RR, Peterson G. Multiple idiopathic root resorption; diagnostic considerations. *Oral Surg Oral Med Oral Pathol* 1989; 67:208-210
[http://dx.doi.org/10.1016/0030-4220\(89\)90333-2](http://dx.doi.org/10.1016/0030-4220(89)90333-2)
10. Bergmans L, Van Cleynbreugel J, Verbeken E, Wevers M, Vanmeerbeek B, Lambrechts P. Cervical external root resorption in vital teeth. *J Clin Periodontol* 2002; 580 – 585